

## Short Communication

**Tissue Engineering: Oromaxillofacial reconstruction  
with platelet rich plasma (PRP)**Arash Poorsattar- Bejehmir<sup>1</sup>✉

1. Dental Student , Dentistry Student Research Committee, Dental Materials Research Center, Babol University of Medical Sciences, Babol-Iran.

✉**Corresponding Author:** Arash Poorsattar Bejeh Mir, Dentistry Student Research Committee, Faculty of Dentistry, Babol University of Medical Sciences, Babol-Iran.

**Email:** arashpoorsattar@gmail.com**Tel:** +981112291408-9**Received:** 30 Jun 2012**Revised:** 4 Aug 2012**Accepted:** 19 Aug 2012

Platelet rich plasma (PRP) is defined as patient's own blood product that consists a minimum of 1,000,000/  $\mu$ L of platelets and a high amount of seven growth factors including: epidermal growth factor (EGF), venous endothelial growth factor (VEGF), platelet-derived growth factor (PDGF<sub>aa, bb, ab</sub>) and transforming growth factor (TGF<sub>b1, b2</sub>). This product can accelerate cell proliferation, collagen formation and angiogenesis.

PRP as layer in the graft site either by insertion or spray on (as a biomembrane) has been used in various oral and maxillofacial hard and soft tissue reconstructive and plastic surgeries (1). Notably, its bioconductive role should not be misinterpreted as bioinductive role by which stem cells are engaged. Marx, a pioneer in PRP, believes that PRP has remarkable outcomes when used with autogenous grafts and when applied with xenografts (2). According to similar concentration of fibronectin, vitronectin and fibrin in PRP to that of a clot, the use of PRP as bioadhesive with elimination of sutures has been a concern (1).

Thrombocyte gel is prepared from blood and has lower and under optimal fracture and shear resistance when compared to other commercially available surgical adhesives (3). PRP was used successfully controlling bleeding in patients with cardiovascular diseases and anticoagulant medication (4). This promising evidence may aid the clinician for better

bleeding diathesis vision, especially in the case of emergent surgeries of anticoagulated patients. There are clear evidences that PRP can be applied in reconstruction of jaw osseous defects, tooth root coverage with gingival, furcation involvement, lessening alveolar osteitis following tooth extractions, alveolar ridge augmentation, implant site augmentation in sinus lift surgery, augmenting bone-to-implant-contact (BIC), skin rejuvenation with fat injection, facial burn wound repair and reducing edema following impacted third molar surgical extraction or blepharoplasty (1, 2, 5).

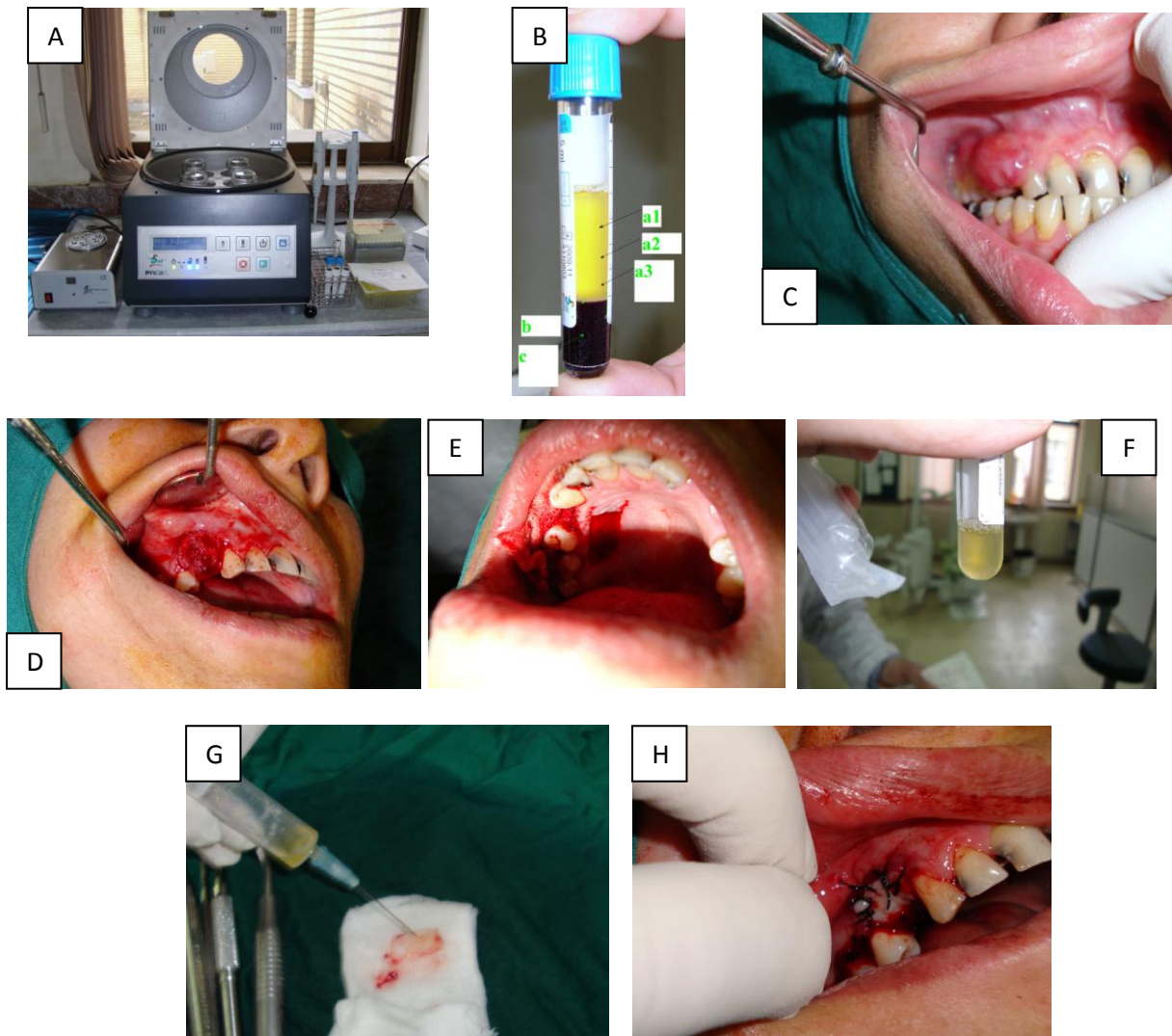
The preferable in-office method for PRP preparation is described with a dual-spin device (e.g., Harvest Tec.). The first spin (hard spin) extracts the red blood cells from the plasma which contains white blood cells WBC) and platelets.

The second spin (soft spin) facilitates pulling platelets from WBCs. The traditional centrifuges and single spin devices are less successful to prepare an ideal solution in terms of high concentration of platelets and growth factors. Moreover, supplanting with calcium chloride and thrombin may increase the release of growth factors from  $\alpha$  granule (Zymogen granules) (1, 2).

Within 10 and 60 minutes after platelets being activated, 70% and 100% of growth factors are released, respectively. Surprisingly, production and release of such factors will be continued till platelets

death, by 8<sup>th</sup> day of activation (1). This unique product can be feasibly prepared bed-side within 30 minutes and is contrasted from other blood products in terms of being free from transmission of HCV, HIV, HBV and other blood-borne diseases. The application of such a product among the patients with localized or systemic diseases (head and neck radiotherapy or diabetes) that

adversely affects the process of wound healing is recommended. When an extensive soft or hard tissue surgery is planned, PRP can be safely used to enhance the in-situ bleeding control, accelerate and improve angiogenesis and blood supply along with lowering the chance of scar formation by moderation of growth factors and fibroblasts activation (figure 1).



**Figure.** Single spin device (A). Four milliliters blood was drawn and then mixed with 0.5 cc citrated sodium 3.8%, then centrifuged at 460 g for 8 min. a<sub>1</sub>: 1cc platelet poor plasma (PPP), 0.5 μl of calcium chloride could be added to form membrane (glue). a<sub>2</sub>: 0.5 cc with moderate platelet count and growth factor (PGF), 25μl of calcium chloride is added to be mixed with osseous graft or other biomaterials. a<sub>3</sub>: 1cc platelet rich plasma (PRP), is used to be sprayed on implant surface, alveolar sockets and soft tissues (gel). b: white blood cell. c: red blood cell. (B) Patient presented with a large pyogenic granuloma (C), Large defect observed after the removal of lesion (D), a free gingival graft prepared from hard palate mucosa (E), bottom 1cc of PRP was removed and stored in a syringe (F) PRP sprayed at graft (G), graft was sutured over the defect (H)

## Acknowledgements

Special thanks to Dr. Mahmood Khosravi Samani, Assistant Professor at the Department of Periodontology, Babol University of Medical Sciences.

## References

1. Marx RE. Platelet-rich plasma (PRP): what is PRP and what is not PRP? *Implant Dent* 2001; 10: 225-8.
2. Arora NS, Ramanayake T, Ren YF, Romanos GE. Platelet-rich plasma: a literature review. *Implant Dent* 2009; 18: 303-10.
3. Altmeppen J, Hansen E, Bonnländer GL, Horch RE, Jeschke MG. Composition and characteristics of an autologous thrombocyte gel. *JSR* 2004; 117: 202-207.
4. Della Valle A, Sammartino G, Marenzi G, Tia M, Espedito di Lauro A, Ferrari F, et al. Prevention of postoperative bleeding in anticoagulated patients undergoing oral surgery: use of platelet-rich plasma gel. *J Oral Maxillofac Surg* 2003; 61: 1275-8.
5. Fuerst G, Gruber R, Tangl S, Sanroman F, Watzek G. Enhanced bone-to-implant contact by platelet-released growth factors in mandibular cortical bone: a histomorphometric study in minipigs. *Int J Oral Maxillofac Implants* 2003; 18: 685-90.