

Original Article

Histologic evaluation of pulpal response to MTA and capsaicin in cats

Zahrasadat Madani (DDS)¹, Maryam Seyedmajidi (DDS)², Aliakbar Moghadamnia (PhD)³,

Ali Bijani (MD)⁴, Amir Zahedpasha (DDS)^{5✉}

1. Assistant Professor, Department of Endodontics, Faculty of Dentistry, Babol University of Medical Sciences, Babol- Iran.
2. Assistant Professor, Department of Oral & Maxillofacial Pathology, Dental Materials Research Center, Faculty of Dentistry, Babol University of Medical Sciences, Babol-Iran.
3. Professor, Department of Pharmacology and Physiology, Faculty of Medicine, Babol University of Medical Sciences, Babol-Iran.
4. General Practitioner, Non-Communicable Pediatrics Diseases Research Center, Babol University of Medical Sciences, Babol-Iran.
5. Dentist, Faculty of Dentistry, Babol University of Medical Sciences, Babol- Iran.

✉**Corresponding Author:** Amir Zahedpasha, Dentist, Faculty of Dentistry, Babol University of Medical Sciences, Babol-Iran.

Email: dr_Zahedpasha@yahoo.com

Tel: +981112291408-9

Abstract

Introduction: In direct pulp capping, the exposed pulp is directly capped with a capping material to provoke a dentinal bridge formation to seal the exposed area. The aim of this study was to evaluate the pulpal response to MTA and capsaicin in cats.

Methods: The sample for this experimental study consisted of 24 canines of cats, weighed approximately 3-4kg. After sedation, the teeth were cut and exposed at 3mm above cemento-enamel junction, then divided into two groups: 1) direct pulp capping with MTA 2) direct pulp capping with Capsaicin. The cavities were filled with glass ionomer cement (Fuji IX). The cats were sacrificed in the first, second, and fourth weeks 4 canine teeth were extracted for the purpose of histologic analysis. 6 Serial sections were cut parallel to the longitudinal axis of the canines. The sections were stained with hematoxylin & eosin, and were observed and analyzed using a light microscope.

Results: In both groups treated with MTA and capsaicin, the inflammation decreased during weeks 1, 2, and 4. Less inflammation was seen in MTA group but there was no statistical difference between the two groups ($p=0.22$). In the group treated with capsaicin, necrosis was observed in every 12 samples, but in the other group treated with MTA, only 1 pulp necrosis was seen in the first week ($p=0.000$). There was no significant difference in dentinal barrier formation, inflammatory response, and soft tissue changes between the two groups.

Conclusions: The results of this study showed that capsaicin can decrease the severity of inflammation, but it is ineffective in dentinal barrier formation.

Keywords: MTA, Capsaicin, Pulp capping.

Received: 8 Apr 2012

Revised: 15 May 2012

Accepted: 2 Jun 2012

Introduction

Sometimes the pulp may get exposed either due to caries, trauma, or as a result of iatrogenic errors during the operative procedure. Direct pulp capping is the procedure for treating an exposed pulp with a

biocompatible material. The purpose of this treatment is to seal the exposed site against microbial invasion and provoke the development of a dentinal bridge formation. This dentinal bridge seals the exposed area

and protects the underlying pulp (1). Calcium Hydroxide [$\text{Ca}(\text{OH})_2$] was used for pulp capping for the first time by Hermann (1930), and, from the early 1940s till now, it has been the most used material for pulp capping. The biggest disadvantage of this antibacterial and disinfectant material is its inability to seal the cracked surfaces (1, 2). Zinc oxide eugenol, tri calcium phosphate, and composite resin had also been used as pulp capping agents, but they were not successful in creating a good coronal seal (2).

MTA (Mineral Trioxide Aggregate) was introduced by Torabinejad in 1995 and for its favorable properties, such as strong sealing ability, higher PH, acceptable biocompatibility, long term stability, prevention of bacterial leakage, and stimulation of cementum, dentine and bone formation has been introduced as an acceptable pulp capping agent (1). Capsaicin is an active irritant component of chili pepper that prevents the transmitting of pain impulses to the brain by affecting demyelinated nerve fibers with small diameters (3).

Studies have demonstrated that Capsaicin increases pulpal blood flow and gives anesthesia to teeth with inflammatory pulps, which do not get numb with common anesthetics (3).

Capsaicin reduces the inflammatory infiltrates in experimental treatment of otitis media, and inflammatory cells in colon mucosa (4, 5). Since no study has been done in association with the anti inflammatory effect of capsaicin on pulp, the aim of this study was to evaluate and compare the pulpal response to pulp capping with capsaicin and MTA in cats.

Methods

The sample for this experimental study consisted of 24 canines (4 sound teeth in each cat) of 6 domestic short hair tomcats, weighed approximately 3-4kg. The teeth were divided into two equal groups. The cats were kept in the veterinary care. General anesthesia was induced with intramuscularly injected Ketamine hydrochloride (Alfasan, Woerden, the Netherlands) 25 mg/kg, and Acepromazine (Alfasan, Woerden, the Netherlands) 1mg/kg, and Diazepam (KasminTamin, Islamic Republic of Iran) 2 mg/kg. After sedation, the teeth were cut and exposed at 3 mm above cementoenamel junction using a sterile taper diamond bur and high-speed turbine under water spray. During

all procedure, the presence of blood was considered as a sign of pulp exposure. After that, the teeth were isolated using rubber dam. After pulp exposure, normal saline was used for cavity irrigation and small sterile cotton pellets were used to control the bleeding. In the first group, MTA (Dentsply) was placed into the exposed area. In the second group, one drop of 1% capsaicin (Sigma-Asldrich-Swiss) was put on the exposed area and in both groups; access cavities were sealed by glass ionomer cement (Fuji IX, GC).

The cats were killed in the first, second, and fourth weeks for the purpose of histologic analysis of pulp with the use of vital perfusion method. The selected teeth (4 canines) with a side of jawbone were extracted using a metal disc under water spray.

They were maintained in 10% formalin for 4 days at room temperature. For the purpose of decalcification, the teeth were kept in 5% nitric acid solution for 14 days at room temperature. Then the samples were submerged in paraffin. 6Serial sections were cut parallel to the longitudinal axis of the canines.

Sections were stained with hematoxylin and eosin. The prepared slides were encoded and sent to the Department of Pathology at Babol University of Medical Sciences where the measurement of the sizes of the infiltrate (quantitatively and qualitatively) were performed using an Olympus microscope (Olympus corporation, Tokyo, Japan) and immersion oil at magnification x 100. Also, the presence or absence of dentinal bridge was observed.

The histopathologic analysis was categorized into 3 grades according to the density of inflammatory cells, described as inflammation of pulp soft tissue, such as hyperemia, necrosis, the presence or absence of odontoblastic layer, the changes of pulp hard tissue, or dentinal bridge formation including location continuity (6) (Table 1). The four canines related to one cat were evaluated and categorized without any intervention. The statistical analysis was performed by SPSS software, X^2 , Fisher's Exact, Mann Whitney, and Kruskal-Wallis tests. The level of significance chosen in all statistical tests was $p < 0.05$.

Results

The treatment results of both study groups are shown in Table 2. In both groups, treated with MTA and capsaicin, the inflammation was decreased during weeks 1, 2, and 4.

Table 1. The utilized criteria for histopathologic evaluation of cat's pulp (6)

	0	1	2	3
Inflammation				
Type	No inflammation	Acute	Chronic	Mixture of acute and chronic
Intensity	No inflammation	Mild: less than 30 inflammatory cells	Intermediate: 30-60 inflammatory cells	Intense: More than 60 inflammatory cells
Soft tissue changes				
Hyperemia	Less than 3 blood vessels	3-5 blood vessels	More than 5 blood vessels	
Necrosis	No necrosis	A sign of necrosis		
Odontoblast layer cells	Absence of cells	Presence of cells		
Dentinal bridge or hard tissue bridge				
Location		Direct contact with capping agent	Nearby capping agent	No evidence of hard tissue formation
Continuity		Complete	Discontinuous contact with capping agent	Absence of dentinal bridge

Table 2. Comparison of indicators of treatment response in the groups treated with MTA and Capsaicin

ic Evaluation			Histolog	First Week		Second Week		Fourth week		All weeks		pvalue
			No.	MTA	CAP	MTA	CAP	MT	CAP	MTA	CAP	
				Frequency		Frequency		Frequency		Frequency		
Tooth pulp	Inflammation	Type	0	0	0	0	0	0	0	0	0	0.158
			1	0	0	0	1	0	0	0	1	
			2	4	1	3	2	4	4	11	7	
			3	0	3	1	1	0	0	1	4	0.223
		Severity	1	3	1	3	2	4	3	10	6	
			2	0	1	1	1	0	1	1	3	
		3	1	2	0	1	0	0	1	3		
	Hyperemia		1	1	2	1	0	2	4	4	6	0.155
			2	3	2	3	2	2	0	8	4	
			3	0	0	0	2	0	0	0	2	
	Necrosis		0	3	0	4	0	4	0	11	0	0.000
			1	1	4	0	4	0	4	1	12	
odontoblastic c ells layer		0	4	4	2	4	3	4	9	12	0.217	
		1	0	0	2	0	1	0	3	0		
Dentinal bridge	Location		1	0	0	2	0	1	0	3	0	0.091
			2	0	0	0	0	1	0	1	0	
			3	4	4	2	4	2	4	8	12	
	Continuity		1	0	0	1	0	1	0	2	0	0.091
			2	0	0	2	0	1	0	2	0	
			3	4	4	2	4	2	4	8	12	

Less inflammation was seen in MTA group but there was no statistical difference between the two groups (Figure 1).

In the group treated with capsaicin, necrosis was observed in every 12 samples, but in the other group treated with MTA, only 1 pulp necrosis was seen in the first week ($p=0.000$).

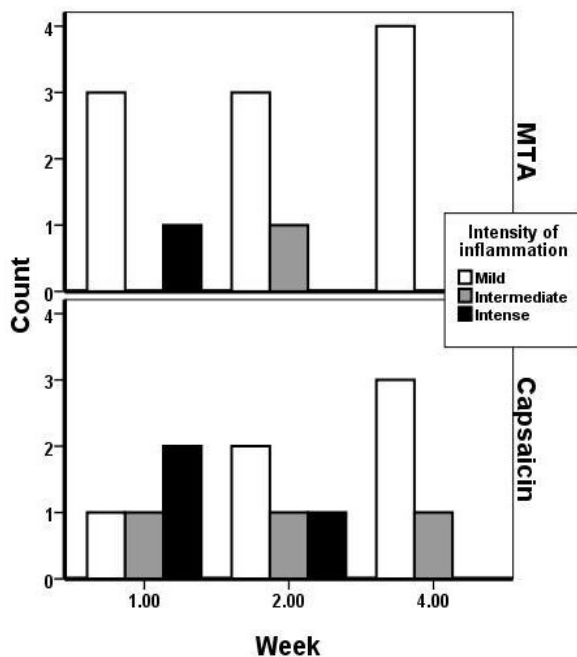


Chart 1. Comparison of inflammation severity between MTA and Capsaicin groups

In the cases treated with MTA, the formation of odontoblastic layer was seen in 3 samples but none in cases treated with capsaicin (Figure 2). Although no statistical difference was seen between the two groups in other treatment varieties during those weeks, in total, the group treated with MTA had better response to the treatment (Table 2).

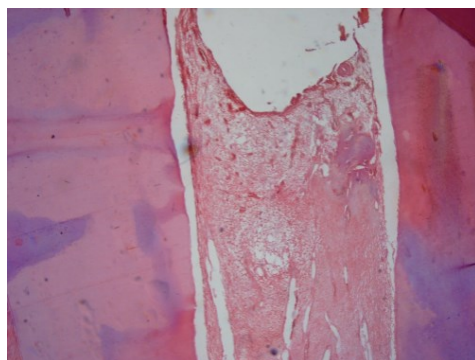


Figure 1. Inflammation in the group treated with Capsaicin

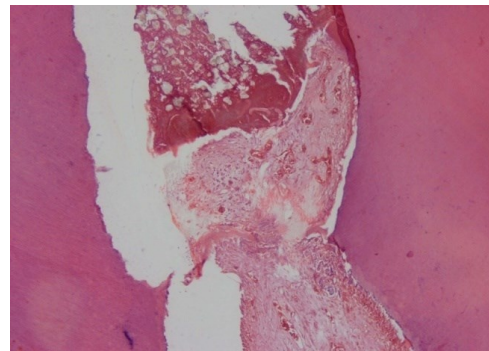


Figure 2. Formation of odontoblastic layer in the group treated with MTA

Discussion

In the present study, pulp necrosis (sign of necrosis) was seen in all the samples of capsaicin group, but only one necrosis was observed in MTA group after one week of treatment, and this difference is statistically significant. The result of necrosis in capsaicin group was similar to the results of the study of Hiura et al. (7) on rats. They demonstrated that necrosis was more than apoptosis in response to capsaicin.

Less occurrence of necrosis in MTA group was similar to the numerous previous studies. MTA is the least cytotoxic dental material (8-10). In this study, in both study groups, the inflammation decreased during weeks 1, 2, and 4. Less inflammation was seen in MTA group but there was no statistical difference between the two groups. Demir, Bilek et al. (11) used low and high dose of capsaicin on the modulation of systematic inflammatory response in different states of septicemia in rats. They demonstrated that low dose of capsaicin increased the anti-inflammatory effect of interleukin 10 (IL-10) and decreased the proinflammatory cytokine, NOX (nitrite/nitrate), and tissue MAD (Malondialdehyde) in the mice with septicemia.

According to Spiller et al. (12) Capsaicin could block the inflammatory cytokine in inflammation site. This hypothesis may justify the present study. Haung et al. (13, 14) declared that the amount of IL-4 and IL-10 increases significantly in the presence of MTA, and this may cause the anti-inflammatory effect of MTA.

Yoshimura et al. (15) used 1% capsaicin cream in their study. At first, it creates neurogenic inflammation (inflammation with neural origin), but then blocks the transmission of pain. In the current study, the frequency of hyperemia did not have significantly

difference between the two groups. In the study performed by Liu et al. (16) on cats, they demonstrated that the local use of capsaicin increased the circulation of tooth pulp and repeated exposure to capsaicin decreased the circulation. Hargreaves et al. (17) stated that adrenergic agonist due to its direct effect on susceptible pain receptors to capsaicin, relieves the pain and changes the blood circulation through the vascular obstruction and interrupts the transpiration of peripheral neuropeptides.

According to present studies, MTA had no adverse effect on capillary blood flow, and can only be effective on vasoconstriction (14). In our study, the formation of dentinal bridge was observed in 4 samples of MTA group, while there was no case of dentinal bridge formation seen in Capsaicin group. According to the study of on rats, MTA increased the mineralization through pulpal cells stimulation, and also increased bone morphogenic protein-2. Andelin et al. (14) reviewed the presence of dentin sialoprotein (DSP) after pulp capping with MTA.

They declared that according to DSP-positive staining of MTA capped pulps, the formed hard tissue under MTA treatment is more similar to dentine. According to the results of this study and the previous studies, Capsaicin can decrease the severity of inflammation, but it is ineffective in dentinal barrier formation.

Acknowledgments

The authors would like to thank Dr. Mohammad Reza Hamidzadeh, Dr. Seyed Gholamali Joorsarayi, Dr. Shervin Rezayi Majd, and Mrs. Alieh Sohan Faraji for their invaluable support.

Conflict of interest: We clarify that there is no conflict of interest in this article.

References

1. Hasheminia SM, Feizi G, Razavi SM, Feizianfard M, Gutknecht N, Mir M. A comparative study of three treatment methods of direct pulp capping in canine teeth of cats: a histologic evaluation. *Lasers Med Sci* 2010; 25: 9-15.
2. Singurdsson A, Trope M, Chivian N. The role of endodontic safter dental traumatic injuries In: Hargreaves KM, Cohen S. editors. *Cohen's Pathways of the Pulp* Expert Consult. 10thed. St. Louis, Missouri: Mosby Elsevier ; 2011. p. 620-54.
3. Talati A, Akbari H.A comparison of the effect of local application of capsaicin, zostrix & morphine to complete anesthesia of teeth with inflamed pulp and poor response to traditional local anesthetics. *J Mashad Dent Sch* 2003; 27: 31-6. [In Persian]
4. Basak S, Dikicioglu E, Turkutanit S, Sarierler M. Early and late effects of capsaicin pretreatment in otitis media with effusion. *Otol Neurotol* 2005; 26: 344-50.
5. Hoffmann P, Mazurkiewicz J, Holtmann G, Gerken G, Eysselein VE, Goebell H. Capsaicin-sensitive nerve fibres induce epithelial cell proliferation, inflammatory cell immigration and transforming growth factor-alpha expression in the rat colonic mucosa in vivo. *Scand J Gastroenterol* 2002; 37: 414-22.
6. Camps J, Déjou J, Rémusat M, About I. Factors influencing pulpal response to cavity restorations. *Dent Mater* 2000; 16: 432-40.
7. Hiura A, Nakae Y, Nakagawa H. Cell death of primary afferent nerve cells in neonatal mice treated with capsaicin. *Anat Sci Int* 2002; 77: 47-50.
8. Camilleri J, Montesin FE, Di Silvio L, Pitt Ford TR. The chemical constitution and biocompatibility of accelerated Portland cement for endodontic use. *Int Endod J* 2005; 38: 834-42.
9. Torabinejad M, Hong CU, Pitt Ford TR, Kettering JD. Cytotoxicity of four root end filling materials. *J Endod* 1995; 21: 489-92.
10. Keiser K, Johnson CC, Tipton DA. Cytotoxicity of mineral trioxide aggregate using human periodontal ligament fibroblasts. *J Endod* 2000; 26: 288-91.
11. Demirbilek S, Ersoy MO, Demirbilek S, Karaman A, Gürbüz N, Bayraktar N, et al. Small-dose capsaicin reduces systemic inflammatory responses in septic rats. *Anesth Analg* 2004; 99: 1501-7.
12. Spiller F, Alves MK, Vieira SM, Carvalho TA, Leite CE, Lunardelli A, et al. Anti-inflammatory effects of red pepper (*Capsicum baccatum*) on carrageenan- and antigen-induced inflammation. *J Pharm Pharmacol* 2008; 60: 473-8.
13. Huang TH, Yang CC, Ding SJ, Yeng M, Kao CT, Chou MY. Inflammatory cytokines reaction elicited by root-end filling materials. *J Biomed Mater Res B Appl Biomater* 2005; 73: 123-8.
14. Adelin WE, Shabahang S, Wright K, Torabinejad M. Indenti fication of hard tissue after experimental

- pulp capping using dentin sialoprotein (DS P) as a marker. J Endod 2003; 29: 646-50.
15. Yoshimura M, Yonehara N, Ito T, Kawai Y, Tamura T. Effects of topically applied capsaicin cream on neurogenic inflammation and thermal sensitivity in rats. Jpn J Pharmacol 2000; 82:116-21.
16. Liu M, Pertl C, Markowitz K, Dörscher-Kim J, Kim S. The effects of capsaicin on pulpal blood flow. Proc Finn Dent Soc 1992;88Suppl 1:463-7.
17. Hargreaves KM, Jackson DL, Bowles WR. Adrenergic regulation of capsaicin-sensitive neurons in dental pulp. J Endod 2003; 29: 397-9.