Caspian Journal of Dental Research
e-ISSN: 2322-2395 p-ISSN: 2251-9890
Babol University Of Medical Sciences

Evaluation of the Relationship between Anteroposterior Facial Growth Spurts and Cervical Vertebral Maturation Index in Girls and Boys

Zahra Nosratabadi [1], Mehdi Rafiei [2], Faranak Jalalian [3*]

1. Dental Student, Faculty of Dentistry, Isf.C, Islamic Azad University, Isfahan, Iran.
2. Assistant Professor, Department of Orthodontics, Faculty of Dentistry, Isf.C, Islamic Azad University, Isfahan, Iran.
3. Assistant Professor, Department of Oral and Maxillofacial Radiology, Faculty of Dentistry, Isf.C, Islamic Azad University, Isfahan, Iran.

Article Type

Research Paper

Received: 23 Sep 2024
Revised: 8 Jun 2025
Accepted: 7 Oct 2025
Pub. Online: 14 Oct 2025

ABSTRACT

Introduction: Using chronological age as the sole measure is insufficient for dental growth planning. The Cervical Vertebral Maturation Index (CVMI), assessed through lateral cephalometric images, predicts growth spurts by examining the second to fourth cervical vertebrae across six stages. The aim of this study was to find the relationship between CVMI and anteroposterior facial growth spurts in 8–15-year-old boys and girls.

Materials & Methods: This retrospective cross-sectional study analyzed 60 lateral cephalometric radiographs (30 boys, 30 girls). Participants had a skeletal Class I relationship. CVMI stages were determined, and anteroposterior facial dimensions were measured manually. Growth changes were analyzed across CVMI stages using ANOVA and the Tukey test (α=0.05).

Results: A significant relationship was found between CVMI and maxillary/mandibular growth spurts (p=0.001). However, there was no significant relationship between cranial base dimensions CVMI in both groups.

Conclusion: A noticeable growth spurt in the anteroposterior dimension of the mandible is CVMI stage 3 to 4, in both boys and girls. In maxilla for boys, it aligns with the transition from CVMI stage 2 to 3, while for girls, it occurs between stages 3 and 4.

Keywords: Vertebra, Spine, Cephalometry

Cite this article: Nosratabadi Z, Rafiei M, Jalalian F. Evaluation of the Relationship between Anteroposterior Facial Growth Spurts and Cervical Vertebral Maturation Index in Girls and Boys. Caspian J Dent Res 2024; 13(2): 109-117.

© The Author(s).
Publisher: Babol University of Medical Sciences

Introduction

Understanding the timing of puberty and growth spurts is crucial for planning orthodontic treatments, particularly when using functional devices. Incorrect timing due to insufficient knowledge can result in treatment failure. [1] Growth spurts during pre-puberty, puberty, and post-puberty are key periods for effective orthodontic intervention. Conditions such as skeletal deep bite, mandibular

*Corresponding Author: Faranak Jalalian, Department of Oral and Maxillofacial Radiology, School of Dentistry, Isfahan (Khorasgan) Branch, Islamic Azad University, Isfahan, Iran.
Tel: +98 9133162171
E-mail: Faranak_jalalian@yahoo.com

[Downloaded from cjdr.ir on 2026-11-25]
[DOI: 10.22088/cjdr.13.2.109]

prognathism, and maxillary stenosis are highly influenced by the level of skeletal maturity during treatment. [2] Evaluating a person's maturity should consider both chronological and biological age. [1]

Indicators of bone maturity include chronological age, height increase, wrist maturity, morphological changes in the vertebral column, voice changes, and dental growth. [3, 4] However, tooth eruption can be affected by local factors or systemic diseases, making it unreliable. [5, 6] The British Orthodontic Association discourages wrist radiography due to radiation exposure concerns. Therefore, lateral cephalometric radiographs, commonly used in orthodontic treatments, are preferred for spine examination. [7]

The Cervical Vertebrae Maturation Index (CVMI), first proposed by Farman and Hassel [1] and later updated by Baccetti in 2002 [8], assesses vertebral column maturity through six stages. These stages evaluate the lower border and surface of vertebral bodies (flat or concave) and analyze the shape of the C3 and C4 vertebrae, which typically change from a trapezoid to a horizontal rectangle, then a square, and finally a vertical rectangle. Stages one and two correspond to pre-puberty, stages three and four to puberty, and stages five and six to post-puberty. [1, 8] The CVMI method helps determine optimal treatment timing in transverse, sagittal, and vertical dimensions. Baccetti and Hagg successfully adapted cervical spine development stages to the growth spurt timing of the lower jaw, using the CVMI method to identify the right time for orthopedic treatment. [8]

Several studies have explored the relationship between cervical vertebrae morphology and growth patterns. Nogueira (2024) et al. conducted a study in China, stating that assessing cervical vertebral maturation is an appropriate method for evaluating growth spurts. Additionally. [9] Shoari et al. (2024) examined 200 lateral cephalometric images archived in the American Association of Orthodontists Foundation growth centers. [10] They concluded that cervical vertebral assessment could predict mandibular growth stages. In 2016, Hosseini et al. compared cervical vertebrae and wrist radiographs in Iranian children aged 8 to 18, noting that cervical vertebrae and wrist maturation stages occurred earlier in girls. [11]

In 2021, Anteprlie et al. in Croatia found that young individuals with horizontal and neutral growth patterns were typically in the fourth stage of skeletal maturity, while those with vertical growth patterns were in the third stage. [12] In 2021, Listania et al. in Indonesia studied the difference in anteroposterior dimensions of the face using the CVMI method, finding significant differences in vertebral column maturation stages in boys and girls, but no significant difference in the anterior dimensions of the cranial base. [1] According to the Profit's textbook, it is indeed possible to examine growth spurts using cross-sectional study designs. [13] Based on these findings, the present study aimed to investigate the relationship between facial growth spurts in the anteroposterior dimension on lateral cephalometric images and CVMI in boys and girls aged 8–15 years within a segment of the Isfahan population.

Materials & Methods

Samples:

This descriptive-analytical cross-sectional study examined 30 female and 30 male lateral cephalometric radiographs from the radiology department of Isfahan Azad School of Dentistry, selected through random sampling. All participants, aged 8–15 years, were of Iranian descent, had a

[Downloaded from cjdr.ir on 2026-11-25]

[DOI: 10.22088/cjdr.13.2.109]

skeletal Class I pattern [13], and had not undergone orthodontic treatment. The sample size for assessing differences in anteroposterior facial dimensions between girls and boys in this age group, using the cervical vertebral maturation index on lateral cephalometric radiographs, was calculated at a significance level of 0.05 ($\alpha = 0.05$) and a test power of 90% ($\beta = 0.1$), based on the results of Listania et al. (2021) [1], using the following formula:

$$n= (Z1-\alpha/2+Z1-\beta)\ 2\times (\sigma12+\sigma22)/ (\mu1-\mu2)2 = (1.96+1.28)2\times (1.82+2.64)2/ (98-96)2 =26.79$$

Accordingly, the required sample size for each gender group was approximately 27 individuals. Considering a 10% dropout rate, a minimum of 30 participants per group (girls and boys), and at least 60 participants in total, was determined.

Variable definitions:

n = sample size

Z = Z-value from the standard normal distribution

α = type I error (0.05)

β = type II error (0.1)

σ = standard deviation

μ = mean

Exclusion criteria were:

1. Unclear lateral cephalometric radiographs in which the 2nd, 3rd, and 4th cervical vertebrae are not visible.

2. Mental or physical disabilities (assessed via file review and phone interviews).

3. Facial deformities (determined by radiographic analysis and phone interviews).

4. Parafunctional habits (assessed by inquiring about symptoms such as teeth grinding, jaw pain after waking, stress, and bedwetting).

5. History of chronic disease (determined by phone interviews).

Data Collection:

Using the CVMI method [8], the maturity stage of each image was determined by evaluating the lower border of the second cervical vertebra and morphological changes in the third and fourth cervical vertebrae across six stages.

In Stage 1, the lower borders of C2, C3, and C4 are smooth, and C3 and C4 bodies are trapezoidal, with peak mandibular growth occurring approximately two years later. In Stage 2, a concavity appears in the lower border of C2, while C3 and C4 remain trapezoidal, with peak mandibular growth occurring one year after this stage. In Stage 3, concavities develop in C2 and C3, and the bodies of C3 and C4 transition into a trapezoidal or horizontal rectangular shape, with peak mandibular growth occurring within one year. In Stage 4, concavities appear in C2, C3, and C4, while C3 and C4 adopt a horizontal rectangular shape, indicating that peak mandibular growth occurred 1-2 years earlier. In Stage 5, concavities persist in C2, C3, and C4, with at least one of C3 or C4 becoming square or remaining horizontally rectangular, suggesting that peak mandibular growth ended at least one year prior. In Stage 6, concavities remain in C2, C3, and C4, with at least one of C3 or C4 appearing

[Downloaded from cjdr.ir on 2026-11-25]

[DOI: 10.22088/cjdr.13.2.109]

vertically rectangular while the other remains square, indicating that peak mandibular growth ended at least two years earlier.

After determining the CVMI stage for each individual, participants were categorized accordingly, and the anteroposterior facial dimensions were measured in lateral cephalometric images using manual tracing for each group. For this purpose, the following anatomical landmarks were manually traced in each radiograph [1]: ANS, PNS, Co (Condylion), Gn (Gnathion), Go (Gonion), Me (Menton), S (Sella), and N (Nasion).

Measurements included the ANS-PNS distance as an indicator of the anteroposterior dimension of the maxilla, the Co-Gn distance as the first indicator of the anteroposterior dimension of the mandible, the Go-Me distance as the second indicator of the anteroposterior dimension of the mandible, and the S-N distance as an indicator of the anteroposterior dimension of the cranial base. With each change in the CVMI stage, the greatest difference in the mean of the measured dimensions was used to determine the growth spurt.

Data Analysis:

Data analysis was conducted at both descriptive and inferential levels. Descriptive statistics included mean, standard deviation, and statistical charts. For inferential analysis, after verifying the normality of data with the Shapiro-Wilk test, parametric tests (Analysis of Variance and Tukey's post hoc test) were used. Tests were performed at a 5% error level using SPSS software version 26.

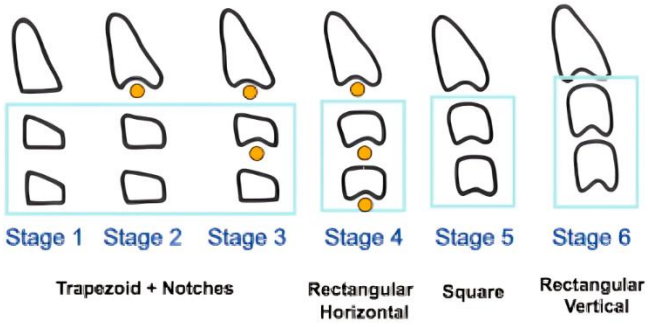

Figure 1. Maturation stages of CVMI. [1]

Statement of Ethics:

This research was approved with the code of ethics IR.IAU.KHUISF.REC.1402.307 at the Department of Dentistry of Islamic Azad University, Isfahan (Khorasgan) Branch.

Results

The average anteroposterior dimension of the cranial base across all samples was 64.5 mm in girls and 64.72 mm in boys. The average mandibular dimension (Go-Mn distance) measured 101.46 mm in girls and 102.76 mm in boys, while the average maxillary dimension was 50.20 mm in girls and 50.52 mm in boys. Also, the mean values of the measured dimensions for each CVMI stage, categorized by gender, are presented in Table 1.

[Downloaded from cjdr.ir on 2026-11-25]

[DOI: 10.22088/cjdr.13.2.109]

Table 1. Anteroposterior Cranial Base, Maxillary and Mandibular Dimensions in Lateral Cephalometric Images across CVMI Stages in Boys and Girls

Index	Sex	CVMI	Number	Average Dimensions	Shapiro-Wilk	P value
ANS-PNS	Girl	2	8	48.6	0.857	0.001
		3	12	49.91	0.65	
		4	10	52.80	0.34	
	Boy	2	9	47.0	0.923	0.001
		3	10	50.0	0.306	
		4	11	52.91	0.653	
S-N	Girl	2	8	63.63	0.627	0.59
		3	12	64.80	0.883	
		4	10	65.00	0.415	
	Boy	2	9	63.70	0.308	0.9
		3	10	65.10	0.055	
		4	11	65.20	0.162	
Co-Gn	Girl	2	8	97.20	0.783	0.001
		3	12	101.59	0.215	
		4	10	104.70	0.719	
	Boy	2	9	98.50	0.935	0.001
		3	10	101.50	0.066	
		4	11	107.40	0.609	
Go-Me	Girl	2	8	58.80	0.716	0.001
		3	12	60.20	0.950	
		4	10	65.27	0.882	
	Boy	2	9	58.60	0.914	0.001
		3	10	61.60	0.677	
		4	11	65.68	0.171	

ANS (Anterior Nasal Spine), PNS (Posterior Nasal Spine), Co (Condylion), Gn (Gnathion), Go (Gonion), Me (Menton), and CVMI (Cervical vertebrae maturation index).

The Shapiro-Wilk test confirmed that these components followed a normal distribution ($p > 0.05$). In Table 1, the ANOVA test identified significant relationships between the anteroposterior maxillary dimension in lateral cephalometric images and both mandibular indices in both sexes when categorized by CVMI ($P = 0.001$). Variables that showed a significant correlation with CVMI were included in Tukey's post hoc test (Table 2), which revealed significant differences between pairwise averages in both boys and girls across different CVMI stages. The largest variation in mean dimensions across CVMI stages was used to identify the growth spurt.

[Downloaded from cjdr.ir on 2026-11-25]

[DOI: 10.22088/cjdr.13.2.109]

Table 2. The relationship between growth spurts and CVMI with sex

Index	Sex	CVMI2-CVMI3		CVMI2-CVMI4		CVMI3-CVMI4	
		mean difference	P value	mean difference	P value	mean difference	P value
ANS-PNS	Girl	-1.3	0.001	-4.2	0.001	-2.89	0.001
	boy	-3.1	0.001	-5.9	0.001	-2.8	0.001
CO-GN	Girl	-4.39	0.001	-7.5	0.001	-3.1	0.001
	boy	-3	0.001	-8.9	0.001	-5.9	0.001
GO-MN	Girl	-1.4	0.62	-6.47	0.001	-5.07	0.003
	boy	-3	0.001	-7.08	0.001	-4.08	0.001

ANS (Anterior Nasal Spine), PNS (Posterior Nasal Spine), Co (Condylion), Gn (Gnathion), Go (Gonion), Me (Menton), and CVMI (Cervical vertebrae maturation index).

Discussion

A significant correlation was found between cervical vertebral maturation stages and the anteroposterior dimensions of the maxilla in lateral cephalometric images for both genders. This finding is fully consistent with the study conducted by Listania, which aimed to determine differences in anteroposterior facial dimensions using the CVMI method. [1] Since the mean measured dimensions in lateral cephalometric images significantly differed across different CVMI stages, the greatest mean difference during CVMI changes is considered a growth spurt. Therefore, in the present study, the maxillary growth spurt in the anteroposterior dimension occurred in girls during the transition from CVMI stage 3 to 4 and in boys from stage 2 to 3. Similarly, in the study by Listania, the maxillary growth spurt occurred in girls during the transition from CVMI stage 3 to 4 and in boys from stage 2 to 3. [1]

A study by Manabe et al. in Japan, which examined maxillary and mandibular growth in boys, also found that the maxillary growth spurt in boys coincided with the transition from CVMI stage 2 to 3, aligning with the present study. [14] The increase in the anteroposterior size of the maxilla is due to bone deposition in the posterior tuberosity region, which shifts the maxilla forward. [1]

In the present study, no significant difference was found between the cervical vertebral maturity index and the mean anteroposterior cranial dimensions in lateral cephalometric images for both girls and boys. Thus, no CVMI-related growth spurt is defined for the cranial base. This finding is in line with the results of Listania. [1] The reason for this lack of significant correlation is attributed to the peak growth period of the cranial base, which occurs before the age of 8 years. A study by Budiardjo et al. (2014) in Indonesia, which examined anteroposterior cranial base length in lateral cephalometric images of individuals aged 11–16 years, also confirmed this conclusion. [15] Additionally, a study by Afrand et al. investigating dimensional changes related to the timing of cranial base growth further supports this finding. [16]

[Downloaded from cjdr.ir on 2026-11-25]

[DOI: 10.22088/cjdr.13.2.109]

In the present study, a significant correlation was observed between the cervical vertebral maturation stage and the mean anteroposterior mandibular dimensions (Co-Gn) in lateral cephalometric images in both genders, which aligns with the findings of Listania. [1] Similarly, the study by Mostaghasi et al., which did not differentiate between genders, also found a significant relationship between these two variables. [17] Since the mean dimensions significantly differ across different CVMI stages, the greatest mean difference during CVMI changes is considered a growth spurt. Therefore, the mandibular growth spurt, based on the Co-Gn distance, coincided with the transition from CVMI stage 2 to 3 in girls and from stage 3 to 4 in boys, which is consistent with the findings of Listania. [1]

In the study by Manabe et al., conducted on boys, this growth spurt also coincided with the transition from CVMI stage 3 to 4 [14], aligning with the present study. In the study by Mostaghasi et al., the most significant change in the anteroposterior mandibular dimensions, regardless of gender, occurred simultaneously with the transition from CVMI stage 3 to 4 based on the measured distances. [17]

A study by Ball et al. in Canada, which analyzed 90 lateral cephalometric radiographs of boys aged 9 to 18 years to examine the relationship between mandibular growth and vertebral maturation, found that the mandibular growth peak occurred during CVMI stage 4. [18] Mandibular growth occurs due to periosteal bone deposition at the posterior edge of the ramus and resorption at its anterior part. Subsequently, as the body of the mandible lengthens, the posterior teeth gain space for eruption. The eruption of these teeth influences the growth of the alveolar bone in the mandible. This process, along with condylar growth, contributes to mandibular lengthening. The posterior-superior growth of the mandibular condyle increases the anteroposterior dimension of the mandible. [8] However, in the present study, another index was also used to measure the anteroposterior dimension of the mandible in lateral cephalometric images (the distance from Gn to Me).

In both genders, a significant correlation was found between the mean of these dimensions and CVMI in both genders, which is completely in line with the study of Listania. [1] Since the mean dimensions significantly differ across various CVMI stages, the greatest change in the mean distance mentioned for the mandible during CVMI transitions can be used to determine the growth spurt. In both girls and boys, this growth spurt coincided with the transition from CVMI stage 3 to 4. In general, according to the theory of craniocaudal growth in the human body, the mandible experiences a later growth spurt than the nasomaxillary complex and continues to grow for a longer period. [1]

In this study, researchers faced challenges due to the unclear visibility of the third and fourth cervical vertebrae in many radiographic images, which resulted from the use of a thyroid collar. Additionally, collecting samples with a skeletal Class I pattern while ensuring alignment with other inclusion and exclusion criteria, such as contacting patients by phone to verify their history of orthodontic treatment, presence of abnormalities, parafunctional habits, etc., was difficult. One of the limitations of the present study is the examination of growth spurts using a cross-sectional design.

It is recommended that similar studies be conducted using a prospective design in the future. It is recommended that future studies be conducted with a larger sample size, categorized according to different skeletal classifications, and that they examine the relationship between chronological age and the Cervical Vertebral Maturity Index. Additionally, it is suggested that this study be replicated in

[Downloaded from cjdr.ir on 2026-11-25]

[DOI: 10.22088/cjdr.13.2.109]

various regions and cities of Iran and across different ethnic groups. Conducting a prospective study may also be beneficial.

Conclusion

The growth spurt in the anteroposterior dimension of the mandible, considering the Go_Mn distance, coincides with the transition from CVMI stage 3 to 4 in both boys and girls. Therefore, this time frame is suitable for orthodontic treatment interventions.
The appropriate time for orthodontic treatment in the maxilla in the anteroposterior dimension is during the transition from CVMI stage 2 to 3 in boys, and from stage 3 to 4 in girls.

Acknowledgements

We would like to thank all those who helped us in this project.

Conflict of interest

All authors declare no conflict of interest.

Author's Contribution

Zahra Nosratabadi, Faranak Jalalian, Mehdi Rafiei designed the study, collected data and analyzed data, and wrote the manuscript. All authors read and approved the final manuscript.

References

1. Listania I. Kuswandari S, Kusuma Differences of anteroposterior facial dimensions in male and female children on intermediate mixed and early permanent dentition using Cervical Vertebrae Maturation Index. Padjadjaran Journal of Dentistry. 2021; 33: 271-8
2. Fernandes-Retto P, Matos D, Ferreira M, Bugaighis I, Delgado A. Cervical vertebral maturation and its relationship to circum-pubertal phases of the dentition in a cohort of Portuguese individuals. J Clin Exp Dent. 2019; 11: 642-9.
3. Pancherz H, Hägg U. Dentofacial orthopedics in relation to somatic maturation. An analysis of consecutive cases treated with the Herbst appliance. Am J Orthod. 1985; 88:273-87.
4. Chertkow S. Tooth mineralization as an indicator of the pubertal growth spurt. Am J Orthod 1980; 77:79-91.
5. Franchi L, Baccetti T, McNamara JA. Mandibular growth as related to cervical vertebral maturation and body height. Am J Orthod Dentofac Orthop 2000; 118:335-40
6. Uysal T, Ilhan Ramoglu S, Ayhan Basciftci F, Sari Kayseri Z. Chronologic age and skeletal maturation of the cervical vertebrae and hand-wrist: Is there a relationship? Am J Orthod Dentofac Orthop 2006; 130:622-8.
7. Isaacson K, Jones M. Guidelines for the use of radiographs in clinical orthodontics.ٔ British Orthodontic Society1994:1-32
8. Baccetti T, Franchi L McNamara J. The Cervical Vertebral Maturation (CVM) Method for the Assessment of Optimal Treatment Timing in Dentofacial Orthopedics. Semin Orthod 2005:11:119–129.
9. Nogueira-Reis F, Cascante-Sequeira D, Farias-Gomes A, et al. Determination of the pubertal growth spurt by artificial intelligence analysis of cervical vertebrae maturation in lateral cephalometric radiographs. Oral Surg Oral Med Oral Pathol Oral Radiol. 2024; 138:306-15.
10. Shoari SA, Sadrolashrafi SV, Sohrabi A, Afrouzian R, Ebrahimi P,et al. Estimating mandibular growth stage based on cervical vertebral maturation in lateral cephalometric radiographs using artificial intelligence. Prog Orthod. 2024; 25:28.

[Downloaded from cjdr.ir on 2026-11-25]

[DOI: 10.22088/cjdr.13.2.109]

11. Hoseini M, Zamaheni S, Bashizadeh Fakhar H, Akbari F, Chalipa J, et al. Comparative Evaluation of the Efficacy of Hand-Wrist and Cervical Vertebrae Radiography for the Determination of Skeletal Age. Iran J Radiol. 2016; 13:e21695.
12. Prlić A, Stunja M, Šimunović Aničić M, Anić Milošević S, et al. Skeletal Maturation in Different Vertical Facial Growth Pattern. Acta Stomatol Croat. 2021; 55:302-7.
13. Proffit, W.R., Fields, H., Larson, B. and Sarver, D.M., 2018. Contemporary Orthodontics-E-Book: Contemporary Orthodontics-E-Book. Elsevier Health Sciences.
14. Manabe A, Ishida T, Kanda E, Ono T. Evaluation of maxillary and mandibular growth patterns with cephalometric analysis based on cervical vertebral maturation: A Japanese cross-sectional study. PLoS One. 2022; 17:1-14.
15. Budiardjo SB, Karim AF, Indriati S, Wahono NA, Soetopo MS, Fauziah E et al. Length of anterior cranial base and Frankfort horizontal plane: A lateral cephalometric study in 11-16-year-old children. Journal of Physics: Conference Series. 2018; 1073:022014.
16. Afrand M, Ling CP, Khosrotehrani S, Flores-Mir C, Lagravère-Vich MO. Anterior cranial-base time-related changes: A systematic review. Am J Orthod Dentofacial Orthop. 2014; 146:21-32.
17. Mostaghasi S., Esnaashari N., Karimi M., Faizbakhsh M., Investigation of the relationship between cervical vertebrae maturation stages with posterior facial length and mandible dimensions and chronological age in children aged 9 to 15 years using computerized tomography imaging method." Professional Doctorate Thesis in Dentistry, Khorasgan Dental School, 2017 (In Persian).
18. Ball G, Woodside D, Tompson B, Hunter W, Posluns J. Relationship between cervical vertebral maturation and mandibular growth. Am J Orthod Dentofacial Orthop. 2011; 139:455-61.

[Downloaded from cjdr.ir on 2026-11-25]

[DOI: 10.22088/cjdr.13.2.109]