

## Subcutaneous emphysema as a complication of mandibular third molar extraction: A case report highlighting diagnostic imaging and surgical management strategies

Ali Bagherpour<sup>1</sup>, Zahra Jamali-paghaleh<sup>2\*</sup>

1. Professor, Department of Oral and Maxillofacial Radiology, School of Dentistry, Mashhad University of Medical Sciences, Mashhad, Iran.

2. DDS, Department of Oral and Maxillofacial Radiology, School of Dentistry, Mashhad University of Medical Sciences, Mashhad, Iran.

### Article type

### ABSTRACT

#### Case Report

Subcutaneous emphysema is a rare complication that can occur when air is forced under the skin, causing swelling and a crackling sensation on the touch. This study aimed to report a case of subcutaneous emphysema during mandibular wisdom tooth extraction emphasizing its diagnosis and management strategies.

A 47-year-old male experienced unilateral swelling on the left side of his face in the area of the mandibular angle following extraction of his lower left wisdom tooth. Cone-beam computed tomography (CBCT) and panoramic images revealed subcutaneous emphysema and displacement of the tooth root into the submandibular space. Immediate surveillance and pain mitigation were promptly commenced, leading to subsequent surgical intervention.

This research underscores the importance of accurate diagnosis and timely intervention in managing subcutaneous emphysema to prevent severe complications. Moreover, CBCT is needed to accurately diagnose emphysema and the status of tooth root displacement. Furthermore, it recommends utilizing a surgical handpiece instead of a turbine for tooth extraction in order to minimize the chances of encountering this uncommon yet severe complication.

**Received:** 1 Jun 2024

**Revised:** 8 Apr 2025

**Accepted:** 16 Apr 2025

**Pub. online:** 19 Apr 2025

**Keywords:** Subcutaneous emphysema, Third molar, Cone-beam computed tomography, Radiography, Panoramic.

**Cite this article:** Bagherpour A, Jamali-paghaleh Z. Subcutaneous emphysema as a complication mandibular third molar extraction: A case report highlighting diagnostic imaging and surgical management strategies: A case report. *Caspian J Dent Res* 2024; 13:58-64.



© The Author(s).

Publisher: Babol University of Medical Sciences

**\*Corresponding Author:** Zahra Jamali-paghaleh, Department of Oral and Maxillofacial Radiology, Faculty of Dentistry, Mashhad University of Medical Sciences, Mashhad, Iran.

**Tel:** +98 5138829501

**E-mail:** zahrajamalipa@gmail.com

## Introduction

Cervicofacial subcutaneous emphysema refers to the presence of air or gas accumulation beneath the skin in the cervicofacial region, which includes the neck, face, and surrounding tissues. <sup>[1]</sup> This condition occurs when air or gas infiltrates the subcutaneous layer, which is the layer of fat and connective tissue beneath the dermis (the outermost layer of the skin). <sup>[2]</sup> Wisdom tooth extraction is a frequently performed procedure in the fields of dentistry and stomatology. <sup>[3]</sup> However, the most prevalent postoperative complications include pain, infection, bleeding, trismus, injury to surrounding tissues, paresthesia of the inferior alveolar and lingual nerves, and adverse reactions to anesthesia. <sup>[4, 5]</sup>

While fractures of the maxilla or mandible and subcutaneous emphysema are uncommon, emphysema typically remains localized to the cervicofacial area. However, it has the potential to extend into the mediastinum, posing a serious risk to the patient's life. <sup>[3, 5]</sup> Subcutaneous emphysema can result from various factors, such as oral surgery (e.g., tonsillectomy, endodontic treatment), dental procedures, or trauma that leads to the release of air or gas into the subcutaneous tissues. <sup>[1]</sup> The air can then spread to deeper tissues, such as the fascial planes, causing a crackling sensation (crepitus) when the skin is palpated. <sup>[6]</sup> The most common symptom of subcutaneous emphysema is rapid swelling that generates crepitus on palpation of the affected area. <sup>[7]</sup>

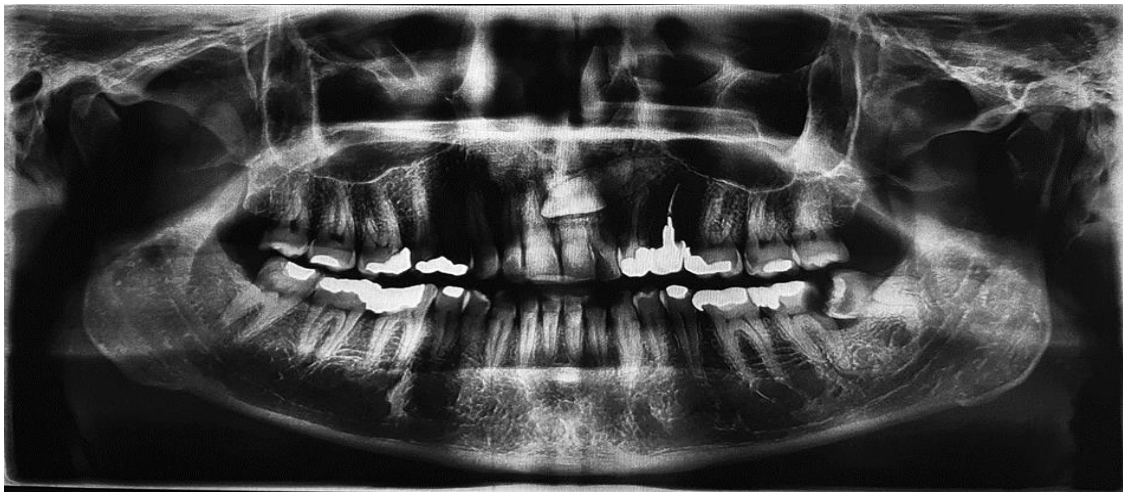Subcutaneous emphysema during mandibular wisdom tooth extraction is a rare but potentially serious complication. <sup>[8]</sup> It occurs when air is forced under the tissue, causing swelling, crepitus on palpation, and the possibility of spreading along the fascial planes. <sup>[9, 10]</sup> The most common cause of subcutaneous emphysema in dental procedures, including wisdom tooth extraction, is the use of air-driven handpieces, such as high-speed air turbine drills. These handpieces are used to section the tooth to facilitate extraction. <sup>[9, 10]</sup> Other factors that can contribute to subcutaneous emphysema during dental procedures include endotracheal intubation, positive pressure, and patient-induced factors such as smoking, coughing, or vomiting before healing takes place. Although subcutaneous emphysema is rare, it can be a potentially fatal complication if not diagnosed and treated promptly and correctly. <sup>[6, 11]</sup>

Diagnosis of subcutaneous emphysema typically involves a thorough clinical examination. Once diagnosed, antibiotic prophylaxis is recommended to avoid infections. <sup>[12]</sup> Rapid diagnosis and management of subcutaneous emphysema are essential to reduce the risk of further complications. <sup>[13]</sup> In the case of mandibular wisdom tooth extraction, subcutaneous emphysema can be managed by addressing the underlying cause, such as stopping the use of air-driven handpieces and providing supportive care, including pain management and monitoring for complications. <sup>[14]</sup> In some cases, patients may require referral to a specialized maxillofacial clinic for further evaluation and treatment. <sup>[15, 16]</sup>

Given the above, recent case reports illustrate the occurrence of cervicofacial subcutaneous emphysema complications, emphasizing its association with the use of air-driven handpieces during dental treatments, which can inadvertently force air into subcutaneous tissues. The importance of recognizing and managing cervicofacial subcutaneous emphysema is underscored by its potential to lead to severe complications, such as pneumothorax and mediastinitis, if not diagnosed and treated promptly. Therefore, this study aimed to report a case of subcutaneous emphysema during mandibular wisdom tooth extraction while highlighting diagnostic imaging and surgical management strategies.

## Case Report

All procedures of this study followed were in accordance with the ethical standards of the responsible committee on human experimentation (institutional and national) and with the Helsinki Declaration of 1975, as revised in 2008. This research project was approved by Mashhad University of Medical Sciences and conducted in the Dental Radiology Center, Mashhad University of Medical Sciences, Mashhad, Iran. The authors would like to express their gratitude to all those who sincerely participated in the study. A 47-year-old male patient was referred to a private dental clinic due to pain and the need for extraction of a wisdom tooth on the left side of the mandible. Following the initial examination, a panoramic image was taken. The image revealed that tooth #38 was in a mesioangular position with occlusal caries, leading to decay in the distal aspect of the second molar (Figure 1).

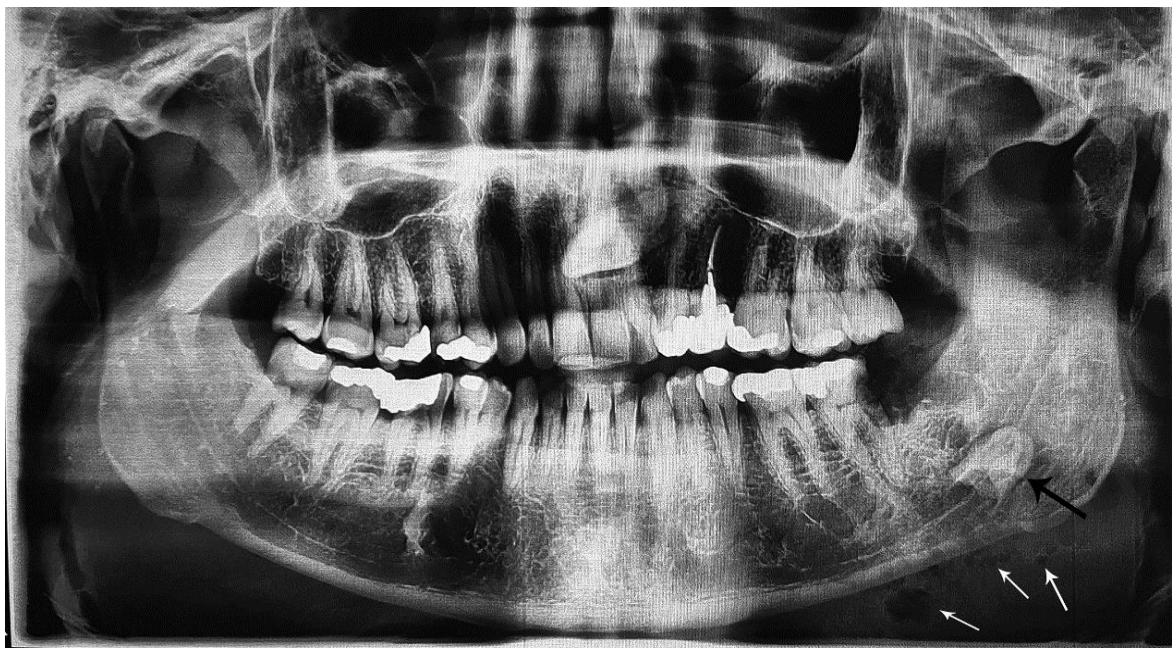

**Figure 1. Panoramic image at the first visit**

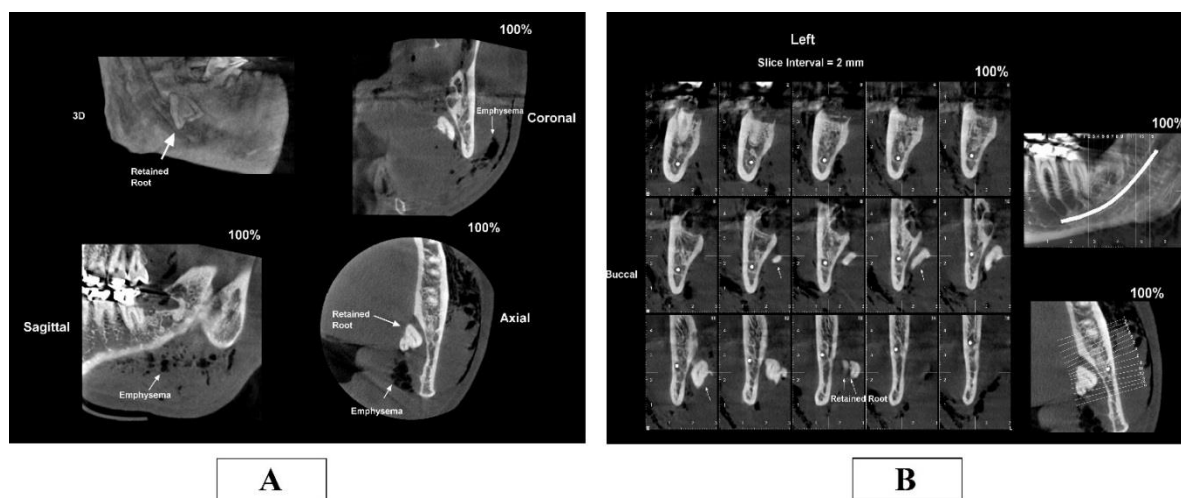
The patient had no significant systemic conditions in his medical history and no history of smoking. Based on these findings, the patient underwent surgery to extract the wisdom tooth. During the surgery, due to difficulties in extracting the teeth simultaneously, an air-driven high-speed turbine was used for the crown or root section. Subsequently, swelling occurred on the left side of the patient's face. As extraction of the tooth was unsuccessful, the surgery was halted, and the surgical site was sutured using a 3-0 silk suture.

The patient was promptly referred to a dental radiology center for further evaluation. The patient presented with severe pain and tenderness upon palpation, accompanied by swelling on the left side of the face. A panoramic view revealed wisdom tooth root displacement to the submandibular space and subcutaneous emphysema (Figure 2). Then, Cone Beam Computed Tomography (CBCT) was used to examine the status of tooth root displacement. So, the CBCT image confirmed these findings, showing emphysema presence and tooth root displacement (Figure 3A, B).





**Figure 2.** Panoramic image was conducted after the first surgical intervention. Displaced left mandibular third molar root (black arrow), and emphysema were seen (white arrows).



**Figure 3.** CBCT scans obtained after emphysema developed. A: Coronal, Sagittal, and Axial views of the emphysema and retained root of the wisdom tooth. B: Cross-sectional view of the retained root.

Following this diagnosis, the patient was referred to the Faculty of Dentistry for a second surgery under general anesthesia. Access to the floor of the mouth was achieved through a lingual sulcus incision, allowing for the extraction of the remaining root of the mandibular wisdom tooth. Post-surgery, the patient was closely monitored until stabilization, with normal vital signs (heart rate, blood pressure, respiration, temperature) and oxygen saturation levels. To aid in recovery, a prescription of Amoxicillin (1.5 gr/day for 7 days) and acetaminophen (500 mg/6 h for 3 days) was provided. Subsequent follow-up appointments showed significant improvement in the patient's clinical symptoms, including pain and swelling reduction.

## Discussion

Subcutaneous emphysema is rare but can occur during mandibular wisdom tooth extraction. Prompt diagnosis are necessary, and patients should be referred to a specialized maxillofacial clinic for thorough clinical examination and treatment. <sup>[6, 11]</sup> In our case report, a 47-year-old patient was referred to a clinic for wisdom tooth extraction of the left side of the mandible. During the surgery, an air-driven high-speed turbine was used for the crown or root section, which resulted in swelling on the left side of the patient's face, displacement of the tooth root to the submandibular space, and subcutaneous emphysema. In line with our study, Melville et al. (2019) reported that air could have been forced into the subcutaneous tissue during a dental procedure. <sup>[14]</sup>

This phenomenon is associated with the use of high-speed air turbine handpieces. Subcutaneous emphysema, a rare but serious complication, can result from the forced air. To minimize the risk of such complications, the use of specific surgical handpieces that are electric or nitrogen-driven is recommended, as they do not run on air. <sup>[17]</sup> The finding of our study was aligned with Ohta et al. (2019), reinforcing the importance of utilizing alternative surgical handpieces, such as electric or nitrogen-driven tools, to minimize risks. <sup>[17]</sup> In our case report, the patient had severe pain and tenderness to palpation, swelling on the left side of the face, and paresthesia of the tongue.

The patient was immediately referred to the radiology center for panoramic and CBCT images. In this regard, it has been shown that symptoms of subcutaneous emphysema include a smooth bulge in the skin and a sensation of pressure in the area. In mild cases, a healthcare professional may observe a patient's symptoms and wait for the swelling to resolve. However, in more serious cases, a dentist may make an incision and insert a drain to relieve the gas and pressure. <sup>[18]</sup> If subcutaneous emphysema obstructs the thoracic outlet, it can prevent adequate airflow, reduce cardiac preload, and result in poor cerebral perfusion. Therefore, anyone who experiences symptoms of subcutaneous emphysema should seek immediate medical attention. <sup>[18]</sup>

In our case report, the patient's clinical symptoms after the second surgery improved after one week.

After a dental procedure, physicians may link immediate difficulty in breathing and swelling to an allergic reaction or angioedema, while delayed symptoms could be attributed to conditions such as hematoma or soft tissue infections like cellulitis, angina, or Lemoore's syndrome. Patients with isolated subcutaneous emphysema typically present with painless swelling of the face and neck; however, the presence of a distinctive crackling sensation (crepitus) when the skin is pressed is characteristic and differentiates it from other causes. <sup>[19]</sup>

In our study, CBCT and panoramic images were utilized to confirm the presence of emphysema and displacement of the tooth root into the submandibular space. In line with our study, several studies have reported that the use of imaging techniques such as CBCT and panoramic radiography can be valuable in diagnosing and managing subcutaneous emphysema related to dental treatment. While intraoral and panoramic radiographs may not always provide definitive evidence of this complication, CBCT can be more effective in detecting pockets of air. <sup>[7, 16, 20]</sup> A case series highlighted the use of computed tomography and three-dimensional (3D) images to evaluate the extent and progression of emphysema, with CT being particularly useful for lesion localization and differential diagnosis.

Both CBCT and CT imaging play significant roles in assessing and managing subcutaneous emphysema following dental procedures. <sup>[7, 16, 20]</sup> This case of subcutaneous emphysema following mandibular wisdom tooth extraction highlights its rarity and seriousness as a potential dental

complication, underscoring the need for prompt diagnosis and referral to specialized clinics. By documenting this case, we aim to raise awareness among dental practitioners about the risks of air-driven handpieces that can lead to forced air infiltration. Our findings align with previous studies,<sup>[17]</sup> reinforcing the use of electric or nitrogen-driven tools to minimize risks and improve patient outcomes.

## Conclusion

Subcutaneous emphysema is a rare but serious complication during mandibular wisdom tooth extraction. Immediate medical attention and diagnostic imaging, such as panoramic radiography and CBCT, are essential for confirming the diagnosis and guiding treatment. Electric or nitrogen-driven tools are recommended to mitigate risks.

### Ethical declarations

This research project was approved by Mashhad University of Medical Sciences. The authors affirm that written informed consent for the dissemination of the data for the educational and research was obtained from the patient. All procedures were carried out in accordance with the provisions of the Declaration of Helsinki of 2013.

## Author's Contribution

Ali Bagherpour: Study design, data curation, writing and proofreading. Zahra Jamali-paghaleh: literature search, data curation, writing and proofreading.

## References

1. Chrysovitiotis G, Boutsikou A, Kollia P, Chrysovergis A. Cervicofacial subcutaneous emphysema following dental procedure. *BMJ Case Rep.* 2021; 14:1-2.
2. Rad MV, Chan EKY, Ahmed IH. Cervicofacial subcutaneous emphysema and pneumomediastinum secondary to dental treatment in a young man. *Respir Med Case Rep.* 2019; 28:1-3.
3. Olate S, Assis A, Freire S, de Moraes M, de Albergaria-Barbosa JR. Facial and cervical emphysema after oral surgery: a rare case. *IJCEM.* 2013; 6:840- 44.
4. Peters M, Shall F, Evrard L. Pneumomediastinum after Third Molar Extraction: Case Report, Physiopathology, and Literature Review. *Case Reports in Dentistry.* 2023:1-10.
5. North L, Sulman C. Subcutaneous emphysema and vocal fold paresis as a complication of a dental procedure. *Int J Pediatr Otorhinolaryngol.* 2019; 124:76-8.
6. Sarfi D, Haitami S, Farouk M, Ben Yahya I. Subcutaneous emphysema during mandibular wisdom tooth extraction: Cases series. *Annals of medicine and surgery.* 2021; 72:1-5.
7. Bai YP, Sha JJ, Chai CC, Sun HP. With two episodes of right retromandibular angle subcutaneous emphysema during right upper molar crown preparation: A case report. *World J Clin Cases.* 2023; 11:4698-706.
8. Sun J, Zhang L, Zhang C, Hou B. Etiology, Diagnosis, and Treatment Strategy of Dental Therapy-related Subcutaneous Emphysema. *Dental Hypotheses.* 2024; 15:48-51.
9. Romeo U, Galanakis A, Lerario F, Daniele GM, Tenore G, Palaia G. Subcutaneous emphysema during third molar surgery: a case report. *Braz Dent J.* 2011; 22:83-6.
10. Tan S, Nikolarakos D. Subcutaneous emphysema secondary to dental extraction: A case report. *Aust Dent J.* 2017; 62:95-7.
11. Tomasetti P, Kuttenger J, Bassetti R. Distinct subcutaneous emphysema following surgical wisdom tooth extraction in a patient suffering from 'Gilles de la Tourette syndrome'. *J Surge Case Rep* 2015; 6: 1-3.

12. Jeong C-H, Yoon S, Chung S-W, Kim J-Y, Park K-H, Huh J-K. Subcutaneous emphysema related to dental procedures. JKAOMS 2018; 44:212-9.
13. Medeiros B. Subcutaneous emphysema, a different way to diagnose. RAMB. 1992. 2018; 64:159-63.
14. Melville JC, Balandran SS, Blackburn CP, Hanna IA. Massive self-induced subcutaneous cervicofacial, pneumomediastinum, and pneumopericardium emphysema sequelae to a nondisplaced maxillary wall fracture: a case report and literature review. JOMS. 2019; 77: 1- 8.
15. Saito Y, Kawai T, Kogi S, Onodera K, Obara M, Takeda K, et al. Clinical evaluation of subcutaneous emphysema caused by dental treatments. J Oral Maxillofac Surg Med Pathol. 2022; 34:813-6.
16. Shimizu R, Sukegawa S. Subcutaneous Emphysema Related to Dental Treatment: A Case Series. InHealthcare. 2022; 10:1-10.
17. Ohta K, Yoshimura H, Ryoke T, Matsuda S, Yoshida H, Omori M, et al. Investigation of the electric handpiece-related pneumomediastinum and cervicofacial subcutaneous emphysema in third molar surgery. J Hard Tissue Biol. 2019; 28:79-86.
18. O'Reilly P, Chen HK, Wiseman R. Management of extensive subcutaneous emphysema with a subcutaneous drain. Respirol Case Rep. 2013; 1:28-30.
19. Brzycki RM. Case Report: Subcutaneous Emphysema and Pneumomediastinum Following Dental Extraction. Clinical practice and cases in emergency medicine. 2021; 5:58-61.
20. Wong P, Palacios S, Kashtwari D. Managing subcutaneous emphysema following dental procedures. Decisions in Dentistry. 2017; 3:36-9.