

Evaluation of the buccolingual position of maxillary and mandibular anterior teeth roots by cone-beam computed tomography (CBCT)

Naghmeh Nasrollahi¹, Ali Bijani², Sina Haghanifar³✉

1. Postgraduate Student, Student Research Committee, Babol University of Medical Sciences, Babol, IR Iran. **ORCID** (0000-0001-7764-8903)
2. Assistant Professor, Social Determinants of Health Research Center, Health Research Institute, Babol University of Medical Sciences, Babol, IR Iran.
3. Professor, Oral Health Research Center, Health Research Institute, Babol University of Medical Sciences, Babol, IR Iran.

✉**Corresponding Author:** Sina Haghanifar, Department of Oral and Maxillofacial Radiology, Faculty of Dentistry, Babol University of Medical Sciences, Babol, IR Iran.

Email: s.haghanifar@mubabol.ac.ir

Tel: +981132291408

ORCID (0000-0001-5949-8913)

Received: 22 Dec 2019 Accepted: 16 Mar 2020

Abstract

Introduction: Evaluation of the position of anterior teeth in the alveolar bone for planning implant treatments is so important. The aim of this study was to evaluate the thickness of buccolingual/palatal bone at anterior teeth roots and the angle between the tooth root axis and alveolar bone axis.

Materials & Methods: In this cross-sectional study, the position of root apex, angle between the tooth root axis and alveolar bone axis as well as thickness of buccolingual/palatal bone in 2,4,6 mm from alveolar crest and root apex areas were evaluated in the cone-beam computed tomography (CBCT) scans of 360 maxillary and mandibular anterior teeth. The data were then analyzed by ANOVA and t-test.

Results: Twenty eight females and 27 males with the mean age of 43.13 ± 10.91 participated (181 female teeth and 179 male teeth) in the current study. In maxillary anterior teeth, the buccal bone thickness was thinner than the palatal bone and was significantly smaller in females than males ($p \leq 0.0001$). The thinnest area in buccal bone was in 4mm from alveolar crest in female's lateral incisor of maxilla (0.09 ± 0.02). The thickness of the palatal bone in the maxillary lateral incisors was significantly thicker in females than males. The thickness of lingual bone was thicker in mandibular lateral incisors and canines than in buccal bone and the lingual bone thickness was significantly thicker in males than females. The apex position of anterior teeth was predominantly buccally in the maxilla (%94), while it was middle in the mandible (%44).

Conclusion: Due to the small thickness of buccal bone, evaluation of the position of implant fixtures in maxillary anterior teeth is of great importance.

Keywords: Cone-beam computed tomography, Maxilla, Mandible, Tooth, Bone

Citation for article: Nasrollahi N, Bijani A, Haghanifar S. Evaluation of the buccolingual position of anterior teeth roots by cone-beam computed tomography (CBCT). *Caspian J Dent Res* 2020; 9:42-8.

بررسی موقعیت باکولینگوالی ریشه دندان های قدامی فکین با استفاده از توموگرافی کامپیوتری با اشعه مخروطی

نغمه نصراللهی^۱، علی بیژنی^۲، سینا حقانی فر^{۳*}

۱. دانشجوی دستیاری، کمیته تحقیقات دانشجویی، دانشگاه علوم پزشکی بابل، بابل، ایران.
 ۲. استادیار، مرکز تحقیقات عوامل اجتماعی موثر بر سلامت، پژوهشکده سلامت، دانشگاه علوم پزشکی بابل، بابل، ایران.
 ۳. استاد، مرکز تحقیقات سلامت و بهداشت دهان، پژوهشکده سلامت، دانشگاه علوم پزشکی بابل، بابل، ایران.
- *نویسنده مسئول: سینا حقانی فر، گروه رادیولوژی دهان، فک و صورت، دانشکده دندانپزشکی، دانشگاه علوم پزشکی بابل، بابل، ایران.
 پست الکترونیکی: s.haghanifar@mubabol.ac.ir تلفن: +۹۸۱۱۳۲۲۹۱۴۰۸

چکیده

مقدمه: بررسی موقعیت ریشه دندان های قدامی در استخوان الوتول جهت طرح ریزی درمان های ایمپلنت از اهمیت بالایی برخوردار است. هدف از این مطالعه ارزیابی میزان ضخامت استخوان باکال و لینگوال/پالاتال در ناحیه ریشه دندان های قدامی فکین و زاویه محور ریشه دندان ها با محور استخوان الوتول می باشد.

مواد و روش ها: در این مطالعه مقطعی، اسکن های CBCT ۳۶۰ دندان قدامی فک بالا و پایین درمقاطع کراس سکشنال موقعیت آپکس ریشه، زاویه محور ریشه دندان ها با محور استخوان الوتول و ضخامت استخوان باکال و لینگوال/پالاتال در ۲ و ۴ میلیمتری از کرسٹ آلتول و در ناحیه آپکس ریشه مورد ارزیابی قرار گرفت. سپس داده ها توسط آزمون های اماری T-test و ANOVA مورد تجزیه و تحلیل قرار گرفت.

یافته ها: ۲۸ خانم و ۲۷ آقا با میانگین سنی ۴۳/۱۳ ± ۱۰/۹۱ (۱۸۱ دندان خانم و ۱۷۹ دندان آقا) مورد بررسی قرار گرفتند. در دندان های قدامی فک بالا ضخامت استخوان باکالی کمتر از پالاتالی بوده و در بانوان به طور معناداری کمتر از آقایان بوده است (p < 0.0001). کم ضخامت ترین ناحیه در ۴ میلیمتری از کرسٹ آلتول استخوان باکالی دندان لاترال فک بالا بانوان مشاهده گردید (۰/۰۹ ± ۰/۰۲). همچنین ضخامت استخوان پالاتالی در ناحیه لترال فک بالا در بانوان به طور معناداری بیشتر از آقایان بوده است. ضخامت استخوان لینگوال در لترال و کانین فک پایین بیشتر از ضخامت استخوان باکال بوده و در آقایان ضخامت استخوان لینگوال به طور معناداری بیشتر از بانوان بوده است. در فک بالا موقعیت آپکس ریشه دندان های قدامی عمدتاً باکالی و در فک پایین بیشتر موارد میانی بوده است.

نتیجه گیری: ارزیابی موقعیت قرار گیری فیکسچر ایمپلنت در ناحیه دندان های قدامی فک بالا با توجه به ضخامت کم استخوان باکالی در ناحیه ریشه دندان های قدامی از اهمیت بالایی برخوردار است.

واژگان کلیدی: توموگرافی کامپیوتری با اشعه مخروطی، فک بالا، فک پایین، دندان، استخوان

Introduction

One of the crucial factors in planning implant treatment is the tooth root position in the alveolar bone. [1] If the implant is inserted in the socket of the extracted tooth exactly at the same angle as the root in the alveolar bone, the prosthesis crown is in its ideal position. However, following tooth extraction, inevitable changes such as resorption and remodeling of alveolar bone are occurred, especially in the buccal bone; hence, careful evaluation of the area is essential. [2] The implant position in the alveolar bone socket of teeth is one of the most important determinants of long-term

maintenance of implant in terms of aesthetics and function. [1-3] Although the implant position should be determined based on future reconstruction plans, implant placement along the longitudinal axis of the crown is often limited due to the morphology of the alveolar ridge. In addition to the root position in the alveolar bone, the thickness of buccal and lingual walls plays a vital role in achieving ideal treatment and determining the exact size of the implant. [1-3] In some studies, a large group of maxillary central and lateral incisors were buccal and had a thin wall. Moreover, the

buccal alveolar bone wall in the lateral incisors was significantly thinner than that of central incisors. [1, 4] Therefore, in order to maintain aesthetics in the anterior region, some implants should be placed lingual. [5, 6]

Cross-sectional view of the roots of the teeth can show well the occurrence of buccal and lingual perforations, and the cone-beam computed tomography (CBCT) images provide important information on teeth root position in the alveolar bone and its angle along the longitudinal axis. The images can precisely determine the thickness of residual bone in buccal and lingual walls to prevent perforation. [2, 6, 7] Therefore, to assess the risk, diagnostic images should be taken prior to implant placement.

The goal of this research was to evaluate the buccal and lingual/palatal alveolar bone thickness in different areas of anterior teeth roots and the angle of roots in alveolar bone.

Materials & Methods

In the current cross-sectional study, the CBCT images of the maxillary and mandibular incisors of 55 patients, referred to a private Maxillofacial Radiology Center for various medical practices from 2014 to 2018 were evaluated after obtaining the ethical approval from Babol University of Medical Sciences (IR.Mubabol.HRI.REC.1397.224)

The inclusion criteria were: the patients who were >20 years with class I occlusion and at least had one maxillary or mandibular central or lateral incisor or canine without any dental caries or fracture. The exclusion criteria were: patients who had incisors with deformed root, bi-rooted, root canal therapy with periapical lesions, external root resorption and chronic periodontitis as well as patients who had bone complications or used drugs that affect the bone metabolism. A total of 360 maxillary and mandibular central/lateral incisors and canines CBCT scans of 27 male and 28 female patients (n=55) with the mean age of 43.13 ± 10.91 (ranged 22-70) were studied.

All CBCT scans were taken by Soredex Cranex 3D (Helsinki, Finland) with field of view: 6x8 cm, voxel size: 0.2 mm, kvp: 89 and mA: 6. Then, using Ondemand 3D Dental software, the curves were plotted, and the location of root apex, positioning the angle of roots in alveolar bone, and thickness of lingual/palatal and buccal bone were assessed with interval and thickness of 1 mm in cross-sectional plane.

Positioning the angle of roots in the alveolar bone was determined based on the angle between the longitudinal axes of the anterior teeth and the alveolar bone. For this purpose, the midpoints of the buccolingual alveolar bone were first determined in the crestal region and next, the apex of the anterior tooth and points were connected; after that, a line was plotted from the apex area of the root to the crown edge as the longitudinal axis of the anterior tooth, and then the angle between the two lines was measured (Figure 1).

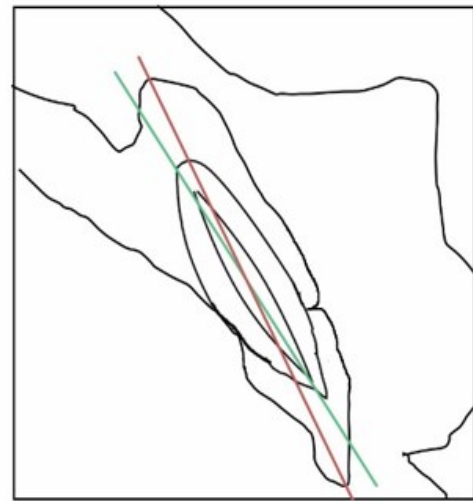


Figure 1. Angle between the longitudinal axes of the anterior teeth and alveolar bone.

The root apex position of maxillary and mandibular incisors and canines in the alveolar bone was evaluated as buccal, middle, and palatal (lingual) types. (1) (Figure 2).

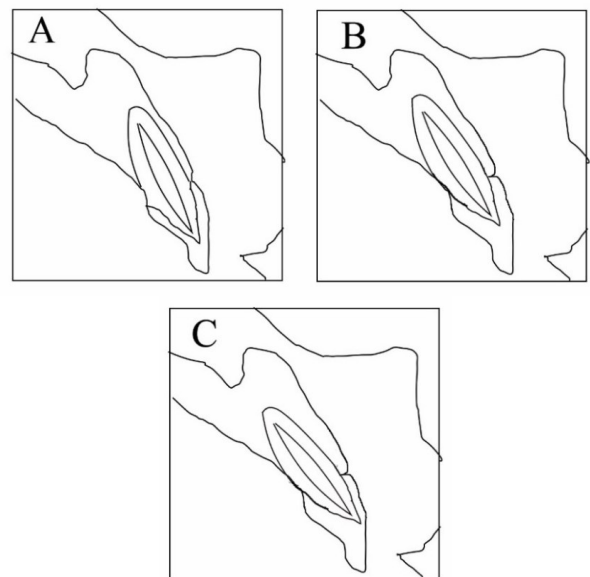


Figure 2. The root apex position in the alveolar bone A: Buccal type B: Middle type C: Palatal type

- A. Buccal type: the apical point of the tooth is within the buccal third of the alveolar bone and the root is closer to the buccal bone wall.
- B. Middle type: the apical point of the tooth is within the middle third of the alveolar.
- C. Palatal type: the apical point of the tooth is within the palatal third of the alveolar bone and the root is closer to the palatal bone wall.

The thickness of buccal and lingual bones was measured at four points perpendicular to the longitudinal axis of the maxillary and mandibular incisors and canines in the alveolar bone 2, 4, and 6 mm from the alveolar crest and root apex (Figure 3&4). All calculations were performed by the same examiner; moreover, to assess intra-examiner agreement, 36 teeth were selected and accordingly, measured by the same examiner, and the obtained correlation coefficient was 0.8.

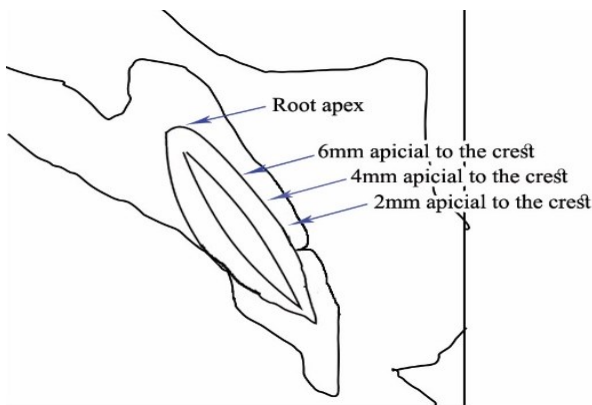


Figure 3. Measuring the thickness of alveolar bone in the marked regions

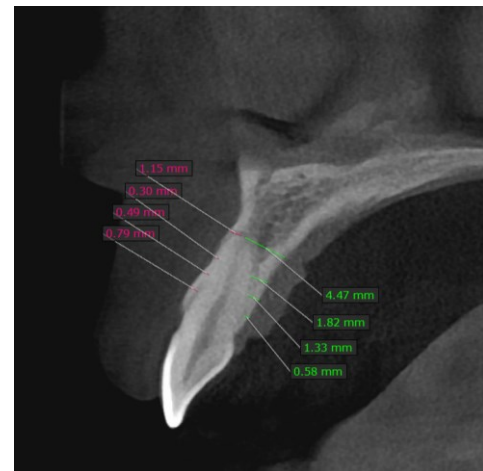


Figure 4. Measuring the thickness of alveolar bone in the marked regions in CBCT

The obtained data were analyzed by SPSS using AVONA and t-test; $P < 0.05$ was considered as significant level.

Results

The thickness of the buccal bone was thinner than that of the lingual bone in the maxillary incisors, and except for the thickness in the apex of the central incisors, the buccal bone thickness was significantly thinner in females than males. Besides, the palatal bone thickness was significantly thicker in females than males (Table 1).

Table1. Buccal and palatal bone thickness at 2, 4, 6 mm apical to the alveolar crest and at root apex in maxillary incisors

	Central		pvalue	lateral		pvalue	Canine		pvalue
	Female (N=29)	Male (N=30)		Female (N=24)	Male (N=26)		Female (N=21)	Male (N=27)	
	Mean±SD	Mean±SD		Mean±SD	Mean±SD		Mean±SD	Mean±SD	
B2 *	0.37±0.06	0.74±0.24	P<0.0001	0.4±0.03	0.83±0.1	P<0.0001	0.36±0.08	1.08±0.24	P<0.0001
B4 [∅]	0.1±0.01	0.63±0.12	P<0.0001	0.09±0.02	0.49±0.15	P<0.0001	0.15±0.03	0.77±0.25	P<0.0001
B6 [°]	0.25±0.1	0.51±0.16	P<0.0001	0.1±0.01	0.45±0.16	P<0.0001	0.22±0.16	0.48±0.01	P<0.0001
Ba ^{zz}	1.37±0.44	1.4±0.17	P=0.73	0.95±0.6	1.65±0.54	P<0.0001	0.75±0.48	1.54±0.46	P<0.0001
L2**	1.32±0.55	1.16±0.33	P=0.179	0.96±0.33	0.63±0.04	P<0.0001	0.84±0.37	1.09±0.26	P=0.009
L4 [∅]	2.19±0.82	2.1±0.48	P=0.607	1.68±0.6	1.22±0.3	P=0.001	1.35±0.73	1.47±0.04	P=0.397
L6 [°]	2.98±0.9	3.09±0.56	P=0.574	2.43±0.83	2.06±0.31	P=0.039	2.46±0.83	2.36±0.17	P=0.544
La ^{zz}	6.87±1.07	6.6±0.36	P=0.196	5.64±1.59	4.64±0.71	P=0.006	8.53±2.4	7.06±0.38	P=0.003

B2*: 2mm apical to the buccal crestal bone L2**: 2mm apical to the palatal crestal bone
 B4[∅]: 4mm apical to the buccal crestal bone L4[∅]: 4mm apical to the palatal crestal bone
 B6[°]: 6mm apical to the crest buccal L6[°]: 6mm apical to the palatal crestal bone
 Ba^{zz} & La^{zz}: Root apex at buccal & lingual side of the alveolar bone

Measurements showed that in mandibular lateral incisors and canines, the lingual bone thickness was thicker than the buccal bone, and the lingual bone thickness was significantly thicker in males than

females (Table 2). The apex position of the maxillary incisors and canines was predominantly buccal, but most of the cases in mandible were middle and buccal (Table 3).

Table 2. Buccal and Lingual bone thickness at 2, 4, 6 mm apical to the alveolar crest and at root apex in mandibular incisors.

	Central		pvalue	lateral		pvalue	Canine		pvalue
	Female (N=33) Mean±SD	Male (N=29) Mean±SD		Female (N=37) Mean±SD	Male (N=35) Mean±SD		Female (N=21) Mean±SD	Male (N=27) Mean±SD	
B2*	0.56±0.4	0.65±0.28	P=0.31	0.27±0.21	0.39±0.29	P=0.047	0.1±0.01	0.55±0.1	P<0.0001
B4	0.67±0.78	0.94±0.19	P=0.074	0.22±0.15	0.11±0.01	P=0.0001	0.16±0.09	0.35±0.13	P<0.0001
B6	1.06±1.06	1.65±0.1	P=0.004	0.17±0.13	0.34±0.23	P=0.0002	0.32±0.22	0.46±0.34	P=0.043
Ba	2.09±1.67	2.94±0.03	P=0.008	2.92±0.99	3.01±0.28	P=0.605	3.82±1.96	1.38±0.83	P=0.091
L2**	0.46±0.16	0.64±0.13	P<0.0001	0.61±0.32	0.88±0.18	P=0.001	1.02±0.47	1.38±0.46	P=0.002
L4	0.58±0.23	0.83±0.25	0.83±0.43	1.09±0.25	P=0.003	P=0.003	1.15±0.54	1.58±0.66	P=0.004
L6	1.2±0.34	1.22±0.11	P=0.763	1.05±0.47	1.67±0.96	P=0.001	1.34±0.34	1.79±0.63	P=0.001
La	3.66±1.45	3.42±0.57	P=0.407	3.74±1.05	4.33±0.22	P=0.002	2.3±1.56	4.44±0.06	P=0.001

B2*. 2mm apical to the buccal crestal bone L2**. 2mm apical to the palatal crestal bone

B4^δ. 4mm apical to the buccal crestal bone L4^{δδ}. 4mm apical to the palatal crestal bone

B6^ο. 6mm apical to the crest buccal L6^{οο}. 6mm apical to the palatal crestal bone

Ba^{zz} & La^{zz}. Root apex at buccal & lingual side of the alveolar bone

Table 3. Root apex position of the maxillary and mandible incisors in the alveolar bone

			B/M/L			Pvalue
			Buccal	Middle	Lingual	
Maxilla	Central	Female(n:29)	28(96.6)	1(3.4)	0	0.492
		Male (n:30)	30(100)	0	0	
		Total	58(98.3)	1(1.7)	0	
	Lateral	Female (n:24)	22(97.1)	2(8.3)	0	0.669
		Male (n:26)	21(80.8)	4(15.4)	1(3.8)	
		Total	43(86)	6(12)	1(2)	
Canine	Female (n:21)	21(100)	0	0	1.000	
	Male (n:27)	26(96.3)	1(3.7)	0		
	Total	47(97.9)	1(1.2)	0		
Mandibular	Central	Female (n:33)	9(27.3)	15(45.5)	9(27.3)	0.678
		Male (n:29)	9(31)	15(51)	5(17.2)	
		Total	18(29)	30(48.4)	14(22.6)	
	Lateral	Female (n:37)	11(29.7)	18(48.6)	8(21.6)	0.388
		Male (n:35)	16(45.7)	14(40)	5(14.3)	
		Total	27(37.5)	32(44.4)	13(18.1)	
	Canine	Female (n:37)	18(48.6)	16(43.2)	3(8.1)	0.936
		Male (n:32)	17(53.1)	12(37.5)	3(9.4)	
		Total	35(50.7)	28(40.6)	6(8.7)	

In addition, positioning the angle of roots in the alveolar bone indicated that the roots of the maxillary incisors and canines were positioned close to the buccal cortical plate, while this angle was smaller in mandibular incisors.

The root deviation of the maxillary and mandibular incisors and canines compared to the longitudinal axis of the alveolar bone, except for the maxillary lateral incisors, was greater in males than females (Table 4).

Table 4. Angle between the long axis of maxillary and mandibular incisors and the alveolar bone

		Angle mean ±SD	Pvalue
Maxilla	Central		
	Female (n:29)	14.71±4.96	0.428
	Male (n:30)	15.79±5.45	
	Lateral		
	Female (n:24)	12.23±6.12	0.636
	Male (n:26)	11.52±4.35	
	Canine		
	Female (n:21)	12.84±4.54	0.208
	Male (n:27)	14.57±4.72	
Mandible	Central		
	Female (n:33)	5.25±4.64	0.272
	Male (n:29)	6.73±5.85	
	Lateral		
	Female (n:37)	3.95±2.59	*0.006
	Male (n:35)	7.25±6.25	
	Canine		
	Female (n:37)	6.97±4.03	0.702
	Male (n:32)	7.44±5.82	

Discussion

Evaluation of the maxillary incisors and canines in the current study suggested that the thinnest buccal bone wall was in B4 (4mm apical to the Buccal crestal bone) in females and B6 (6mm apical to the crest buccal) in males. The thickness of alveolar bone walls was larger in males than females, which is consistent with that of Hamsah Sheerah et al. [2] In addition, there was no significant difference between males and females in the palatal cortical bone thickness of the maxillary central incisors, but in lateral incisors of maxilla, the thickness of palatal cortical plate was significantly higher in females than males. Studies were mostly performed on the buccal cortical bone thickness and no study so far was conducted on the thickness of palatal cortical bone.

In the present study, the root position of the maxillary incisors, one case was lingual and the rest were predominantly buccal, similar to the results of previous studies [1, 8-13]; however, due to the scatter of studies on this topic, the root position of maxillary incisors is the same in human beings regardless of race and population. Regarding the root position of canines in females, all the studied cases were buccal; it was also buccal in males except in one case that was middle. Regarding the angle between the longitudinal axes of anterior teeth and alveolar bone, the roots of maxillary anterior teeth were close to the buccal cortical plate with

greater positioning of the root apex to the cortical buccal wall.

In the present study, the longitudinal axis of mandibular incisors and canines was less deviated from the longitudinal axis of the alveolar bone compared to the maxillary incisors and canines, but the thickness of buccal bone in mandibular central incisors increased from the crest region toward the apex. Likewise, the thickness of buccal cortical bone in central incisors was greater in males than females. In the study by Lopez et al., the angle between the longitudinal axes of incisors and alveolar bone was smaller in mandible, which confirms the results of the ongoing study. [6]

Conclusion

Due to the small thickness of buccal bone, evaluation of the position of implant fixtures in maxillary anterior teeth is of great importance.

Funding: This study was a part of research project (Grant No: 9706571), supported and funded by Babol University of Medical Sciences.

Conflict of interest: The authors declare that they have no conflict of interest.

Author's Contribution

The study was designed by Sina Haghanifar and Naghmeh Nasrollahi. Sina Haghanifar and Naghmeh Nasrollahi defined the conceptual content of the research. The study data were collected by Naghmeh Nasrollahi. Statistical analysis and interpretation of data were accomplished by Ali Bijani. Preparation of manuscript was performed by Naghmeh Nasrollahi. Study supervision was performed by Sina Haghanifar.

References

- Jung YH, Cho BH, Hwang JJ. Analysis of the root position of the maxillary incisors in the alveolar bone using cone beam computed tomography. *Imaging Sci Dent* 2017;47:181-87.
- Sheerah H, Othman B, Jaafar A, Alsharif A. Alveolar bone plate measurements of maxillary anterior teeth : A retrospective Cone Beam Computed Tomography study , Almadinah, Saudi Arabia. *Saudi Dent J* 2019;31:437-44.
- Fuentes R, Flores T, Navarro P, Salamanca C, Beltrán V, Borie E. Assessment of buccal bone thickness of aesthetic maxillary region: a cone beam computed tomography study. *J Periodontal Implant Sci* 2015; 45:162-65.
- Zhang W, Skrypczak A, Weltman R. Anterior maxilla alveolar ridge dimension and morphology measurement by cone beam computed tomography for immediate implant treatment planning. *BMC Oral Health* 2015;15:65.
- Han JY, Jung GU. Labial and lingual/palatal bone thickness of maxillary and mandibular anteriors in human cadavers in Koreans. *J Periodontal Implant Sci* 2011;41:60-6.
- López-Jarana P, Díaz-Castro CM, Falcão A, Falcão C, Ríos-Santos JV, Herrero-Climent M. Thickness of the buccal bone wall and root angulation in the maxilla and mandible: an approach to cone beam computed tomography. *BMC Oral Health* 2018;18:194.
- Yu Q, Pan XG, Ji GP, Shen G. The association between lower incisal inclination and morphology of the supporting alveolar bone--a cone-beam CT study. *Int J Oral Sci* 2009; 1:217-23.
- Lau SL, Chow J, Li W, Chow LK. Classification of maxillary central incisors-implications for immediate implant in the esthetic zone. *J Oral Maxillofac Surg* 2011; 69: 142-53.
- Braut V, Bornstein MM, Belser U, Buser D. Thickness of the anterior maxillary facial bone wall--a retrospective radiographic study using cone beam computed tomography. *Int J Periodontics Restorative Dent* 2011; 31: 125-31.
- Kan JY, Roe P, Rungcharassaeng K, Patel RD, Waki T, Lozada JL, et al. Classification of sagittal root position in relation to the anterior maxillary osseous housing for immediate implant placement: a cone beam computed tomography study. *Int J Oral Maxillofac Implants* 2011; 26: 873-6.
- Xu D, Wang Z, Sun L, Lin Z, Wan L, Li Y, et al. Classification of the Root Position of the Maxillary Central Incisors and its Clinical Significance in Immediate Implant Placement. *Implant Dent* 2016; 25: 520-4.
- Chung SH, Park YS, Chung SH, Shon WJ. Determination of implant position for immediate implant placement in maxillary central incisors using palatal soft tissue landmarks. *Int J Oral Maxillofac Implants* 2014; 29: 627-33.
- Vera C, De Kok IJ, Reinhold D, Limpiphitanakorn P, Yap AK, Tyndall D, et al. Evaluation of buccal alveolar bone dimension of maxillary anterior and premolar teeth: a cone beam computed tomography investigation. *Int J Oral Maxillofac Implants* 2012; 27: 1514-9.