

## Cone-beam computed tomography performance and endodontic filling material influence in the diagnosis of horizontal root fracture

Naeime Rayiat <sup>1</sup>, Zahra Sadat Madani <sup>2✉</sup>, Ehsan Moudi <sup>3</sup>, Ali Bijani <sup>4</sup>

1. Assistant Professor , Dental Materials Research Center, Health Research Institute, Babol University of Medical Sciences, Babol, IR Iran. **ORCID** (0000-0001-6582-755X )
2. Associate Professor, Dental Materials Research Center, Health Research Institute, Babol University of Medical Sciences, Babol, IR Iran.
3. Associate Professor, Oral Health Research Center, Health Research Institute, Babol University of Medical Sciences, Babol, IR Iran.
4. Assistant Professor, Social Determinants of Health Research Center, Health Research Institute, Babol University of Medical Sciences, Babol, IR Iran.

**✉Corresponding Author:** ZahraSadat Madani, Department of Endodontics, Faculty of Dentistry, Babol University of Medical Sciences, Babol, IR Iran.

**Email:** madani\_z@yahoo.com

**Tel:** +981132291408

**ORCID** (0000-0001-8738-1413)

**Received:** 23 Nov 2019

**Accepted:** 9 Feb 2020

### Abstract

**Introduction:** The aim of this study was to investigate the accuracy of Cone-beam computed tomography(CBCT) in detecting the horizontal root fractures (HRFs) in teeth with and without gutta-percha.

**Materials & Methods:** This in vitro study was performed on 100 mandibular and maxillary single-rooted teeth. In 55 samples, the canals were prepared. Then, the horizontal fracture was induced randomly in 56 (29 with gutta-percha, 27 without gutta-percha) samples. The samples were mounted on a wax rim, and the CBCT scan was provided. The scans were examined by two endodontists twice with two-week interval. Data were analyzed using IBM SPSS 20.0 software (IBM Corp., Armonk, IL, USA). Sensitivity, specificity, accuracy, positive predictive value (PPV), negative predictive value (NPV), likelihood ratio (LR +, LR -) with 95% confidence interval were calculated.

**Results:** The sensitivity and specificity were 72% and 100% for the group with gutta-percha as well as 89% and 100% for the group without gutta-percha, respectively. The coefficient of agreement for each observer within two observations was  $0.940 \pm 0.034$  and  $0.960 \pm 0.028$  ( $P < 0.001$ ). The inter observer agreement was  $0.092 \pm 0.039$  ( $P < 0.001$ ).

**Conclusion:** The CBCT scans have high accuracy in diagnosis of horizontal root fracture and gutta-percha although they reduce the diagnostic accuracy with no significant effect.

**Keywords:** Cone-beam computed tomography, Gutta-percha, Sensitivity and specificity

**Citation for article:** Rayiat N, Madani ZS, Moudi E, Bijani A. Cone-beam computed tomography performance and endodontic filling material influence in the diagnosis of horizontal root fracture. Caspian J Dent Res 2020; 9:17-22.

## کار آیی توموگرافی کامپیوتری با اشعه مخروطی و تاثیر مواد پرکردگی ریشه در تشخیص شکستگی افقی ریشه

نعیمه رعیت<sup>۱</sup>، زهراسادات مدنی<sup>۲\*</sup>، احسان موعودی<sup>۳</sup>، علی بیژنی<sup>۴</sup>

۱. استادیار، مرکز تحقیقات مواد دندان، پژوهشکده سلامت، دانشگاه علوم پزشکی بابل، بابل، ایران.

۲. دانشیار، مرکز تحقیقات مواد دندان، پژوهشکده سلامت، دانشگاه علوم پزشکی بابل، بابل، ایران.

۳. دانشیار، مرکز تحقیقات سلامت و بهداشت دهان، پژوهشکده سلامت، دانشگاه علوم پزشکی بابل، بابل، ایران.

۴. استادیار، مرکز تحقیقات عوامل اجتماعی موثر بر سلامت، پژوهشکده سلامت، دانشگاه علوم پزشکی بابل، بابل، ایران.

\*نویسنده مسئول: زهراسادات مدنی، گروه اندودنتیکس، دانشکده دندانپزشکی، دانشگاه علوم پزشکی بابل، بابل، ایران.

پست الکترونیکی: [madani\\_z@yahoo.com](mailto:madani_z@yahoo.com) تلفن: +۹۸۱۱۳۲۹۱۴۰۸

### چکیده

**مقدمه:** هدف این مطالعه بررسی دقت CBCT در شناسایی شکستگی های افقی ریشه در دندانهای با و بدون گوتاپرکا می باشد.

**مواد و روش ها:** این مطالعه آزمایشگاهی بر روی ۱۰۰ دندان تک ریشه فک بالا و فک پایین انجام شد. در ۵۵ نمونه، کانال ها آماده سازی شدند. سپس شکستگی افقی ریشه بصورت تصادفی در ۵۶ نمونه (۲۹ نمونه با گوتاپرکا و ۲۷ نمونه بدون گوتاپرکا) ایجاد شد. نمونه ها بر روی ریم مومی مانت شدند و اسکن CBCT تهیه شد. اسکن ها بوسیله دو متخصص درمان ریشه، دو مرتبه و با فاصله دو هفته بررسی شدند. اطلاعات بوسیله نرم افزار IBM SPSS 20.0 (IBM Corp., Armonk, IL, USA) آنالیز شد. حساسیت، ویژگی، دقت، ارزش اخباری مثبت (PPV)، ارزش اخباری منفی (NPP)، Likelihood ratio (LR+، LR-) با ضریب اطمینان ۹۵٪ محاسبه شد.

**یافته ها:** حساسیت و ویژگی برای گروه با گوتاپرکا به ترتیب ۷۲٪ و ۱۰۰٪ بود همچنین برای گروه بدون گوتاپرکا ۸۹٪ و ۱۰۰٪ بود. ضریب توافق برای هر مشاهده گر در دو مرتبه مشاهده ۰/۹۴±۰/۰۳۴ و ۰/۹۶±۰/۰۲۸ بود (P<0.001). توافق بین دو مشاهده گر ۰/۹۲±۰/۰۳۹ بود (P<0.001).

**نتیجه گیری:** اسکن های CBCT دقت بالایی در شناسایی شکستگی افقی ریشه دارند و اگرچه گوتاپرکا دقت تشخیصی را می کاهد ولی تاثیر معناداری بر آن ندارد.

**واژگان کلیدی:** توموگرافی کامپیوتری با اشعه مخروطی، گوتاپرکا، حساسیت و ویژگی

### Introduction

Diagnosis of horizontal root fracture is based on clinical findings and radiographic examination. Detection of horizontal root fracture with intraoral radiography often requires multiple radiographs with different vertical angles, and detection is difficult due to their two-dimensional nature and superimposition of adjacent structures.<sup>[1]</sup> On the other hand, the horizontal root fracture mostly is oblique and extended from buccal to palatal. As a result, the fractures seen in periapical radiography in the middle-third may reach coronal-third on the palatal side. Since the coronal-third fractures have the poorest prognosis, so the loss of this diagnostic information will lead to inappropriate treatment plans and adverse consequences.<sup>[2]</sup> The horizontal root fracture can lead to the canal


calcification, necrosis of coronal segment and rarely apical segment. Even root fractures with minimal damage such as hairline fractures can also result in tooth necrosis.<sup>[3]</sup> For the treatment plan is different, according to the fracture line location and direction, from no treatment and follow up periodically in cases of apical-third fracture to coronal segment removal and orthodontic or surgical treatments on the apical segment in cases of the coronal-third fracture, the correct detection will be very important in the management of the tooth.<sup>[3]</sup> Therefore, the use of three-dimensional (3D) imaging can be helpful in overcoming the limitations of two-dimensional (2D) radiographs. The cone-beam computed tomography (CBCT) is a 3D imaging method that provides clear information. A factor affecting the

diagnostic quality of CBCT is the presence of radiopaque objects including gutta-percha, causing a reduction in the diagnostic accuracy through artifacts that can mimic the root fracture view or prevent the observation of the fracture lines.<sup>[4,5]</sup> Hence, the aims of this study were to investigate the accuracy of CBCT in detecting horizontal root fractures and to assess the influence of root canal filling on the visibility of a root fracture.

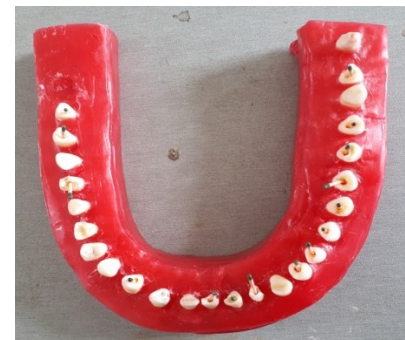### Materials & Methods

This study was supported by a grant from Babol University of Medical Sciences and approved by Ethical Committee of Babol University of Medical Sciences (Ethical number: mubabol.rec.1396.23). Totally, 100 anterior single rooted extracted human teeth without any fractures, root resorption or any other anomalies were collected, disinfected and cleaned from soft tissue in a solution of sodium hypochlorite 5.25% for one hour, and finally kept in normal saline until testing. The teeth had not been subjected to any endodontic treatment, and the absence of any fracture was assessed visually. These 100 teeth were divided into two groups : 45 samples were stayed without any preparation, and in 55 samples, access cavities were prepared and the root canals preparation were done with ProTaper rotary system (Dentsply-Maillefer, Tulsa, OK, USA) up to size F3. A 4% tapered gutta-percha (DiaDent, Incheon, Korea) with appropriate fit was selected for each prepared teeth.

**Horizontal root fracture induction:** To induce the horizontal fracture, the teeth were fixed inside the industrial clamp along the longitudinal axis, and then hit by a hammer in the direction of perpendicular to the longitudinal axis of the tooth (figure 1). The teeth sectioned into more than two slices or chipped at the borders were excluded from the study, and were replaced based on the inclusion criteria. The broken slices were placed together carefully without displacement and fixed with a cyanoacrylate adhesive. In general, the fracture was created randomly in 56 samples from 100 (29 prepared teeth, 27 not prepared). In the prepared group, when adhering two slices, a 4% tapered gutta-percha with appropriate fit and without sealer was placed inside the canal. The specimens were coded by the person who was responsible for inducing the teeth fracture and had no role in the observations, and then mounted randomly in the U-shaped wax rim with a diameter and thickness of 2 cm (figure 2).

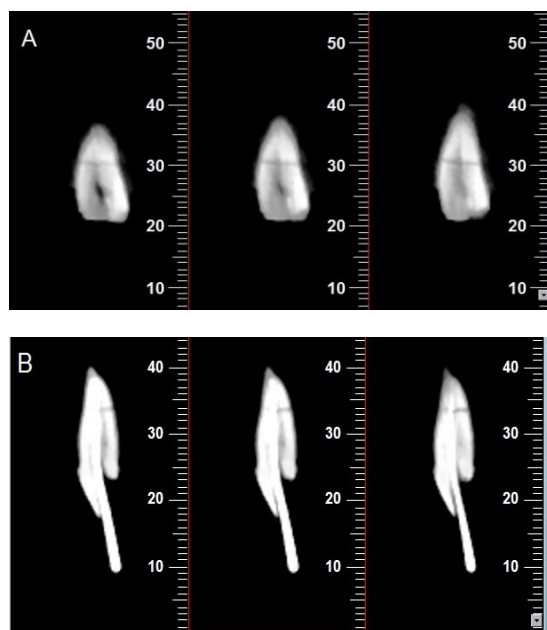


**Fig.1 A. The teeth were placed in industrial clamp. B. Broken tooth horizontally**



**Fig.2 mounting teeth in the U-shaped wax rim.**

**Radiographic examination:** The CBCT scans were obtained using denture scan mode of Newtom 5G System (QR srl, Verona, Italy) set at 110kv and a tube current of 3.46 mA and a mean time of 4.8 seconds with an FOV of 18x16 cm and a voxel size of 0.3 mm. The scans were examined in three planes of axial, coronal and sagittal in multi-planar reformation (MPR) by using NNT viewer software version 3.0 (QR srl, Verona, Italy). The slice thickness was 0.5 mm in this study. Scans were examined by two trained endodontists twice with two-week interval for the presence or absence of a horizontal root fracture (figure 3). The observation was done in a low-light room with the LG Flatron 18.5 inch monitor (LG, Seoul, Korea) and observers were free to choose magnification. In addition, the observers were unaware of how many samples had fracture.



**Fig.3 A. Coronal cross-sectional images and the fracture line in teeth without gutta-percha. B. Sagittal cross-sectional images and the fracture line in teeth with gutta-percha**

**Statistical analysis:** Data were analyzed by IBM SPSS 20.0 statistical software (IBM Corp., Armonk, IL, USA). Sensitivity, specificity, accuracy, positive predictive value (PPV), negative predictive value (NPV), likelihood ratio (LR+, LR-) with 95%

confidence interval were calculated for each observer in each observation based on more than two identical observations in all cases. The third person judged in cases where the positive and negative observations were the same.

The KAPPA coefficient was used to determine the agreement rate in each observation and to evaluate the intraobserver and interobserver agreement and  $P < 0.05$  was considered as significance level.

## Results

The results for the analysis of data obtained from each observer are reported in table 1. The KAPPA coefficient for each observation representing the extent of agreement with gold standard is also given in table 1. In this study, the specificity of both groups with and without gutta-percha was 100%. The sensitivity in the group with and without gutta-percha was 72% and 89%, respectively. The accuracy in the group without gutta-percha was greater than the group with gutta-percha, but not significant ( $P = 0.210$ ). The results for these two groups are presented in table 2. Kappa value for intraobserver agreement in twice reading for first and second observers was  $0.940 \pm 0.034$  and  $0.960 \pm 0.028$ , respectively ( $P < 0.001$ ). The coefficient of agreement between the two observers (interobserver agreement) was  $0.920 \pm 0.039$  ( $P < 0.001$ ).

**Table 1. Sensitivity, specificity, accuracy, positive predictive value (PPV), negative predictive value (NPV), and likelihood ratio (LR +, LR-) with 95% confidence interval for each turn by any observer**

Groups	Sensitivity	specificity	accuracy	positive predictive value	negative predictive value	LR +	LR -	kappa±SE	P-value
1 <sup>st</sup> observer, 1 <sup>st</sup> reading	86%(77-95)	100%(100-100)	92%(87-97)	100%(100-100)	85%(75-94)	∞	0.14(0.08-0.27)	0.841±0.053	<0.001
1 <sup>st</sup> observer, 2 <sup>nd</sup> reading	84%(74-94)	100%(100-100)	91%(85-97)	100%(100-100)	83%(73-93)	∞	0.16(0.09-0.29)	0.821±0.056	<0.001
2 <sup>nd</sup> observer, 1 <sup>st</sup> reading	82%(72-92)	100%(100-100)	88%(82-94)	100%(100-100)	81%(71-92)	∞	0.18(0.10-0.31)	0.802±0.058	<0.001
2 <sup>nd</sup> observer, 2 <sup>nd</sup> reading	79%(68-89)	100%(100-100)	90%(84-96)	100%(100-100)	79%(68-89)	∞	0.21(0.13-0.35)	0.763±0.062	<0.001
Observer *	80%(70-91)	100%(100-100)	89%(83-95)	100%(100-100)	80%(69-91)	∞	0.20(0.12-0.33)	0.783±0.060	<0.001

\* Diagnosis based on more than two observations



**Table 2. Sensitivity, specificity, accuracy, positive predictive value (PPV), negative predictive value (NPV), and likelihood ratio (LR +, LR-) with 95% confidence interval for two groups with and without gutta-percha**

Groups	Sensitivity	specificity	accuracy	positive predictive value	negative predictive value	LR +	LR -	kappa±SE	P-value
with gutta-percha	72%(56-89)	100%(100-100)	85%(76-95)	100%(100-100)	76%(62-91)	∞	0.28(0.15-0.50)	0.713±0.090	<0.001
without gutta-percha	89%(77-100)	100%(100-100)	93%(86-100)	100%(100-100)	86%(71-100)	∞	0.11(0.04-0.32)	0.865±0.075	<0.001

## Discussion

Our results showed that CBCT scans have high diagnostic accuracy in detecting the horizontal root fractures, and gutta-percha has little effect on it. The root fractures, especially those with no displacement, may be undetectable in conventional radiography.<sup>[5-7]</sup> The method for inducing horizontal fracture in this study was different from that in other studies. In previous studies, the teeth were placed on a soft foundation, and then broken by a hammer blow on the horizontal direction.<sup>[8-11]</sup> The high amount of crushing and loss of specimens in this method led us to use another method, resulting in fractures without crush and chipping in the borders. Additionally, only a single well-fitting gutta-percha and no sealer were used to prevent the possible penetration of the sealer into the fracture line. Despite the benefits of CBCT, this modality originally has scattered beam and noise due to the low energy spectrum, cone-beam geometry and artifacts. The beam-hardening phenomenon leads to two types of artifacts: 1. deformation of metal structures due to the differential absorption of beam leading to cupping artifacts. 2. streaks and dark bands that create the missing value artifact when present between two dense objects.<sup>[12-14]</sup> In the present study, the scans were performed in the large FOV, and the accuracy was high for both groups. This result is in contrast to that of Costa et al. in 2012.<sup>[15]</sup> Their results indicated a low level of accuracy in the use of large FOV.<sup>[15]</sup> Moreover, Salineiro et al. reported higher metal interaction in the large FOV along with small voxel size.<sup>[16]</sup> This finding can be due to the use of different devices in these studies, as some of them can produce more artifacts.<sup>[8]</sup>

In the present study, the presence of gutta-percha reduced the accuracy and sensitivity of CBCT images in HRF detection, but not significant. In the study of Costa et al., the presence of metal posts reduced the diagnostic accuracy of CBCT in the detection of HRF, which was statistically significant.<sup>[5]</sup> Costa et al. and Salineiro et al.

stated that the presence of metal posts decreased the sensitivity and specificity of small volume CBCT in detecting the HRFs<sup>[5,16]</sup> Reducing the sensitivity and negative predictive value in the teeth with gutta-percha in the current study could be attributed to the gutta-percha-induced artifact, leading to hiding the fracture line and failing to detect the fracture in some teeth. In the present study, the specificity was similar in both groups. Possible reason for the equalization of specificity and positive predictive value in different groups in this study was the absence of dark stripe artifact (in the form mimicking the fracture line). Besides, no sealer was applied in the ongoing study, while different sealers due to different densities can produce various strip artifacts, which may endanger the fracture detection in teeth containing root-filling materials.

In a study of Brito-junior et al., the amount of strip artifact created in the groups containing sealer and gutta-percha was greater than that of the gutta-percha alone.<sup>[17]</sup> The overall specificity in the present study was greater than that in the studies by Costa et al. and Salineiro et al.<sup>[5,16]</sup> which can be due to no use of soft and hard tissue analogues (human dried mandible and wax layers) that increase scattered beam.

In this in vitro study, the presence of soft and hard tissues in in vivo condition can influence on quality of CBCT scans. It is suggested that in further research, a smaller voxel size and field of view should be used to examine the diagnostic accuracy of CBCT in horizontal root fracture.

## Conclusion

According to the results of this in vitro study, the CBCT scans have high accuracy in diagnosis of horizontal root fracture and gutta-percha although they reduce the diagnostic accuracy with no significant effect..

**Funding:** This study was a part of research project (Grant No: 9644011), supported and funded by Babol University of Medical Sciences.

**Conflict of interest:** We declare no conflict of interest.

## Authors Contributions

The study was designed by ZahraSadat Madani. The study data was collected by Naeime Rayiat. Statistical analysis and interpretation of data were accomplished by Ali Bijani and Naeime Rayiat. Preparation of manuscript was performed by Naeime Rayiat and its editing and revision were done by ZahraSadat Madani and Ehsan Moudi.

## References

1. Hashemnia SM, Jahadi S, Shaygannia S, Hekmatian E, Habibollahi A, Ghazizadeh M. Cone beam computed tomography and digital periapical radiography in determining horizontal root fractures: An in-vitro comparative study. *Dentistry*. 2018; 8:1000513.
2. Patel S, Brown J, Pimentel T, Kelly RD, Abella F, Durack C. Cone beam computed tomography in Endodontics - a review of the literature. *Int Endod J* 2019;52:1138-52.
3. Malhotra N, Kundabala M, Acharaya S. A review of root fractures: diagnosis, treatment and prognosis. *Dent Update*. 2011;38:615-30.
4. Bechara B, Alex McMahan C, Moore WS, Noujeim M, Teixeira FB, Geha H. Cone beam CT scans with and without artefact reduction in root fracture detection of endodontically treated teeth. *Dentomaxillofac Radiol* 2013;42:20120245.
5. Costa FF, Gaia BF, Umetsubo OS, Cavalcanti MG. Detection of horizontal root fracture with small-volume cone-beam computed tomography in the presence and absence of intracanal metallic post. *J Endod* 2011;37:1456-9.
6. Bernardes RA, de Moraes IG, Húngaro Duarte MA, Azevedo BC, de Azevedo JR, Bramante CM. Use of cone-beam volumetric tomography in the diagnosis of root fractures. *Oral Surg Oral Med Oral Pathol Oral Radiol Endod* 2009;108:270-7.
7. Valizadeh S, Vasegh Z, Rezapana S, Safi Y, Khaezifard MJ. Effect of object position in cone beam computed tomography field of view for detection of root fractures in teeth with intra-canal posts. *Iran J Radiol* 2015 ; 12: e25272.
8. Avsever H, Gunduz K, Orhan K, Uzun I, Ozmen B, Egrioglu E, et al. Comparison of intraoral radiography and cone-beam computed tomography for the detection of horizontal root fractures: an in vitro study. *Clin Oral Investig* 2014;18:285-92.
9. Kamburoğlu K, Ilker Cebeci AR, Gröndahl HG. Effectiveness of limited cone-beam computed tomography in the detection of horizontal root fracture. *Dent Traumatol* 2009;25:256-61.
10. Fisekcioglu E, Dolekoglu S, Ilguy M, Ersan N, Ilguy D. In vitro detection of dental root fractures with cone beam computed tomography (CBCT). *Iran J Radiol* 2014;11:e11485.
11. Kamburoglu K, Onder B, Murat S, Avsever H, Yüksel S, Paksoy CS. Radiographic detection of artificially created horizontal root fracture using different cone beam CT units with small fields of view. *Dentomaxillofac Radiol* 2013;42:20120261.
12. Mallya SM, Lam EWN, editors. *White and Pharoah's Oral Radiology: Principles and Interpretation*. 8th ed. St. Louis, Missouri : Elsevier; [2019]. p. 415.
13. Nagarajappa AK, Dwivedi N1, Tiwari R. Artifacts: The downturn of CBCT image. *J Int Soc Prev Community Dent* 2015;5:440-5.
14. Syam S, Maheswari TN U. Artifacts in cone beam computed tomography – A retrospective study. *J Pharm Sci Res* 2019;11: 1914-7.
15. Costa FF, Gaia BF, Umetsubo OS, Pinheiro LR, Tortamano IP, Cavalcanti MG. Use of large-volume cone-beam computed tomography in identification and localization of horizontal root fracture in the presence and absence of intracanal metallic post. *J Endod* 2012;38:856-9.
16. Salineiro FC, Pinheiro LR, dos Santos Junior O, Cavalcanti MG. Detection of horizontal root fracture using four different protocols of cone-beam computed tomography. *Braz Oral Res* 2015;29:1-6.
17. Brito-Júnior M, Santos LA, Faria-e-Silva AL, Pereira RD, Sousa-Neto MD. Ex vivo evaluation of artifacts mimicking fracture lines on cone-beam computed tomography produced by different root canal sealers. *Int Endod J* 2014;47:26-31.