

## Evaluation of the morphometric variation of frontal sinus in cone-beam computed tomography (CBCT) of paranasal sinus

Kosar Shakeri<sup>1</sup>, Farida Abesi<sup>2✉</sup>, Sina Haghanifar<sup>3</sup>, Soraya Khafri<sup>4</sup>

1. Dental Student, Student Research Committee, Babol University of Medical Sciences, Babol, IR Iran. **ORCID** (0000-0002-4453-5635)
2. Associate Professor, Dental Materials Research Center, Health Research Institute, Babol University of Medical Sciences, Babol, IR Iran.
3. Professor, Oral Health Research Center, Health Research Institute, Babol University of Medical Sciences, Babol, IR Iran.
4. Assistant Professor, Dental Materials Research Center, Health Research Institute, Babol University of Medical Sciences, Babol, IR Iran.

**✉Corresponding Author:** Farida Abesi, Department of Oral & Maxillofacial Radiology, Faculty of Dentistry, Babol University of Medical Sciences, Babol, IR Iran.

**Email:** Faridaabesi@yahoo.com

**Tel:** +9891132291409

**ORCID** (0000-0002-6826-2782)

Received: 7 Jul 2019      Accepted: 16 Mar 2020

### Abstract

**Introduction:** The frontal sinus is the most variable part of the paranasal sinuses in terms of symmetry, anatomical features and degree of development. The aim of this study was to assess the morphometric changes of the frontal sinus in cone-beam computed tomography (CBCT) images.

**Materials & Methods:** In this cross-sectional study, 200 CBCT images were examined for anatomical variations such as the presence of frontal sinus, sinus symmetry, lateral frontal sinus extension (LFSE) to orbital roof, scalloping, septum and type of septum. Moreover, Crista Galli (CG) was divided into three equal segments of anterior, middle and posterior in order to have a precise criterion for determining the location of the frontal recess in coronal plane. The data were analyzed using ANOVA with T-test and Chi-square at significant level of  $P < 0.05$ .

**Results:** Of 200 cases, 113 and 87 ones were male and female with the mean age of 18–88 years. The results showed that frontal sinus was bilateral in all cases and symmetric in 113 (57%) cases. The LFSE to orbital roof had a significant relationship with gender, so that at the external one-third, the LFSE was less frequent in women than men ( $P < 0.001$ ). The most frequent location of the frontal recess was in the posterior one-third of CG (85 (43%)) with significant difference ( $P = 0.012$ ).

**Conclusion:** In this study, frontal sinuses were rather symmetric, and the use of the anatomical CG marker in multiplanar (MPR) images was not feasible method for rapid detection of the frontal recess location in coronal plane.

**Keywords:** Frontal sinus, Anatomic variations, Cone- beam computed tomography

**Citation for article:** Shakeri K, Abesi F, Haghanifar S, Khafri. Evaluation of the morphometric variation of frontal sinus in cone beam computed tomography (CBCT) of paranasal sinus. *Caspian J Dent Res* 2020; 9: 35-41.

## ارزیابی تغییرات مورفومتریک سینوس فرونتال در تصاویر توموگرافی کامپیوتری با اشعه مخروطی از سینوس پاراناژال

کوثرشاکری<sup>۱</sup>، فریدا عابسی<sup>۲\*</sup>، سینا حقانی فر<sup>۳</sup>، ثریا خفری<sup>۴</sup>

۱. دانشجوی دندانپزشکی، کمیته تحقیقات دانشجویی، دانشگاه علوم پزشکی بابل، بابل، ایران.
  ۲. دانشیار، مرکز تحقیقات مواد دندان، پژوهشکده سلامت، دانشگاه علوم پزشکی بابل، بابل، ایران.
  ۳. استاد، مرکز تحقیقات سلامت و بهداشت دهان، پژوهشکده سلامت، دانشگاه علوم پزشکی بابل، بابل، ایران.
  ۴. استادیار، مرکز تحقیقات مواد دندان، پژوهشکده سلامت، دانشگاه علوم پزشکی بابل، بابل، ایران.
- \*نویسنده مسئول: فریدا عابسی، گروه رادیولوژی دهان، فک و صورت، دانشکده دندانپزشکی، دانشگاه علوم پزشکی بابل، بابل، ایران.  
پست الکترونیکی: Faridaabesi@yahoo.com: تلفن: +۹۸۱۱۳۳۲۹۱۴۰۹

### چکیده

**مقدمه:** سینوس فرونتال تغییرپذیرترین بخش سینوس های پاراناژال از لحاظ تقارن، ویژگی های آناتومیک و درجه تکامل است. هدف از این مطالعه ارزیابی تغییرات مورفومتریک سینوس فرونتال در تصاویر توموگرافی کامپیوتری با اشعه مخروطی می باشد.

**مواد و روش ها:** در این مطالعه مقطعی، تعداد ۲۰۰ تصویر CBCT از نظر تغییرات آناتومیک مانند وجود سینوس فرونتال، تقارن سینوس، گسترش لترالی سینوس نسبت به سقف استخوان اوربیت، کنگره دار بودن، وجود سپتوم و نوع آن مورد بررسی قرار گرفتند. همچنین به منظور داشتن یک معیار دقیق برای تعیین مکان رسس فرونتال در پلن کروئال، ما کریستالوگرافی را به سه قسمت مساوی قدیمی، میانی و خلفی تقسیم کردیم و رابطه بین آنها از نظر تست های آماری t-test و Chi-square test و ANOVA مورد بررسی قرار گرفت و  $P\_value < 0.05$  معنادار تلقی شد.

**یافته ها:** از ۲۰۰ مورد ۱۱۳ نفر مرد و ۸۷ نفر زن، با میانگین سنی ۱۸-۸۸ سال بودند. نتایج نشان داد که در همه ی موارد سینوس فرونتال دو طرفه و ۱۱۳ مورد (۵۷٪) از موارد متقارن هستند. گسترش لترالی سینوس فرونتال نسبت به سقف اوربیت با جنسیت رابطه معناداری داشت بطوریکه در یک سوم خارجی، فراوانی کمتری در زنان نسبت به مردان مشاهده شد ( $P < 0.001$ ). شایعترین محل رسس فرونتال در یک سوم خلفی کریستالوگرافی (۸۵ مورد ۴۳٪) با اختلاف معناداری بود ( $P = 0.012$ ).

**نتیجه گیری:** در این مطالعه، سینوس های فرونتال نسبتاً متقارن بودند و استفاده از نشانگر آناتومیک کریستالوگرافی در تصاویر چند بعدی، یک روش عملی برای تشخیص سریع محل فرونتال رسس در پلن کروئال نبود.

**واژگان کلیدی:** سینوس فرونتال، تنوعات آناتومیک، توموگرافی کامپیوتری با اشعه مخروطی

### Introduction

The paranasal sinuses develop from the nasal cavity as invaginations extending into the maxillary, ethmoid, sphenoid and frontal bones. The frontal sinus begins to develop from 5-6 years old and fully develops at age 18. This sinus is formed by the expansion of the nasal cavity or by the anterior ethmoid cells. [1] The frontal sinus is the most variable of all the paranasal sinuses in terms of symmetry, anatomical features and degree of development. [2] Frontal recess has an approximate shape of an inverted cone or funnel with the apex at the frontal ostium [3, 4] and is a pathway for the frontal sinus drainage into the middle meatus of the nose. [1] Some of the anatomic variations of the frontal sinus including the presence of: unilateral or bilateral

frontal sinus, frontal sinus symmetry on both sides, lateral frontal sinus extension (LFSE) to orbital roof on both sides based on internal, middle and external one-third of orbit, scalloping on the left and right sinuses, septum inside the sinuses and complete or incomplete septa were examined in the present study. The frontal recess is very crucial and probably effective in sinus occlusion and sinus mucosal diseases. Some of the pathologies of the frontal sinus and frontal recess usually require surgery. Surgery on the frontal sinus and frontal recess is a challenge for sinus surgeons. In the past, they disagreed on frontal sinus and frontal recess surgeries because it was thought that these surgical incisions might result in scars and closure of the frontal sinus opening. However, several studies have shown that the sinus surgery can be carried out successfully if

the surgeon has a clear understanding of cell structures, drainage paths and anatomy of the frontal sinus and frontal recess. A clear understanding of the anatomy of structures can be achieved through observing CT images in all three planes and reconstructing the 3-D cone-beam computed tomography (CBCT) images. [4,5]

Since finding the location of the frontal recess on CBCT images is just as difficult as finding the ostium; therefore, the aim of this study was to use a clear anatomic landmark in order to quickly detect the frontal recess on multiplanar (MPR) images (to our best knowledge, no study has been conducted so far) and also to assess the anatomic variations of the frontal sinus on CBCT images.

## Materials & Methods

This study was approved by the Ethics Committee of Babol University of Medical Sciences, Babol, Iran (with the code of MUBABOL.REC.1396.2). In this cross-sectional study, 200 retrospective CBCT images taken by CBCT Giano unit (Newtom, Verona, Italy) with a field view of 11×13 cm were studied. The CBCT images belonged to patients due to different reasons, referred to the Babol Oral and Maxillofacial Radiology Clinic in Iran. All 18-88-year-old patients had visible frontal sinuses bilaterally on the CBCT images. In addition, patients with trauma, surgery or developmental anomalies were excluded from the current study.

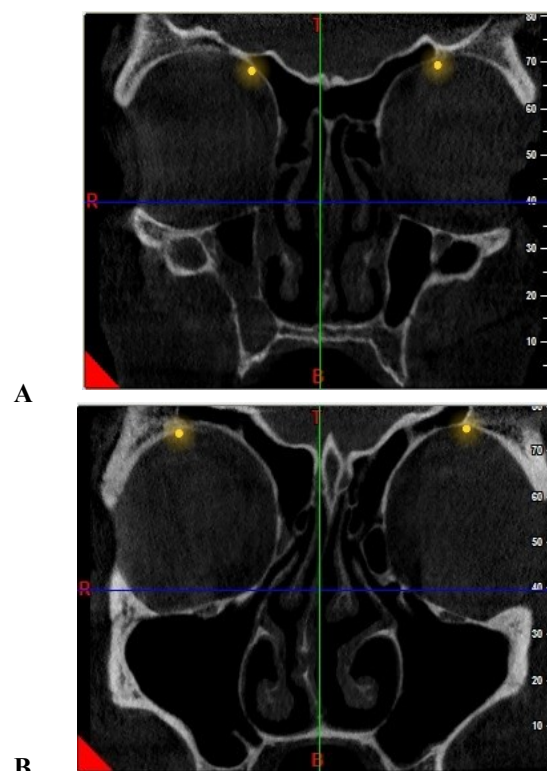
Some of the anatomic variations of the frontal sinus including the presence of: unilateral or bilateral frontal sinus, frontal sinus symmetry on both sides, lateral frontal sinus extension (LFSE) to orbital roof on both sides based on internal, middle and external one-third of orbit, scalloping on the left and right sinuses, septum inside the sinuses and complete or incomplete septa were examined in the ongoing study. The location of the frontal recess on coronal plane, relative to Crista Galli (CG) on axial plane in MPR images was categorized into the frontal, middle or posterior one-third of the CG. To investigate the symmetry of the frontal sinuses, the CBCT images were examined in the coronal dimension at the point where the orbital bone roof was fully visible. In the present study, the orbital bone roof was divided into internal, middle, and external segments as well as the sinus symmetry was diagnosed based on the LFSE on both sides in the same third.

The CBCT images were monitored using a personalized Dell inspiron N5110 monitor with a TFT LED-backlit LCD screen and FULL HD 1366x768

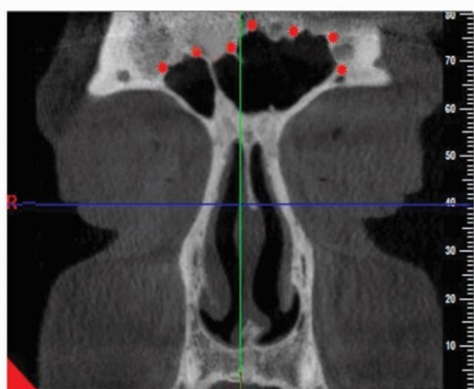
resolution. Next, two maxillofacial radiologists checked the images simultaneously, and finally made a single comment. Data were analyzed through descriptive statistics, t-test and chi-square at the significant level of  $p < 0.005$ .

## Results

Totally, 200 CBCT images taken from 113 (57 %) males and 87 (43%) females with the age of 18–88 years as well as with the mean and standard deviation of  $35.9 \pm 15.14$  years were analyzed in this cross-sectional study. The results showed that there was no unilateral sinus on the evaluated images, and the 113 (57%) and 87 (43%) frontal sinuses were symmetrical and asymmetrical, respectively (Figure 1). The most frequent LFSE to orbital roof was observed in 118 (59%) cases. A total of 176 (88%) cases had a scalloped border (Figure 2).



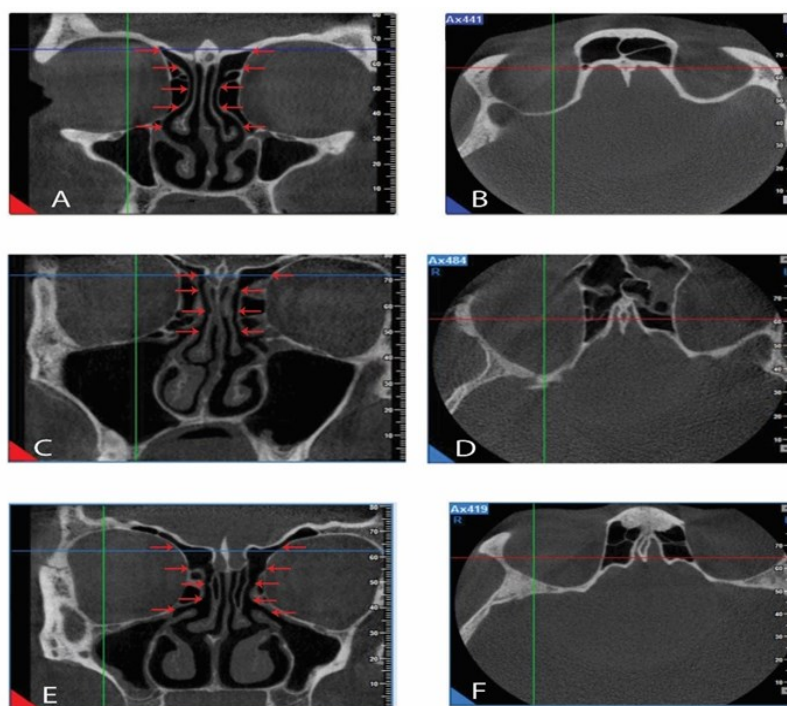
**Figure 1.** Images of the symmetrical (A) and asymmetrical (B) sinuses



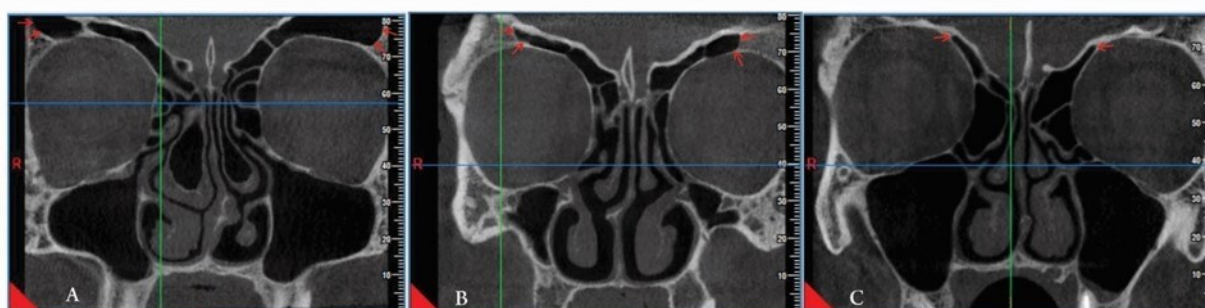
**Figure 2.** A coronal CBCT cross-section, showing the scalloped border of the frontal sinus

A total of 183 (92%) cases had a central septum between the left and right sinuses with significant difference ( $P < 0.001$ ). Of all these, the majority (158, 79%) had complete septa, which was significant statistically ( $P < 0.001$ ). In addition, the posterior one-third of CG was the most frequent location of the frontal recess in 85 (43%) cases with significant difference ( $P = 0.012$ ) (Figure 3).

As shown in table 1, the LFSE to orbital roof is not distributed homogeneously in both genders, so that at the external one-third, the LFSE is less frequent in women than men ( $P < 0.001$ ). On the other hand, it was more frequent in females compared to males at the internal one-third (Figure 4).



**Figure 3.** The coronal section of CBCT images (A-C-E), indicating the frontal recess position (red arrows) relative to the position of CG in the axial section at the anterior, middle and posterior one-third of CG (red lines) (F-B-D)



**Figure 4.** A coronal CBCT cross-section, representing the LFSE to orbital roof at internal, middle and external one-third



**Table 1. Relationships between the studied variables and gender in the frontal sinus**

Variables		Total	sex		P-value <sup>a</sup>
			Males	Females	
Presence of frontal sinus	Unilateral	0	0	0	-
	Bilateral	200 (100)	87 (100)	113 (100)	
Sinus symmetry	Symmetrical	113 (57)	49 (56)	64 (58)	0.740
	Asymmetrical	87 (43)	38 (44)	49 (42)	
Lateral frontal sinus extension to orbital roof	Internal one-third	118 (59)*	41 (47)	77 (68)	<0.001*
	Middle one-third	69 (35)	36 (42)	33 (29)	
	External one-third	13 (6)	10 (11)	3 (3)	
Frontal recess position to Crista Galli	Posterior one-third	85 (43)*	41 (47)	44 (42)	0.536
	Middle one-third	64 (32)	27 (31)	37 (31)	
	Anterior one-third	51 (25)	19 (22)	32 (31)	
Presence of scalloping	No	24 (12)	10 (12)	14 (11)	<0.001*
	Yes	176 (88)*	77 (88)	99 (89)	
Presence of septum	NO	17 (8)	6 (7)	11 (8)	<0.001*
	Yes	183 (92)*	81 (93)	102 (92)	
Type of septum	No	17 (8)	6 (6)	11 (8)	<0.001*
	Complete	158 (79)*	68 (79)	90 (82)	
	Partial	25 (13)	13 (15)	12 (10)	

\*Statistically significant at  $\alpha=0.05$ 

a: The results of chi-square test \*\* Values in the table are numbers (%).

The relationship between the mean age with the sinus symmetry, the presence of scalloping and septum and the type of septum were studied (Table 2). There was no significant relationship between the studied variables and age.

**Table 2. The relationship between the mean age and studied variables**

Variables		Mean $\pm$ SD	P-value
Frontal sinus symmetry	Symmetrical	34.80 $\pm$ 13.97	0.229 <sup>a</sup>
	Asymmetrical	37.40 $\pm$ 16.51	
Presence of scalloping	No	35.28 $\pm$ 14.84	0.103 <sup>a</sup>
	Yes	40.67 $\pm$ 16.77	
Presence of septum	No	35.92 $\pm$ 15.03	0.984 <sup>a</sup>
	Yes	36 $\pm$ 16.78	
Lateral frontal sinus extension to orbital roof	Internal one-third	36.92 $\pm$ 16.09	0.377 <sup>b</sup>
	Middle one-third	35.12 $\pm$ 14.24	
	External one-third	31.23 $\pm$ 9.58	
Type of septum	Full	36.18 $\pm$ 15.14	0.567 <sup>b</sup>
	Partial	34.32 $\pm$ 14.49	
	No	35.93 $\pm$ 15.15	

 $\alpha$ : The result of the independent t-test at  $\alpha=0.05$ .b: The results of ANOVA at  $\alpha=0.05$ .

## Discussion

Like the study of Soares et al., the frontal sinuses were bilateral in 100% of cases, and there was no aplasia of the sinus. However, some other studies reported that the rates of bilateral congenital aplasia of the sinus were 10%, 14%, 4% and 1% in Northern Ireland, United Estate of America, Turkey and Iraq, respectively. It seems that the prevalence of aplasia in

the frontal sinus is variable in different areas. [6] One study has expressed that the frontal sinus is the most symmetrical sinus, [1] while another one has stated the opposite. [7] Nevertheless, in the present study, the frontal sinus was symmetrical in 57% of the cases. Frontal sinus has different sizes and its pneumatization might include the vertical plate of frontal bone

(squamous part), horizontal plate of frontal bone (orbital roof) or both. The diagnosis of the extension of frontal sinus into the orbital recess is very crucial in frontal sinus occlusion as well as in external endoscopic and frontal sinus surgeries.<sup>[8]</sup> Any failure in diagnosis of orbital recess before surgery leads to the removal of only the vertical part of the sinus, finally giving rise to a mucocele in the occluded orbital recess.<sup>[6]</sup>

In the ongoing study, the LFSE to orbital roof was studied in order to better understand these areas and sinus symmetry. The results suggested that the sinus extension in the internal one-third of orbit roof was found in 59% of cases, which was significantly higher than that in the middle and external one-third.

Moreover, the LEFS to orbital roof was not distributed homogeneously in two genders, so that at the external one-third, the LFSE is less frequent in women than men ( $P < 0.001$ ). On the other hand, it was more frequent in females compared to males at the internal one-third. To our best knowledge, no similar study has been conducted so far. The border of frontal sinus is usually scalloped.<sup>[7]</sup> In a study by Soares et al., the frequency of scalloping in the left and right sinuses was 91.3% and 92%, respectively.<sup>[6]</sup> In the present study, 88% of cases exhibited scalloped sinus border, which is consistent with other studies.

In fact, the remaining frontal bone between the two frontal sinuses is known as the intersinus septum which is usually in the midline at its base or lower portion; nevertheless, relying on the differential growth rates of the frontal sinuses, it may then deviate far to one side. Although the septum is always complete, the acquired or congenital recess might develop at the central region, resulting in bilateral connection of frontal sinuses.<sup>[6]</sup>

Besides, in the present study, 92% of cases exhibited the central septum, which was significant. In addition, the types of central septum were analyzed, and the results indicated that the frequency of complete septum between the left and right sinuses (79%) was significantly higher than that of the partial septum (23%) and absence of septum (8%). Asmaa et al. studied on the septum in the left and right sinuses separately and concluded that 48.8% of cases had no septum in left sinus, 45 and 6.3% of cases had one septum and two septa in the left sinus, respectively. Incomplete and complete septa were found in 80 and 20% of cases in the right sinus and in 87.7 and 12.2% of cases in the left sinus, respectively.<sup>[2]</sup> In a study, the

term “bifurcated sinus” was used when there was a complete septum in the left or right sinus.<sup>[9]</sup>

The frontal recess as an hourglass-like structure is situated between the frontal sinus and middle meatus (into which the sinus is discharged).<sup>[4, 6]</sup> Frontal recess is the narrowest frontal air channel and possible site for infection. Thus, its occlusion decreases ventilation and clearing of mucous cilia in the frontal sinus.<sup>[6]</sup> If there is a significant relationship between the cursor position in the anterior, middle and posterior of CG in axial plane and frontal recess position in coronal plane, the CG position in axial plane will be used as a guide to find frontal recess in coronal plane in MPR images. Since, in the present study, this relationship was not significant, it was impossible to use this landmark for locating the frontal recess.<sup>[10]</sup>

This method must be used in other populations with larger sample sizes to prove the efficacy of the technique with a higher level of confidence. Previously, the frontal sinus surgeries were performed using 2-D radiographic techniques. However, with the advent of CT and CBCT techniques, there is an opportunity to provide 3-D images from the position of the frontal sinus and frontal recess. Although 2- and 3-D images were helpful in treatment planning, the exact information about the real position of the sinus and frontal recess's path became accessible to surgeons only with the use of CT and CBCT images.<sup>[11-15]</sup>

Due to the low cost and low-dose scanning in the initial assessments of the frontal sinus, the CBCT images are preferred to CT images.<sup>[1, 16, 17]</sup> Advanced CBCT softwares make it easier to diagnose the anatomic variations of frontal sinus and frontal recess's path, decreasing the complexities during the surgery.

## Conclusion

Due to the high incidence of anatomical variations in the frontal sinus and frontal recess, the CBCT images owing to high resolution compared to other 3-D modalities seem appropriate for pre-treatment evaluation. Using the anatomic landmark such as CG in MPR images for quick assessment of frontal recess is not a practical method; therefore, further studies on other populations with larger sample sizes are needed to show the efficacy of this technique with higher reliability.

## Acknowledgments

The authors wish to thank sincere cooperation of Social Determinants on Dental Materials Research Center, Babol University of Medical Sciences.

**Funding:** This study was a part of research project (Grant no: 9643819), supported and funded by Babol University of Medical Sciences. There is no conflict of interests.

**Conflict of interest disclosure:** The authors state that they have no conflict of interest.

## Authors' Contributions

The study was designed by Farida Abesi and Sina Haghanifar. The study data were collected by Kosar Shakeri. Analysis and interpretation of data drafting of the manuscript, and critical revision of the manuscript for important intellectual content were performed by Soraya Khafri, Farida Abesi Sina Haghanifar. Study supervision was conducted by Farida Abesi and Sina Haghanifar.

## References

- White SC, Pharoah MJ, editors. Oral radiology : principles and interpretation. 7<sup>th</sup> ed. St. Louis, Missouri : Elsevier; [2014].p.541-61.
- Asmaa T.Uthman AT, Al-Rawi NH, Al-Naaimi AS, Tawfeeq AS, Suhail EH. Evaluation of frontal sinus and skull measurements using spiral CT scanning: an aid in unknown person identification. *Forensic Sci Int* 2010; 197: 124.
- Lee WT, Kuhn FA, Citardi MJ. 3D computed tomographic analysis of frontal recess anatomy in patients without frontal sinusitis. *Otolaryngol Head Neck Surg* 2004; 131: 164-73.
- Kubota K, Takeno S, Hirakawa K. Frontal recess anatomy in Japanese subjects and its effect on the development of frontal sinusitis: computed tomography analysis. *J Otolaryngol Head Neck Surg* 2015;44:21.
- Wormald P J. Three-dimensional building block approach to understanding the anatomy of the frontal recess and frontal sinus. *Oper Tech Otolaryngol* 2006; 17:2-5.
- Soares CB, Caio.Belem R., Almeida MS, Lopes Pde M, Beltrão RV, Pontual Ados A, Ramos-Perez FM,et al. Human identification study by means of frontal sinus imaginological aspects. *Forensic Sci Int* 2016;262:183-9.
- Som PM, Curtin HD,editors. Head and Neck Imaging 5<sup>th</sup> ed. St. Louis : Mosby Elsevier; 2011.p.123-4.
- Amin SM. External endoscopic multiportal frontal sinus obliteration for laterally pneumatized frontal sinus: a feasibility study. *Egypt J Otolaryngol* 2018;34:105-10.
- McCoul ED , Tipirneni KE. The Bifurcated Frontal Sinus. *OTO Open* 2018;2:2473974X18764879.
- Wormald PJ. The agger nasi cell: the key to understanding the anatomy of the frontal recess. *Otolaryngol Head Neck Surg* 2003;129:497-507.
- Choby G , Thamboo A, Won TB, Kim J, Shih LC, Hwang PH. Computed tomography analysis of frontal cell prevalence according to the International Frontal Sinus Anatomy classification. *Int Forum Allergy Rhinol* 2018; 8: 825 -30.
- Akhlaghi M, Bakhtavar K, Moarefdoost J, Kamali A, Rafeifar S. Frontal sinus parameters in computed tomography and sex determination. *Leg Med (Tokyo)* 2016;19:22-7.
- Cossellu G, De Luca S, Biagi R, Farronato G, Cingolani M, Ferrante L, et al. Erratum to: Reliability of frontal sinus by cone beam-computed tomography (CBCT) for individual identification. *Radiol Med* 2015;120: 1130-6.
- Morais Marques JA, Musse Jde O, Gois BC, Cavalcante Galvao LC, Paranhos LR. Cone beam computed tomography analysis of the frontal sinus in forensic investigation. *Int J Morphol* 2014; 32:660 -5.
- Souza LA Jr, Marana AN, Weber SAT. Automatic frontal sinus recognition in computed tomography images for person identification. *Forensic Sci Int* 2018;286:252-64.
- Khojastepour L, Mirhadi S, Mesbahi SA. Anatomical variation of ostiomeatal complex in CBCT patients seeking rhinoplasty. *J Dent (Shiraz)* 2015; 16: 42-8.
- de Andrade PF, Silva JNN, Sotto-Maior BS, Ribeiro CG, Devito KL, Souza Picorelli Assis NM. Three-dimensional analysis of impacted maxillary third molars: A cone-beam computed tomographic study of the position and depth of impaction. *Imaging Sci Dent* 2017; 47: 149-55.