

Vital pulp therapy with two different calcium-silicate cements: two cases report

Shiva Alvandifar¹, Naeime Rayiat¹✉

1. Postgraduate Student, Student Research Committee, Babol University of Medical Sciences, Babol, IR Iran.

✉Corresponding Author: Naeime Rayiat, Faculty of Dentistry, Babol University of Medical Sciences, Babol, IR Iran.

Email: rayiatn@yahoo.com Tel: +989111704654 ORCID (0000-0001-6140-9908)

Received: 2 Feb 2018 Accepted: 4 Jul 2018

Abstract

It is a worthy aim to preserve the pulp vitality in teeth with immature root in order to continue the root's maturation. Traumatic injuries and caries are two main reasons for pulp exposure in immature teeth. This article describes two vital pulp therapies on two patients, a nine-year-old boy with traumatized central tooth and a 10-year-old boy with caries exposure in a premolar tooth. Both teeth had open apices in radiography. After removing inflamed pulp, the pulp cap was done using calcium silicate cements (CEM cement, MTA angelus) and then, the teeth were restored with filling material. In periodical follow-ups, both treated teeth remained functional, with complete root development and apex formation. Regarding to the potentiality of pulp healing in immature teeth, vital pulp therapy (VPT) can be an acceptable treatment. However, further clinical studies with longer follow-up periods are recommended.

Keywords: CEM cement, MTA-angelus, Tooth injuries

Citation for article: Alvandifar S, Rayiat N. Vital pulp therapy with two different calcium-silicate cements: two cases report. Caspian J Dent Res 2018; 7: 54-8.

وایتال پالپ تراپی با دو سمان کلسیم سیلیکات مختلف: گزارش دو مورد

شیوا الوندی فر^۱، نعیمه رعیت^{*۱}

۱. دانشجوی دستیاری، کمیته تحقیقات دانشجویی، دانشگاه علوم پزشکی بابل، بابل، ایران.

*نویسنده مسئول: نعیمه رعیت، دانشکده دندانپزشکی، دانشگاه علوم پزشکی بابل، بابل، ایران.

پست الکترونیکی: rayiatn@yahoo.com: تلفن: ۴۴۶۵۰۹۸۹۱۱۷۰

چکیده

کمک به حفظ حیات پالپ برای ادامه تکامل ریشه یک هدف ارزشمند در دندان هایی با ریشه نابالغ است. صدمات تروماتیک و پوسیدگی ۲ علت اصلی اکسپوز پالپ در دندان های نابالغ می باشد. این مقاله در مورد دو درمان وایتال پالپ تراپی یکی پسر ۹ ساله با دندان سانتال تروما دیده و دیگری پسر ۱۰ ساله با دندان پر مولر با اکسپوز پوسیدگی است که هر دو دندان در رادیوگرافی دارای آپکس باز بودند و بعد از برداشت پالپ ملتهب، پوشش پالپی با سمان های کلسیم سیلیکات (CEM, MTA) انجام شد و سپس دندان ها با مواد پر کردنی ترمیم شدند. در فالوآپ های دوره ای دندان ها فانکشنال بوده و ادامه تکامل ریشه و تشکیل آپکس قابل مشاهده بود. بنابراین با توجه به پتانسیل ترمیم پالپ در دندان های نابالغ، وایتال پالپ تراپی می تواند یک درمان قابل قبول باشد. با این حال مطالعات کلینیکی بیشتر با دوره های فالوآپ طولانی تر توصیه می شود.

واژگان کلیدی: سمان مخلوط غنی شده کلسیمی، سمان تری اکسید معدنی، صدمات دندان

Introduction

Traumatic injuries and dental caries are the greatest challenges in development of the teeth that can lead to irreversible injuries and arrest the normal development of the root. [1] VPT is a conservative treatment for carious and traumatized teeth by vital pulp and open apices, [2, 3] which leads to physiological development of the root and apical closure; this procedure is referred to as apexogenesis including partial or complete pulpotomy. [4] Partial pulpotomy (shallow or Cvek pulpotomy) is defined as the removal of a small portion of the vital coronal pulp as a means of preserving the remaining coronal and radicular pulp tissues. Full pulpotomy involves the removal of the entire coronal pulp to a level of the root orifices. After amputation of the coronal pulp, a capping material is placed over the remaining exposed pulp tissue. The proper capping material should be biocompatible and bactericidal, and be able to form a biologic and bacterial tight seal and induce hard tissue formation. [5] Calcium hydroxide has been the material of choice in VPT for a long time, and the studies showed that the dentin bridge formation under the calcium hydroxide layer is not predictable and it has tunnel-shape defects that can act as pathways for bacterial leakage and inflammatory changes. [6-9]

Calcium silicate cements like mineral trioxide aggregate (MTA) and calcium enriched mixture (CEM) were introduced for VPTs. MTA is able to induce hard tissue formation and preserve the integrity of pulp tissues. In comparison to calcium hydroxide, it produces a thicker dentinal bridge, less inflammation and less pulp necrosis. [3, 10, 11] Clinical application of CEM cement is similar to MTA, but they have different chemical composition. Because of the potential discoloration effects of MTA, the use of CEM cement is recommended in aesthetics zone. [12] CEM is able to form hydroxyapatite and consequently a dentinal bridge, and it can induce differentiation of human dental pulp stem cells. [13] This report presents two VPT cases on immature permanent teeth using calcium silicate cements.

Case 1

A 10-year-old boy was referred to Babol Faculty of Dentistry, complaining about the deep caries in his upper right second premolar tooth. There was no history of trauma and medical problem. The patient reported about pain, provoked by cold drink. An extensive carious lesion was observed in intraoral examination,

the tooth responded to pulp vitality test with severe lingering pain, but there was no pain during percussion and palpation. Radiographic examinations showed a deep caries of tooth #4 with immature apex. The final diagnosis was irreversible pulpitis with normal periapex.

The access cavity was prepared with diamond fissure bur (Diatech, Heerbrugg, Switzerland) under local anesthesia with 2% lidocaine and 1/80000 epinephrine (Darupakhsh, Tehran, Iran). Tooth isolated with rubber dam. After removing the caries and the roof of pulp chamber, about 2 millimeters of coronal pulp and inflamed pulp were amputated by using a long shank sterile round diamond bur # 2 (Diatech, Heerbrugg, Switzerland) with high speed and copious water spray in order to prevent damaging the adjacent pulp.

Homeostasis was achieved via placing cotton pellet moistened with 5/25% sodium hypochlorite over the amputated pulp for 5 minutes. Then, according to the instructions, the powder and liquid of MTA Angelus (Londrina –PR, Brazil) were mixed and placed over the amputated pulp and surrounding dentin with sterile plastic instrument. Next, MTA was adapted by cavity walls with mild pressure of dry cotton pellet. Ultimately, the wet cotton and Cavite temporary filling (Asia Chemi Teb Co, Tehran, Iran) were placed. After 24 hours, the tooth was restored by a composite restoration. Patient was recalled 1, 3, 6, 12, 18 and 24 months after the treatment for follow-up (figures 1). The tooth remained without any sign and symptoms. The radiographic examinations indicated the normal root maturation.

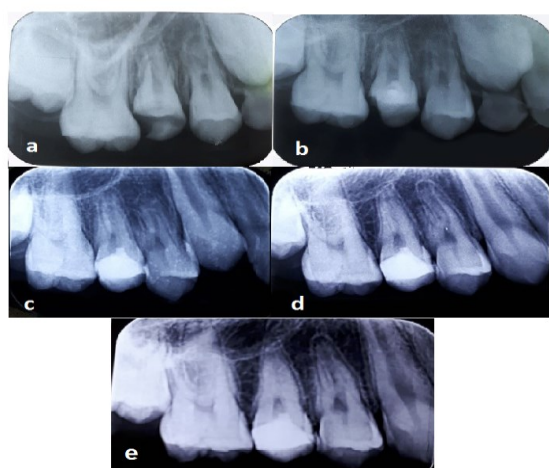


Figure 1. (a) Preoperative radiography (b) immediately post-operative radiography (c) 6-month recall (d) 18-month recall (e) 24-month recall

Case 2

A 9-year-old boy with crown fracture in maxillary left central incisor was referred to Babol Faculty of Dentistry 3 days after a traumatic injury. In clinical examination, the complex crown fracture with pulp exposure of tooth #9 was observable and there was no sensitivity to percussion and palpation. In radiographic evaluation, the tooth was immature (figure 2). Other anterior maxillary and mandibular teeth were examined and evaluated for lack of crown fracture, and all were normal in percussion and vitality pulp tests. According to the clinical and radiographic examination, the VPT was considered for tooth#9. After injecting the 2% lidocaine with 1/80000 epinephrine (Darupakhsh, Tehran, Iran), the tooth was isolated by rubber dam and disinfected with 5/25 % sodium hypochlorite. Then, the coronal inflamed pulp tissue was removed by sterile high-speed diamond round bur# 2 (Diatech, Heerbrugg, Switzerland) under water coolant.

Homeostasis was achieved through gentle placement of moistened sterile cotton pellet over the amputated pulp. Next, according to the instructions, CEM cement (Yektazist Dandan, Tehran, Iran) powder and liquid were mixed together and placed over the pulp tissue using sterile plastic instrument. Afterwards, CEM was adapted by cavity walls with mild pressure of dry cotton pellet. Finally, the wet cotton and Cavite temporary filling (Asia Chemi Teb Co, Tehran, Iran) were placed. After 24 hours, the tooth was restored by a composite restoration (figure 3). After one week, the tooth was examined and had no sign and symptoms. The next follow-ups represented the maturation of root after 3, 6, 12 and 18 months (figure 4).

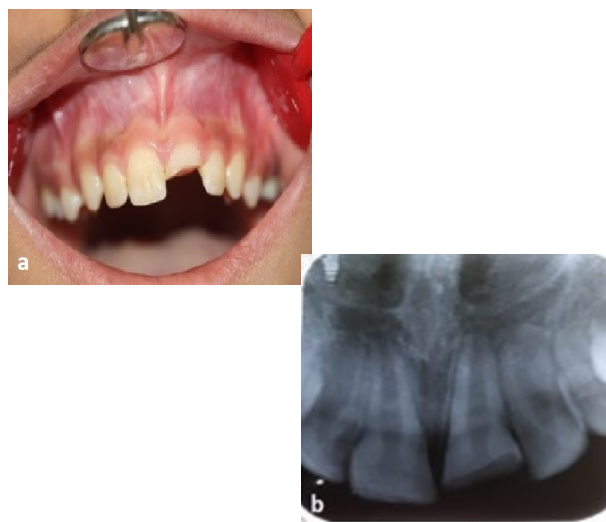


Figure2. (a) Preoperative photograph (b) Preoperative radiography

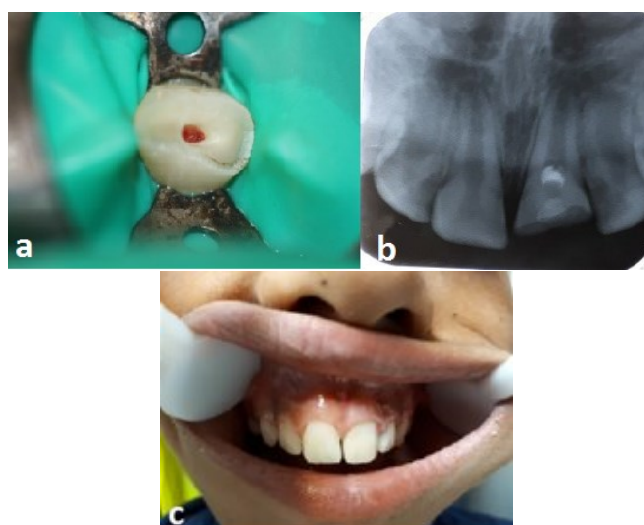


Figure 3. (a) Homeostasis (b) Post-operative radiography (c) Postoperative photograph

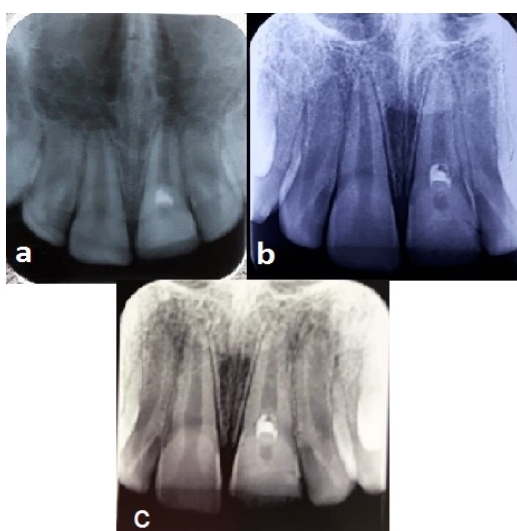


Figure 4. (a) 6-month recall (b) 12-month recall (c) 18-month recall

Discussion

Root canal therapy in immature permanent teeth has some challenges to achieve complete apical seal. Moreover, thin dentinal walls will increase the probability of root fracture.^[2] The primary aim of VPT in teeth with immature roots is to preserve the pulp vitality and help the normal root development. This is a reasonable and acceptable treatment with lower cost and time in immature teeth. Trauma and caries are two main reasons for pulpal exposure.^[1]

Linsuwanont et al., in a retrospective study, mentioned that the presence of clinical signs of irreversible pulpitis and presence of periapical radiolucency should not be considered as contraindication for pulpotomy.^[14] Moreover,

Tsukiboshi et al. stated pulpotomy as an alternative treatment of immature teeth with partial vital pulp tissue and apical periodontitis.^[15] In first reported case, favorable treatment outcomes have been achieved in tooth #4 diagnosed with irreversible pulpitis. Traumatic exposures such as crown fractures usually lead to pulp contamination by saliva and oral bacteria. In second case reported in this article, considering the longer period of pulpal exposure, we performed cervical pulpotomy.

Root development and normal apex closure are the trustable prognostic index to evaluate the successful of VPT in immature teeth. Due to the probability of root obliteration in the future and the need for a more aggressive treatment like RCT, these treatments need a long-time follow-up. There are different materials for pulp capping that calcium hydroxide is the oldest one. Recently, the entrance of bioceramics has created a revolution in endodontic materials. These materials have excellent tissue compatibility and are ideal for VPT.^[16] MTA is one of the bioceramic materials, used as apical sealant and pulp cap material in apexification and apexogenesis treatments and restoring the perforations.^[17] CEM cement is the other cements of calcium silicate that has different chemical composition with MTA, but has similar clinical application; CEM has shorter setting time, better handling, effective seal and has no tooth discoloration.^[16] In this report, MTA was used in tooth #4 and CEM cement was used in tooth #9 as well as less color change was observed in CEM than MTA. Both of these cements have similar sealing ability, setting expansion, and cyto-compatibility. Finally, the pulp healing resulted from these two cements probably is related to the sealing capacity, anti-microbial activity and the ability to induce the hard tissue barrier.^[2]

Authors' Contributions

The data of the cases were collected by Shiva Alvandifar and Naeime Rayiat. Interpretation of cases and drafting of manuscript were performed by Shiva Alvandifar. The manuscript supervision was conducted by Naeime Rayiat.

References

- Witherspoon DE, Small JC, Harris GZ. Mineral trioxide aggregate pulpotomies: a case series outcomes assessment. *J Am Dent Assoc* 2006;137:610-8.
- Sabbagh S, Sarraf Shirazi A, Eghbal MJ. Vital pulp therapy of a symptomatic immature permanent molar with long-term success. *Iran Endod J* 2016;11: 347-9.
- Nosrat A, Asgary S. Apexogenesis treatment with a new endodontic cement: a case report. *J Endod* 2010;36:912-4.
- Ashraf H, Rahmati A, Amini N. Vital pulp therapy with calcium-silicate cements: report of two cases. *Iran Endod J* 2017;12: 112-5.
- Witherspoon DE. Vital pulp therapy with new materials: new directions and treatment perspectives--permanent teeth. *J Endod* 2008;34:S25-7.
- Cox CF, Bergenholtz G, Heys DR, Syed SA, Fitzgerald M, Heys RJ. Pulp capping of dental pulp mechanically exposed to oral microflora: a 1-2 year observation of wound healing in the monkey. *J Oral Pathol* 1985;14:156-68.
- Stanley HR. Criteria for standardizing and increasing credibility of direct pulp capping studies. *Am J Dent* 1998; S17-34.
- Asgary S, Eghbal MJ, Parirokh M, Ghanavati F, Rahimi H. A comparative study of histologic response to different pulp capping materials and a novel endodontic cement. *Oral Surg Oral Med Oral Pathol Oral Radiol Endod* 2008;106:609-14.
- Pitt Ford TR, Roberts GJ. Immediate and delayed direct pulp capping with the use of a new visible light-cured calcium hydroxide preparation. *Oral Surg Oral Med Oral Pathol* 1991;71:338-42.
- Ford TR, Torabinejad M, Abedi HR, Bakland LK, Kariyawasam SP. Using mineral trioxide aggregate as a pulp-capping material. *J Am Dent Assoc* 1996;127:1491-4.
- Patel R, Cohenca N. Maturogenesis of a cariously exposed immature permanent tooth using MTA for direct pulp capping: a case report. *Dent Traumatol* 2006; 22: 328-33.
- Asgary S, Shahabi S, Jafarzadeh T, Amini S, Kheirieh S. The properties of a new endodontic material. *J Endod* 2008; 34:990-3.
- Peng C, Zhao Y, Yang Y, Qin M. [Mineral trioxide aggregate pulpotomy for the treatment of immature permanent teeth with irreversible pulpitis: a preliminary clinical study]. *Zhonghua Kou Qiang Yi Xue Za Zhi* 2015; 50:715-9. [In Chinese]
- Linsuwanont P, Wimonsutthikul K, Pothimoke U, Santiwong B. Treatment outcomes of mineral trioxide aggregate pulpotomy in vital permanent teeth with carious pulp exposure: the retrospective study. *J Endod* 2017;43:225-30.
- Tsukiboshi M, Ricucci D, Siqueira JF Jr. Mandibular premolars with immature roots and apical periodontitis lesions treated with pulpotomy: report of 3 cases. *J Endod* 2017; 43:S65-S74.
- Utneja S, Nawal RR, Talwar S, Verma M. Current perspectives of bio-ceramic technology in endodontics: calcium enriched mixture cement - review of its composition, properties and applications. *Restor Dent Endod* 2015; 40: 1-13.
- Vallés M, Roig M, Duran-Sindreu F, Martínez S, Mercadé M. Color stability of teeth restored with biodentine: a 6 month In vitro study. *J Endod* 2015; 41: 1157-60.