

## The effect of fixed orthodontic treatment with first premolar extraction on mandibular third molars angulation and retromolar space

Sedigheh Sheikhzadeh<sup>1✉</sup>, Allahyar Geramy<sup>2</sup>, Manouchehr Rahmati Kamel<sup>3</sup>,  
Tania Ghasemi<sup>3</sup>, Hemmat Gholinia<sup>4</sup>

1. Assistant Professor, Dental Materials Research Center, Health Research Institute, Babol University of Medical Sciences, Babol, IR Iran.
2. Professor, Department of Orthodontics, School of Dentistry, Tehran University of Medical Sciences, Tehran, IR Iran.
3. Assistant Professor, Oral Health Research Center, Health Research Institute, Babol University of Medical Sciences, Babol, IR Iran.
4. MSc in Statistics, Health Research Institute, Babol University of Medical Sciences, Babol, IR Iran.

✉ **Corresponding Author:** Sedigheh Sheikhzadeh, Faculty of Dentistry, Babol University of Medical Sciences, Babol, I R Iran.

**Email:** elfsh@yahoo.com

**Tel:** +981132291408-9

Received: 20 Oct 2017

Accepted: 17 Mar 2018

### Abstract

**Introduction:** In most orthodontic patients, mandibular 3<sup>rd</sup> molars are in early stages of calcification, and prediction of eruption status would be difficult during the course of orthodontic treatment. The aim of this study was to evaluate the effect of first premolar extraction with moderate anchorage on angular changes of third mandibular molar after orthodontic treatment.

**Materials & Methods:** Panoramic radiographs of 50 skeletal class I patients with normal facial height were selected. The patients were divided into two groups of extraction and non-extraction treatments. The angle between 2<sup>nd</sup> and 3<sup>rd</sup> molars and 3<sup>rd</sup> molar angle to mandibular plane were evaluated. Space for eruption of 3<sup>rd</sup> molar and 3<sup>rd</sup> molar position relative to ramus were evaluated with regard to Pell and Gregory classification. Paired T-test was used to compare the changes after treatments.

**Results:** In both groups, 3<sup>rd</sup> molar angle relative to mandibular plane was increased after the treatment but the difference was not significant. M2-M3 angle changed during the treatments but it was not significant ( $P>0.05$ ). The retromolar space had significantly higher amounts in extraction groups after the treatment ( $P<0.001$ ). In non-extraction group, there was significant increase in stage I of Pell and Gregory classification ( $P<0.001$ ). In extraction group, counts of patients with no space for eruption of M3M were decreased and the difference was significant ( $P<0.001$ ).

**Conclusion:** Extraction of premolars did not have any significant positive effect on mandibular 3<sup>rd</sup> molar angulation but it can increase the posterior space for eruption of wisdom teeth.

**Keywords:** Angulation, Extraction, Third molar, Panoramic radiography

**Citation for article:** Sheikhzadeh S, Geramy A, Rahmati Kamel M, Ghasemi T, Gholinia H. The effect of fixed orthodontic treatment with first premolar extraction on mandibular third molars angulation and retromolar space. Caspian J Dent Res 2018; 7: 43-8.

## بررسی اثر درمان ارتودنسی ثابت با کشیدن پره مولرهای اول مندیبل بر زاویه مولرهای سوم و فضای رترومولر

صدیقه شیخ زاده\*، اللهیار گرامی، منوچهر رحمتی کامل، تانیا قاسمی، همت قلی نیا

### چکیده

**مقدمه:** در بسیاری از بیماران ارتودنسی، مولرهای سوم مندیبل در مراحل اولیه کلسیفیکاسیون می باشند و معمولاً پیش بینی وضعیت رویشی آنها در طی درمان ارتودنسی مشکل می باشد. هدف مطالعه حاضر بررسی اثر کشیدن پره مولرهای اول با انکوربیج متوسط بر تغییرات زاویه ای مولر سوم مندیبل پس از درمان ارتودنسی می باشد.

**مواد و روش ها:** پانورامیک ۵۰ بیمار ۱۶ تا ۲۰ ساله اسکلتال کلاس I با ارتفاع صورتی نرمال انتخاب شد. بیماران در دو گروه درمان Ext و Non-ext تقسیم شدند. زاویه مولرهای دوم و سوم با پلن مندیبولر و زاویه این دندانها با یکدیگر ارزیابی شدند. فضای رویش مولر سوم و موقعیت مولر سوم نسبت به راموس توسط طبقه بندی Pell و Gregory بررسی گردید. Paired-T test برای بررسی تغییرات پس از درمان استفاده شد.

**یافته ها:** زاویه مولرهای دوم و سوم در هر دو گروه نسبت به پلن مندیبولر افزایش یافته بود اما این تغییرات پس از درمان معنادار نبود ( $P > 0.05$ ). زاویه مولر دوم و سوم در طی درمان تغییر کرد اما این تغییرات معنادار نبود ( $P > 0.05$ ). فضای رویش مولرهای سوم در گروه کشیدن بصورت معناداری افزایش یافته بود ( $P < 0.001$ ). در طبقه بندی Pell و Gregory، در گروه Non-ext، stage I افزایش معناداری داشت ( $P < 0.001$ ). در گروه Ext تعداد افراد بدون فضا برای رویش مولر سوم کاهش یافته بود و این تفاوت معنادار بود ( $P < 0.001$ ).

**نتیجه گیری:** کشیدن پره مولرها اثر مثبت معناداری بر زاویه مولرهای سوم مندیبل ندارد اما این کار می تواند فضای رویش مولر سوم را افزایش دهد.

**واژگان کلیدی:** زاویه، کشیدن، مولر سوم، رادیوگرافی پانورامیک

### Introduction

The impact of mandibular 3<sup>rd</sup> molar (M3M) on dental arch has been paid long attention in orthodontic literatures. M3M impaction is a common problem in dentistry. In most orthodontic patients, M3Ms are in early stages of calcification and prediction of eruption status is very difficult during the course of orthodontic treatment. [1] When M3M comes in proximity with second molar in early ages, angular changes in M3M long axis occur with respect to mandibular plane which tend to place it in a more upright position. [2-4] Some studies investigated the effect of fixed orthodontic treatment on the 3<sup>rd</sup> molar inclination or position. [3-8] Although some evaluations have claimed that in patient with intact dentition, non-extraction orthodontic therapy would increase the risk of 3<sup>rd</sup> molar impaction due to distal tipping or distal driving of molars, [4,6] some studies have shown that there is no significant difference in M3M angulation in extraction and non-extraction cases after orthodontic treatment. [7-10]

Besides, several investigations concluded that premolar extraction had a positive influence on the developing 3<sup>rd</sup> molar angulation [11-13] while non-extraction therapy induced no or little changes on it. [11,14] Stagers et al. claimed that the type of anchorage and mechanics had greater effect on 3<sup>rd</sup> molar angulation than the premolar extraction itself. [1] Abu Alhaja et al. showed that M3M impaction is more prevalent in skeletal class III patients due to the decreased retromolar space. [15] Tooth size, indicating racial differences has impacts on the available space for eruption of teeth in dental arch. The role of anchorage considerations, skeletal morphology and growth in retromolar space has not been mentioned in most previous studies so the aim of the present study was to evaluate the effect of first premolar extraction with moderate anchorage on angular changes of third mandibular molar after orthodontic treatment in skeletal class I Iranian patients with normal facial height.

## Materials and Methods

In this retrospective study, panoramic radiographs of 50 patients<sup>[16]</sup> (27 female, 23 male) treated in a private orthodontic office were selected. The patients were divided into two groups: 25 patients of the first group had undergone fixed orthodontic treatment with extraction of first premolars and moderate anchorage. Second group included 25 patients who were treated without any extractions.

The Non-extraction group with lower arch crowding of 1-4 mm was treated via arch expansion or interproximal stripping of teeth. Pretreatment age in extraction group was  $17 \pm 2.1$  and the age range in non-extraction group was 16-20 years (Mean age of  $17 \pm 1.3$  years).

The patients with skeletal class I morphology (ANB=1-4, Wits= 0, -1) and normal face height (mandibular plane angle = 22-29, Jarabak index= 62-65) were included in the study. Patients with previous history of trauma, prior fixed orthodontic treatment or molar distal driving, skeletal deformities, dental missing or mandibular pathology were excluded from the study. Pretreatment and post treatment panoramic graphs, taken in the same radiology centers with high resolution were chosen.

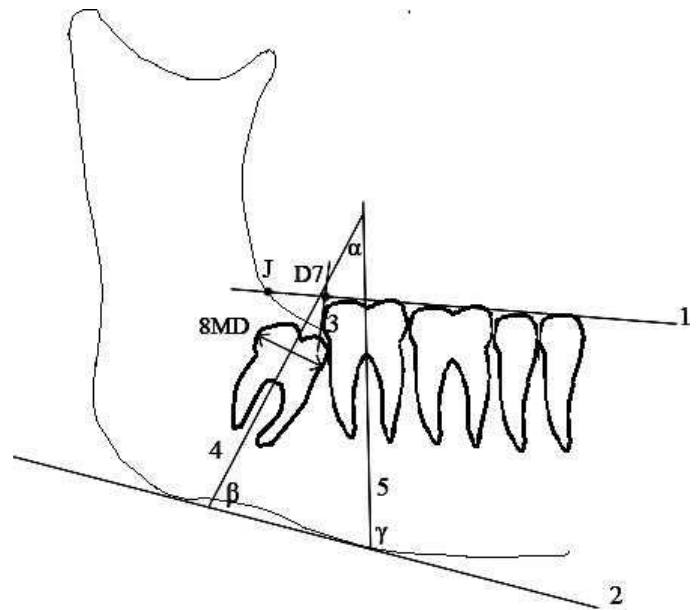
M3M position relative to ramus was evaluated with regard to Pell and Gregory classification<sup>[17]</sup>: stage I demonstrates enough space for eruption of M3M. In stage II, there is small space for eruption and no space for M3M eruption shows the third stage.

The following variables described by Turkoz<sup>[10]</sup> were measured on radiographs: angle  $\alpha$  was defined as the angle between long axis of the second and third molars. Intersection between long axis of the M3M and mandibular plane represented the angle  $\beta$ . Retromolar space (D) was calculated between J-point and D7 point. Point J was the intersection between mandibular occlusal plane and ramus. Point D7 was defined by intersection of occlusal plane and most distal surface of second molar (Figure 1).

The graphs were analyzed by one orthodontist and method errors were calculated between measurements performed twice in 10 days. Statistical analysis was performed using SPSS 21.

Independent t-test was used to determine the significant differences between groups. Paired T-test

was used to assess the significances before and after the treatments.



**Figure1. Linear and angular measurements (registered from Turkuz et al study)**

## Results

Descriptive and analytic data in both groups are illustrated in table 1. Reliability test showed an average method error of 0.06 mm which was not significant (P=0.76).  $\beta$  angle in both groups in right and left sides was increased and the amount was higher in Ext-group but the difference was not significant. The angle between 2<sup>nd</sup> and 3<sup>rd</sup> molars changed during the treatments but it was not significant (Table 1).

Comparing the retromolar space for eruption of M3M showed that D in right and left sides had not significant differences in both groups before the treatment but D had significantly higher amounts in extraction group after the treatment (P<0.001). Descriptive data of Pell and Gregory classification in each group are listed in table 2. In non-extraction group, there was significant increase in stage I of Pell and Gregory classification (P<0.001). In extraction group, a number of patients with no space for eruption of M3M were decreased with significant difference (P<0.001).

**Table 1. Linear and angular changes in extraction and non-extraction groups**

Variables	Non-Extraction	Extraction	Pvalue **
	Mean±Sd (25)	Mean±Sd (25)	
$\alpha$ _Left_before	20.78±3.58	19.72±3.60	0.30
$\alpha$ _Left_after	19.92±3.87	20.08±3.71	0.88
P*	0.20	0.67	-
$\beta$ _Left_before	72.88±4.56	74.24±3.75	0.25
$\beta$ _Left_after	73.40±3.85	74.78±3.80	0.20
P*	0.47	0.52	-
$\gamma$ _Left_before	90.04±2.97	93.80±3.55	0.00
$\gamma$ _Left_after	90.56±3.11	94.32±3.80	0.00
P*	0.45	0.45	-
D_Left_before	5.88±1.81	6.64±2.15	0.18
D_Left_after	6.18±1.95	8.92±2.69	0.00
P*	0.17	0.00	-
diff_D_Left	0.30±1.02	2.28±2.33	0.00
$\alpha$ _Right_before	16.76±2.94	19.76±3.89	0.004
$\alpha$ _Right_after	17.24±3.71	20.28±3.91	0.007
P*	0.41	0.49	-
$\beta$ _Right_before	75.78±3.78	72.44±4.24	0.005
$\beta$ _Right_after	76.52±4.92	73.00±4.41	0.01
P*	0.27	0.43	-
$\gamma$ _Right_before	90.88±3.55	90.98±4.58	0.93
$\gamma$ _Right_after	91.68±4.25	91.96±3.97	0.81
P*	0.21	0.18	-
D_Right_before	5.68±2.17	6.24±1.92	0.33
D_Right_after	6.10±2.20	9.28±1.51	0.00
P*	0.17	0.00	-
diff_D_Right	0.42±1.23	3.04±1.09	0.00

.P\*: Paired T- test P\*\*: Independent T- test

**Table 2. Sample distribution in pell and gregory classification**

Pell and Gregory classification	Non-Extraction (Before)	Non-Extraction (After)	Extraction (Before)	Extraction (After)
Stage I	8(%16)	15(%30)	4(%8)	3(%6)
Stage II	41(%82)	31(%62)	30(%60)	29(%58)
Stage III	1(%2)	4(%8)	16(%32)	18(%36)

**Discussion**

The present study was conducted to evaluate the effect of first premolar extraction with moderate anchorage on angular changes of third mandibular molar after orthodontic treatment in skeletal class I Iranian patients with normal facial height. In this study, panoramic radiographs were used to measure the linear

and angular changes in position of M3M. Previous studies advocated the accuracy of panoramic radiographs for measuring the M3 changes during the treatment. [18, 19] The angular changes in M3M were investigated. The M3M angulation relative to mandibular plane was increased, indicating the M3M tended to be get upright throughout the treatments in

both groups, but the changes were not significant. This result may be in agreement with the findings of several previous studies.<sup>[7-10, 20, 21]</sup> In contrary to our findings, several authors reported that extraction of premolars would result in significant M3M up righting.<sup>[11, 14]</sup>

According to Graber, posterior space for the eruption of 2<sup>nd</sup> and 3<sup>rd</sup> molars increase 1.5 millimeters per year until the age of 14 in girls and 16 in boys.<sup>[22]</sup> Besides, Richardson showed that an average angular change of 11.2 mm in M3M relative to mandibular plane occurs in 10-15 year-old persons.<sup>[2]</sup> In the present study, the patients older than 16 years were included to decrease the impact of growth in posterior segment, and the natural rotational movements had previously occurred in M3M so this age maybe an ideal time to evaluate the effect of orthodontic treatment on M3M inclination.

“D” findings were increased after the treatment in both groups, but they were significantly higher in extraction group after the treatment. The increased amounts may be due to the growth in retromolar pad but the significant differences were related to the extraction space closure with moderate anchorage, which led to mesial movement of posterior teeth. Earlier studies also showed that extraction of premolars increased the available space for eruption of M3Ms.<sup>[7, 8]</sup> The increased space in retromolar pad may be a reason for increased angulation of M3Ms in Extraction and Non-extraction groups.

Having evaluated the eruption space of M3M based on Pell and Gregory, in Non-extraction group, there was significant increase in stage I of Pell and Gregory classification. The number of patients with no space for eruption of M3M was decreased in Extraction group. Miclotte et al. also reported that the percentage of stage III in patients treated with premolar extraction was higher than Non-extraction group.<sup>[23]</sup>

Retrospective nature of the present study could be an important limitation but the authors tried to decrease the confounders by excluding factors like age, gender, growth, skeletal morphology and anchorage consideration during space closure.

## Conclusion

Within the limitations of the present study, it was concluded that the extraction of first premolars did not have any significant positive effect on M3M angulation but it could increase the posterior space for eruption of wisdom teeth.

**Funding:** This article is derived from the results of a research project in Babol University of Medical Sciences (Grant No: 964448). Hereby, the funding and support of the Research Deputy of Babol University of Medical Sciences are highly appreciated.

**Conflict of interest disclosure:** The authors state that they have no conflicts of interest.

## Author contributions

Study concept and design were proposed by Sedigheh Sheikhzadeh. Acquisition of data was performed by Sedigheh Sheikhzadeh, Tania ghasemi, Manouchahr Rahmati Kamel, Allahyar Geramy. Drafting of the manuscript was done by Sedigheh Sheikhzadeh and Allahyar Geramy. Statistical analysis was performed by Hemmat Gholinia.

## References

1. Stagers JA, Germane N, Fortson WM. A comparison of the effects of first premolar extractions on third molar angulation. *Angle Orthod* 1992; 62:135-8.
2. Richardson ME. The etiology and prediction of mandibular third molar impaction. *Angle Orthod* 1977;47:165-72.
3. Huggins DG. Eruption of lower third molars following orthodontic treatment. *Trans Br Soc Study Orthod*. 1962;67.
4. Silling G. Development and eruption of the mandibular third molar and its response to orthodontic therapy. *Angle Orthod* 1973;43:271–8.
5. Celikoglu M, Kamak H, Akkast I, Oktay H. Effects of orthodontic treatment and premolar extractions on the mandibular third molars. *Aust Orthod J* 2010; 26:160-4.
6. Yigit M, Gokce D, Kocadereli I, Tasar F. The effects of first premolar extractions on third molar angulations. *Angle Orthod* 2005;75:719-22.
7. Miclotte A, Grommen B, Cadenas de Llano-Pérula M, Verdonck A, Jacobs R, Willems G. The effect of first and second premolar extractions on third molars: A retrospective longitudinal study. *J Dent* 2017;61:55-66.
8. Durgesh BH, Gowda KH, AlShahrani OA, Almalki AD, Almalki WD, Balharith MM, et al. Influence of premolar extraction or non-extraction orthodontic therapy on the angular changes of mandibular third molars. *Saudi J Biol Sci* 2016; 23:736-40.

9. Sayse MY, Meral GD, Kocadereli I, Taşar F. The effects of first premolar extractions on third molar angulations. *Angle Orthod* 2005; 75:719-22.
10. Türköz Ç, Ulusoy Ç. Effect of premolar extraction on mandibular third molar impaction in young adults. *Angle Orthod* 2013; 83: 572-7.
11. Jain S, Valiathan A. Influence of first premolar extraction on mandibular third molar angulation. *Angle Orthod* 2009; 79:1143-8.
12. Behbehani F, Artun J, Thalib L. Prediction of mandibular third-molar impaction in adolescent orthodontic patients. *Am J Orthod Dentofacial Orthop* 2006;130:47-55.
13. Elsey MJ, Rock WP. Influence of orthodontic treatment on development of third molars. *Br J Oral Maxillofac Surg* 2000; 38:350-3.
14. Gohilot A, Pradhan T, Keluskar KM. Effects of first premolar extraction on maxillary and mandibular third molar angulation after orthodontic therapy. *J Oral Biol Craniofac Res* 2012; 2:97-104.
15. Abu Alhaija ES, AlBhairan HM, AlKhateeb SN. Mandibular third molar space in different antero-posterior skeletal patterns. *Eur J Orthod* 2011; 33:570-6.
16. Ahmed I, Gul-e-Erum, Kumar N. Mandibular third molar angulation in extraction and non-extraction orthodontic cases. *J Ayub Med Coll Abbottabad* 2011; 23:32-5.
17. Pell GJ, Gregory GT. Impacted third molars: classification and modified technique for removal. *Dent Dig* 1933; 39:330-8.
18. Stramotas S, Geenty JP, Darendeliler MA, Byloff F, Berger J, Petocz P. The reliability of crown-root ratio, linear and angular measurements on panoramic radiographs. *Clin Orthod Res* 2000; 3:182-91.
19. Atieh MA. Diagnostic accuracy of panoramic radiography in determining relationship between inferior alveolar nerve and mandibular third molar. *J Oral Maxillofac Surg* 2010; 68:74-82.
20. Russell B, Skvara M, Draper E, Proffit WR, Philips C, White RP Jr. The association between orthodontic treatment with removal of premolars and the angulation of developing mandibular third molars over time. *Angle Orthod* 2013; 83:376-80.
21. Mihai AM, Lulache IR, Grigore R, Sanabil AS, Boianuiu S, Ionescu E. Positional changes of the third molar in orthodontically treated patients. *J Med Life* 2013; 6:171-5.
22. Graber Lee W, Vanarsdall Robert L., Jr, Vig Katherine W L, editors. *Orthodontics : current principles & techniques*. 5th ed. Philadelphia : Elsevier/Mosby; 2012. p 449.
23. Miclotte A, Van Hevele J, Roels A, Elaut J, Willems G, Politis C, et al. Position of lower wisdom teeth and their relation to the alveolar nerve in orthodontic patients treated with and without extraction of premolars: a longitudinal study. *Clin Oral Investig* 2014; 18:1731-9.