

A cone-beam computed tomography study of apical and mental foramen's location in mandibular premolars

Azadeh Harandi¹, Ehsan Moudi², Hemmat Gholinia³, Mehdi Akbarnezhad^{4✉}

1. Assistant Professor, Dental Materials Research Center, Health Research Institute, Department of Endodontics, Babol University of Medical Sciences, Babol, IR Iran.
2. Associate Professor, Oral Health Research Center, Health Research Institute, Department of Oral & Maxillofacial Radiology, Babol University of Medical Sciences, Babol, IR Iran.
3. MSc in Statistics, Health Research Institute, Babol University of Medical Sciences, Babol, IR Iran.
4. Dental Student, Student Research Committee, Babol University of Medical Sciences, Babol, IR Iran.

✉ **Corresponding Author:** Mehdi Akbarnezhad, Faculty of Dentistry, Babol University of Medical Sciences, Babol, IR Iran.

Email: Mehdi_Akbarnezhad@yahoo.com

Tel: +989116263631

Received: 23 Sept 2017

Accepted: 4 Mar 2018

Abstract

Introduction: Knowledge of the internal anatomy of the tooth, apical foramen (AF) and mental foramen (MF) is considered a basic prerequisite before root canal surgical and non-surgical treatments. The aim this study is evaluation the distance and situation of AF & MF to anatomic apex of mandibular premolar.

Materials & Methods: In this cross-sectional study, CBCT images of mandibular premolars from 240 patients with a minimum age of 20 years were evaluated. The location and distance of the MF and AF from the anatomical apex in mandibular premolars were investigated. The information was compared in both genders and both sides of mandible, and analyzed using ANOVA, Chi-Square and T-Test.

Results: In the right quadrant, the mean distance from AF to the anatomic apex in the first premolars was higher than the second ones ($p = 0.02$). There was a significant difference among the mean distances from AF to the anatomic apex in various positions of the AF in both quadrants. The MF was closer to the second premolars in both sides ($p < 0.00$). No significant difference was observed between two genders and two sides of the jaw.

Conclusion: possibility of lateral extrusion of canals in the mandibular premolars, the use of the auxiliary devices such as apex locator is useful. According to different place of MF, it's necessary to pay attention to this position during the periapical surgeries in the mandibular premolars, specially in second premolar.

Keywords: Apical foramen, Cone-beam computed tomography, Premolar, Root canal therapy

Citation for article: Harandi A, Moudi E, Gholinia H, Akbarnezhad M. A cone-beam computed tomography study of apical and mental foramen's location in mandibular premolars. Caspian J Dent Res 2018; 7: 27-36.

بررسی موقعیت سوراخ اپیکال و چانه ای نسبت به اپکس آناتومیک در پره مولرهای مندیبل توسط توموگرافی پرتو مخروطی

آزاده هرنندی، احسان موعودی، همت قلی نیا، مهدی اکبر نژاد*

چکیده

مقدمه: آگاهی از آناتومی داخلی دندان و سوراخ اپیکال و سوراخ چانه ای به عنوان پیش‌نیازی اساسی قبل از انجام درمان‌های جراحی و غیرجراحی کانال ریشه محسوب می‌شود. هدف این مطالعه بررسی فاصله و موقعیت سوراخ اپیکال و چانه ای نسبت به اپکس آناتومیک در دندان‌های پره مولر فک پایین می‌باشد.

مواد و روش‌ها: در این مطالعه مقطعی، دندان‌های پره‌مولر مندیبل در CBCT ۲۴۰ بیمار با حداقل سنی ۲۰ سال ارزیابی شدند. موقعیت و فاصله سوراخ اپیکال و چانه ای نسبت به اپکس پره‌مولرهای مندیبل مورد بررسی قرار گرفت. اطلاعات بدست آمده هم در دو گروه و هم در دو طرف مندیبل با هم مقایسه و توسط تست‌های ANOVA, Chi-Square و T-Test تحلیل شدند.

یافته‌ها: در کوادرنانت راست، میانگین فاصله سوراخ اپیکال تا اپکس آناتومیک در پره‌مولرهای اول به طور معنی‌داری بیشتر از پره-مولر دوم بود ($p=0.02$). اختلاف معنی‌داری بین میانگین فواصل سوراخ اپیکال تا اپکس آناتومیک در موقعیت‌های مختلف سوراخ اپیکال در دو کوادرنانت دیده شد. هر دو سمت، سوراخ چانه ای به پره‌مولر دوم نزدیک‌تر بود. در بررسی محل سوراخ چانه ای نسبت به اپکس پره‌مولرها، هیچ اختلاف معناداری در دو جنس و دو سمت فک دیده نشد.

نتیجه‌گیری: احتمال خروج لترالی کانال‌ها در دندان‌های پره مولر فک پایین استفاده از وسایل کمکی مثل اپکس لوکیتور مفید می‌باشد. با توجه به محل‌های متفاوت قرارگرفتن سوراخ چانه ای، در جراحی‌های پری اپیکال در ناحیه پره مولرهای مندیبل به خصوص پره مولر دوم، توجه به محل سوراخ چانه ای ضروری می‌باشد.

واژگان کلیدی: سوراخ اپیکال، توموگرافی کامپیوتری با پرتو مخروطی، پره مولر، درمان کانال ریشه

Introduction

One of the important issues in endodontic treatments is the maintenance of the function, which requires adequate knowledge of the morphology of the tooth, the position of the anatomical apex and AF.^[1] In endodontic treatment, AF is the end-point of the root canal filling.^[2] What is seen in the conventional radiography is anatomic apex which is not necessarily the same as the AF.^[3] Variation in the internal anatomy, especially in the apical region, can be found among the complicated cases in endodontic treatments, especially in the mandibular premolars.^[4] This anatomic variation is also present in the apical foramen, and the AF can be laterally removed through one of the mesial, distal, buccal, or lingual surfaces, which is not accurately observed in radiography.^[1, 5] These internal

complexities can be masked by an external surface with a simple and uniform anatomy, which leads to the unsuccessful treatment.^[6] Precise knowledge of the AF morphology and internal anatomy of the roots is effective in the prognosis of endodontic treatment.^[7] Diversity and complexity of the root are also related to the genetic factors that are important in terms of anthropology, meaning diagnosis of morphology and apical variations is important based on racial populations. The mandibular premolars from endodontic perspective indicate higher endodontic failure rates. One of the main reasons for this failure is the lack of attention to the end-point of the root canal filling and anatomical variations in the apical region.^[8] Mental foramen (MF) is an important anatomical landmark in

the mandible, and evaluating its position related to the surrounding structures, especially its distance from the premolars, is very important in the treatment.^[9]

Determining the position of the MF has inhibition effect on injuries to surrounding structures during endodontic non-surgical and surgical treatments such as pre apical surgery^[10], incision, drainage, vertical incision for the release of mucoperiosteal flap^[11] and local anesthesia infiltration.^[12] Knowledge of the MF position is very important in the pre apical surgeries. In addition, the MF is very important as a part of the mandible, which has nerve and blood vessels.^[13] Studies have shown that the racial variation has an impact on the MF position.^[14]

Cone-beam computed tomography (CBCT) as an important tool could help to evaluate the MF and diagnose it from pre apical lesions and its position relative to the surrounding structures.^[11] So far, the use of CBCT has been attracted more attention in the field of dentistry and treatment plans.^[15] A study in relation to the morphology and anatomy of premolars has been conducted on different ethnic groups such as Turkish, Kuwaiti and Americans.^[16]

Since the anatomy and morphology of the canals and the position of the MF may be different in every race; therefore, the aim of this study was to evaluate the distance and position of the apical and mental foramina from the anatomic apex in mandibular premolars in a population from northern Iran.

Materials & Methods

In this cross-sectional study, the CBCT images of mandibular premolars from 240 patients with a minimum age of 20 years, referred to an oral and maxillofacial radiology center were evaluated and only 177 CBCT images were entered into the study based on the inclusion criteria. This study was approved at the Ethics Committee of Babol University of Medical Sciences [mu Babol.REC.1395.213]. The inclusion criteria included the completeness of the root of the mandibular premolars, complete recognizable apical foramen, absence of the apical resorption and non-

endodontically treated teeth. by the scans were obtained using a Newtom 5G CBCT unit (Quantitative Radiology SRL Co, Verona ,Italy) with high resolution , FOV:8×12, kVp 90,mA6.The images were studied using NTT viewer software program (NTT Software Corporation,Yokohama,Japan) in the coronal view, a line was drawn from the AF to the anatomic apex via 0.5 mm-thick sections, and this distance was measured (Figure.1).

The position of the AF was evaluated in sagittal, axial, *and* coronal planes (Figure.2) In all cases, the measurements were performed three times and the mean was considered as the main size.

To examine the position of the MF, a line parallel to anatomic apex of the first and second premolars was drawn; next, another line was vertically drawn on it; then, the distance from anatomic apex of premolars to the intersection of these two lines were measured with 15-mm-thick sections and; finally, the proximity of the premolars to the MF was determined (Figure.3). Data were analyzed using SPSS 20 through chi-square and t-test. P 0.05 was considered as significant level.

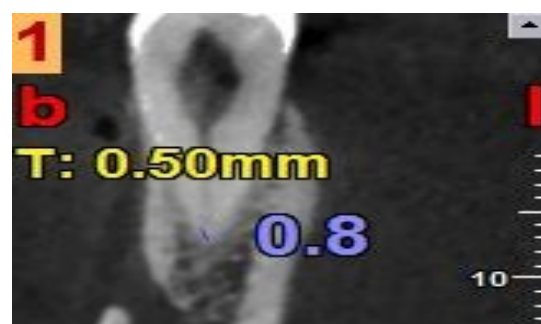


Fig1. Measuring the distance of apical foramen to anatomic apex in coronal plan by NNT viewer

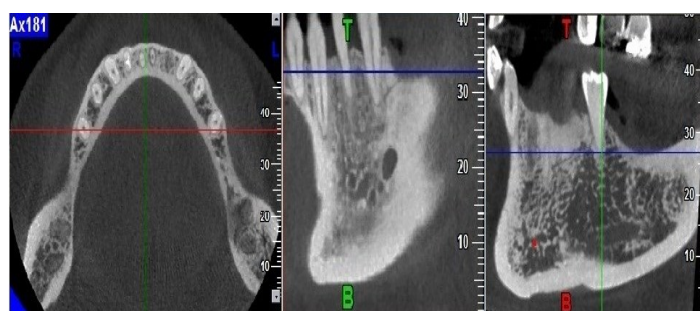


Fig2. Evaluation the position of apical foramen by NNT viewer in axial, sagittal and coronal plan, respectively

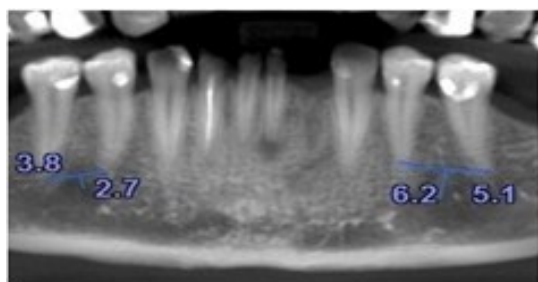


Fig3. Measuring the distance of mental foramen to anatomic apex in panorex plan by NNT viewer

Results

In the present study, 606 single-canal, 16 double-canal and 2 double-rooted premolars were examined. First, 606 single-canal premolars were studied (50.5% of the first premolar, 49.5% of the second premolar, 50.5% of the left, 49.5% of the right and 44.2% and

55.8% were male and female, respectively). The most frequent position of the AF was central (81%) and 19% of the AF was lateral (buccal 7.42%, distal 2.31%, lingual 6.42% and mesial 2.64%). The most common position of the MF was located between the first (PM₁) and second premolars (PM₂) (60.4% between the premolars, 31.2% below the root of the second premolar, 5.9% below the root of the first premolar and 2.3% between the second premolars and first molars). Then, other 18 teeth were individually examined. There was no significant difference in distance from AF to anatomic apex based on gender and quadrant. The distance from the AF to anatomic apex of 606 teeth was measured and the minimum and maximum distances were 0 and 2.40, respectively. The mean distance from AF to anatomic apex of premolars was 0.56 mm (Table1).

Table1. The distance (mm) from AF to anatomic apex in mandibular premolars based on gender, quadrant and tooth

Variable		Number	Mean±SD	Min-Max	p-value
gender	male	267	0.56±0.41	0.00-2.10	0.99
	female	339	0.56±0.42	0.00-2.40	
quadrant	right	273	0.60±0.40	0.00-2.10	0.08
	left	273	0.55±0.44	0.00-2.40	
tooth	PM1	310	0.58±0.42	0.00-2.20	0.32
	PM2	296	0.55±0.41	0.00-2.40	
total		606	0.56±0.41	0.00-0.41	-

In comparison between the first and second premolars in the right quadrant, the mean distance from AF to anatomic apex was significantly higher in the first premolar than second premolar ($p=0.02$). In the study of the position of the AF in the first and second premolars in the right quadrant, a significant difference was found among the mean distances from AF to the anatomic apex in different positions of the AF ($p=0.00$) so that the highest and the lowest mean distances from foramen apical to anatomic apex were related to the mesial and central position of AF, respectively. The most frequent position of the AF was central and the lowest one was mesial (Table 2). In the study of distance from AF to the anatomic apex in the left quadrant, there was no significant difference between the first and second premolars. In the examination of the position of the AF of the first and second premolars in the left quadrant,

there was a significant difference among the mean distances from AF to the anatomic apex in different positions of the AF ($p=0.00$) so that the highest and lowest mean distances from foramen apical to anatomic apex were related to the mesial and central Position of AF, respectively. The most frequent position of the AF exit was central and the lowest one was mesial (Table 3).

The mean distance from MF to anatomic apex was not significantly different between males and females. Meanwhile, there was a significant difference in the mean distance from the MF to the anatomic apex between the first and second premolars of both *sides* of the *jaw* ($p < 0.001$). On both sides of the jaw, the MF was closer to the second premolar. The mean distance from MF to the first premolar was 4.38 mm and to the second premolar was 3.5 mm (Table 4).

Table2. The position of the AF and its distance to the anatomic apex in the mandibular premolars in the right quadrant based on gender

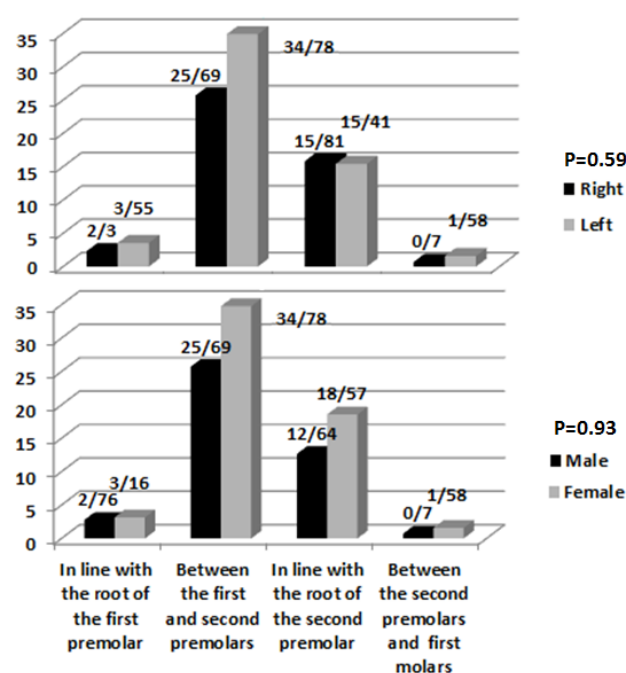
Tooth	Position	Gender	Number	Mean±SD	Min-Max	p-value ^a	p-value ^b	p-value ^c
PM1	buccal	male	8	1.30±0.26	1.00-1.90	0.32	0.00	0.02
		female	9	1.14±0.30	0.70-1.70			
		total	17	1.21±0.28	0.70-1.90			
	lingual	male	5	1.26±0.11	1.10-1.40	0.42		
		female	5	1.16±0.25	0.80-1.50			
		total	10	1.21±0.19	0.80-1.50			
	mesial	male	4	1.40±0.24	1.10-1.70	0.00		
		female	3	1.73±0.35	1.40-2.10			
		total	7	1.54±0.32	1.10-2.10			
	distal	male	-	-	-	-		
		female	1	1.00	1.00-1.00			
		total	1	1.00	1.00-1.00			
	central	male	53	0.45±0.19	0.10-1.00	0.56		
		female	65	0.44±0.22	0.00-1.10			
		total	118	0.45±0.21	0.00-1.10			
PM2	buccal	male	2	1.30±0.28	1.10-1.50	0.22		
		female	7	1.01±0.13	0.80-1.20			
		total	9	1.07±0.19	0.80-1.50			
	lingual	male	5	1.22±0.27	1.00-1.70	0.42		
		female	5	1.38±0.31	1.00-1.80			
		total	10	1.30±0.29	1.00-1.80			
	mesial	male	2	1.55±0.21	1.40-1.70	-	0.00	
		female	-	-	-			
		total	2	1.55±0.21	1.40-1.70			
	distal	male	-	-	-	-		
		female	3	1.23±0.58	0.80-1.90			
		total	3	1.23±0.58	0.80-1.90			
	central	male	55	0.42±0.20	0.10-1.00	0.40		
		female	71	0.38±0.20	0.00-1.00			
		total	126	0.40±0.20	0.00-1.00			

a: Men and Women Comparison

b: Comparison of Position

c: PM₁ and PM₂ Comparison

In the study of MF, no significant difference was observed between males and females ($p=0.93$ (ns)) and between two sides of the jaw ($p=0.93$ (ns)). The most common frequent position of the MF was between the first and second premolars (60.4% among the premolars, 31.2% in line with the root of the second premolar, 5.9% in line with the root of the first premolar and 2.3% among the second premolars and first molars (figure 4). Descriptive information of 16 double-canal premolars the mean, minimum and maximum distances from MF to the anatomic apex of 16 double-canal teeth were 5.20 mm, 2 mm and 9 mm, respectively. The mean, minimum and maximum distances from AF to the anatomic apex of 16 double-canal premolars were 0.69 mm, 0.1 mm and 2.3 mm, respectively. The mean distance from AF to anatomic apex was 0.89 ± 0.68 and 0.53 ± 0.50 mm on the left and right sides, respectively.

**Figure4. Study the position of the MF**

In examining two double-rooted premolars, both teeth of the first premolars were belonged to one patient. In both teeth, the position of the AF exit was central-

central and the mean distance from AF to apex was 0.2 mm. Mean distance from MF to the apex of two double-rooted premolars was 4.3 mm.

Table3. The position of the AF and its distance to the anatomic apex in the mandibular premolars in the left quadrant based on gender

Tooth	Position	Gender	Number	Mean±SD	Min- Max	p-value ^a	p-value ^b	p-value ^c
PM1	buccal	male	2	1.30±0.56	0.90-1.70	1.00		
		female	8	1.17±0.20	1.00-1.60			
		total	10	1.20±0.26	0.90-1.70			
	lingual	male	5	1.40±0.39	0.90-1.80	0.54		
		female	5	1.14±0.75	0.20-2.20			
		total	10	1.27±0.58	0.20-2.20			
	mesial	male	-	-	-	-	0.00	
		female	-	-	-			
		total	-	-	-			
	distal	male	3	1.50±0.36	1.20-1.90	1.00		
		female	3	1.60±0.52	1.00-2.00			
		total	6	1.55±0.40	1.00-2.00			
	central	male	60	0.36±0.21	0.00-1.00	0.32		
		female	71	0.39±0.19	0.00-1.00			
		total	131	0.37±0.20	0.00-1.00			
PM2	buccal	m-ale	3	1.16±0.15	1.00-1.30	0.90		0.46
		female	6	1.31±0.55	0.90-2.40			
		total	9	1.26±0.45	0.90-2.40			
	lingual	male	1	0.80	0.80-0.80	0.66		
		female	8	1.01±0.34	0.40-1.40			
		total	9	0.98±0.33	0.40-1.40			
	mesial	male	3	1.46±0.65	0.80-2.10	1.00	0.00	
		female	4	1.32±0.49	0.90-1.80			
		total	7	1.38±0.51	0.80-2.10			
	distal	male	2	1.75±0.49	1.40-2.10	1.00		
		female	2	1.60±0.14	1.50-1.70			
		total	4	1.67±0.30	1.40-2.10			
	central	male	54	0.41±0.21	0.10-1.00	0.43		
		female	63	0.38±0.19	0.00-1.00			
		total	117	0.39±0.20	0.00-1.00			

a: Men and Women Comparison

b: Comparison of Position

c: PM₁ and PM₂ Comparison

Table 4. The distance from MF to the anatomic apex in the mandibular premolars in both sides of the jaw based on gender

	Side	Tooth	Gender	Number	Mean±SD	Min-Max	pvalue ^a	pvalue ^b	pvalue ^b
distance from MF to the anatomic apex	right	Pm1	male	73	4.16±1.85	1.00-9.69			0.51
			female	88	4.45±1.99	1.40-13.80	0.47		
			total	161	4.31±1.93	1.00-13.80			
		Pm2	male	66	3.41±1.42	1.10-9.40		<0.001	
			female	91	3.43±1.62	0.50-9.00	0.71		
			total	157	3.42±1.53	1.50-9.40			
	left	Pm1	male	74	4.58±2.00	1.20-10.70			
			female	90	4.34±2.25	1.20-11.60	0.34		
			total	164	4.45±2.14	1.20-11.60		<0.001	
		Pm2	male	71	3.52±1.36	0.60-7.40			
			female	90	4.16±1.66	0.40-10.40	0.94		
			total	161	3.49±1.53	0.40-10.40			

Discussion

Often, the apex and AF are replaced with each other. However, the anatomic apex is the root end as identified morphologically, while the AF is the circumference or the rounded edge like a funnel or crater and does not necessarily coincide with the anatomical apex.^[3]

The current study suggested that the mean distance from AF to the anatomic apex of the premolars in the right quadrant compared to the premolars in the left quadrant had no difference in both genders (general comparison of premolars in the two sides of the jaw), but the mean distance from AF to the anatomic apex had significant difference between the first and second premolars in right quadrant so that it was significantly higher in the first premolar than the second one ($p=0.02$). The most number of double-canal premolars was related to the first premolar in the women. The mean distance from AF to anatomic apex of single-canal teeth was 0.56 mm, and the position of AF in 81% and 19% of these single-canal teeth was central and lateral, respectively. Yang et al. studied on 440 CBCT images of mandibular first premolars in a Chinese population and revealed that 66.14%, 22%, 1.14% and 0.68% of teeth were single-canal (single-rooted), double-canal, C-shaped and three-canal, respectively. the distance from the AF to the anatomic apex in single-canal and double-canal teeth was 0-2mm in most cases, whereas the distances 2-3 mm and 3-5 mm were found in a small number, and the results were the same on both sides of

the jaw and in both genders.^[4] Kuttler demonstrated that the AF does not completely coincide with anatomical apex. He selected 268 teeth from cadavers with 18-25 years, and 55 years and older. The distance from the AF to the anatomic apex in the first group and second group was 0.49 mm and 0.62 mm and deviation of the AF from the apex in the first and second groups was 68% and 80%, respectively.^[17]

Lagiseti determined the morphology of the apices of mandibular premolars using CBCT. Mean distance from the AF to the apex was 0.72mm, which are consistent with the results of the present study.^[18] The apical morphology of the anterior and posterior teeth was evaluated by Martos et al. using stereomicroscope and clearing technique. It was concluded that the mean distance from the AF to the anatomic apex was 0.69 mm in the anterior and posterior teeth together, but it was 0.87 mm in mandibular premolars, separately. The position of AF was at the apex end (central position) in 40% of cases. It was lateral in 60% of them; the highest was related to the buccal position of AF with 20%, followed by the distal position of AF with 12%.^[19] The distance from AF to apex of their study is close to that of the present study. Alkaabi et al. conducted a study on the mandibular first premolars using micro-computed tomography (micro-CT) in an Emirati population. It was found that the apical foramina were located centrally in 37.2, and in 62.8% they were located laterally^[20], which is inconsistent with the current study and this difference

can be due to the type of the study as well as the race. The incidence of the single-canal and single-rooted teeth in this study is similar to that in the studies of Cleghorn et al. and Khedmat et al. [16, 21] However, the incidence of the double-canal teeth is greater in the studies of Velmurugan et al, Awawdeh et al and Lu et al. than in the present study. [22-24]

The reason for this difference can be owing to differences in various races. Carruth et al evaluated the MF using CBCT showed that 53.7% of the mental foramina were located between the first and second premolars (mesial of the second premolar), 45.3% in distal apex of the second premolar and 1% below the apex of the second premolar, and the MF was closer to the second premolar. [25] In the current study, there was a significant difference in the mean distance from the MF to the anatomic apex between the first and second premolars of both sides of the jaw so that on both sides of the jaw, the MF was closer to the second premolar. The most common frequent position of the MF was between the first and second premolars so that 60.4%, 31.2%, 5.9% and 2.3% of them were located among the premolars, in line with the root of the second premolar, in line with the root of the first premolar and among the second premolars and first molars, respectively. The current study represented no significant difference between both sides of the jaw with respect to the position of MF ($p=0.59$ (ns) and between males and females in terms of gender ($p=0.53$ (ns).

In addition, similar to the present study Chen et al. using CBCT indicated that the most frequent position of the MF was located between the first and second premolars on both sides of the jaw and in both genders. In their study, the MF was located apically between the first and second premolars in 51.67% and in line with the root of the second premolar in 40.83% of the cases, and the mean distance of MF was closer to the second premolar. [26]

Haghanifar et al, Gada et al, Kumar et al, and Lopes et al. (using panoramic radiography) and Lopes (by studying the mandibles of dry cadavers) evaluated the MF and stated that the position of the MF was located

between the first and second premolars, which are the same as the findings of the present study. [27-30] Khojastepour et al. and Dabbaghi et al. determined the position of MF using CBCT and there was a slight difference between their study and the present study on the location and type of the MF. [31, 32] In those two studies, the most common position of the MF was below the apex of the second premolar. (In the study of Khojastepour, the position of MF was below the second premolars in 48.7% cases on the right side in both genders, and in 51.9% of cases was below the apex of the second premolar on the left side in both genders) and this slight difference can be because of the race [31] Other studies performed using panoramic radiography suggested that in different Iranian populations, the most common position of the MF was parallel to the second premolar, and this difference can be owing to type of the study and different Iranian race. [33-35]

Due to the possibility of lateral extrusion of canals in the mandibular premolars, there is a risk of file over and invasion to per radicular tissue. Therefore, the use of the auxiliary devices such as apex locator is useful.

Conclusion

Possibility of lateral extrusion of canals in the mandibular premolars, the use of the auxiliary devices such as apex locator is useful. According to different place of MF, its necessary to pay attention to this position during the periapical surgeries in the mandibular premolars, specially in second premolar.

Acknowledgments

The authors would like to thank the Research Deputy of Babol Medical Sciences University for financial support and educational administrators of Endodontics and Oral Maxillofacial Radiology Departments.

Funding: This study was a part of research project (Grant No: 9543223) which was supported and funded by Babol university of Medical Sciences.

Conflict of interest: We declare no Conflict of interest.

Author's Contributors

The study was designed by Azadeh Harandi. The study data were collected by Azadeh Harandi and Mehdi Akbarnezhad. Analysis and interpretation of data were conducted by Hemmat Gholinia and drafting of the manuscript and critical revision of the manuscript for important intellectual content were performed by Azadeh Harandi and Mehdi Akbarnezhad. Study supervision was conducted by Azadeh Harandi, and the adviser was Ehsan Moudi.

References

1. Abarca J, Zaror C, Monardes H, Hermosilla V, Munoz C, Cantin M. Morphology of the Physiological AF in Maxillary and Mandibular First Molars. *Int J Morphol* 2014;32:671-7.
2. Hassanien EE, Hashem A, Chalfin H. Histomorphometric study of the root apex of mandibular premolar teeth: an attempt to correlate working length measured with electronic and radiograph methods to various anatomic positions in the apical portion of the canal. *J Endod* 2008;34:408-12.
3. American Association of Endodontists .Glossary: contemporary terminology for endodontics. 5th ed. Chicago, Ill: American Association of Endodontists;1994.p.22.
4. Yang H, Tian C, Li G, Yang L, Han X, Wang Y. A cone-beam computed tomography study of the root canal morphology of mandibular first premolars and the location of root canal orifices and apical foramina in a Chinese subpopulation. *J Endod* 2013;39:435-8.
5. Ayranci LB, Yeter KY, Arslan H, Kseoğlu M. Morphology of apical foramen in permanent molars and premolars in a Turkish population. *Acta Odontol Scand* 2013;71:1043-9.
6. Neelakantan P, Subbarao C, Ahuja R, Subbarao CV, Gutmann JL. Cone-beam computed tomography study of root and canal morphology of maxillary first and second molars in an Indian population. *J Endod* 2010;36:1622-7.
7. Zoya-Farook A, Abhishek P, Shahabadi A. Cone-beam computed tomographic evaluation and endodontic management of a mandibular first premolar with type IX canal configuration: case report. *J Endod* 2017;43:1207-13.
8. Parekh V, Shah N, Joshi H. Root canal morphology and variations of mandibular premolars by clearing technique: an in vitro study. *J Contemp Dent Pract* 2011;12:318-21.
9. von Arx T, Friedli M, Sendi P, Lozanoff S, Bornstein MM. Location and dimensions of the mental foramen: a radiographic analysis by using cone-beam computed tomography. *J Endod* 2013;39:1522-8.
10. Moiseiwitsch JR. Avoiding the mental foramen during periapical surgery. *J Endod* 1995;21:340-2.
11. Moiseiwitsch JR. Position of the mental foramen in a north american, white population. *Oral Surg Oral Med Oral Pathol Oral Radiol Endod* 1998;85:457-60.
12. Loudon J. Beware the mental foramen. *Br Dent J* 2011;210:293.
13. Wu YC, Su CC, Tsai YC, Cheng WC, Chung MP, Chiang HS, et al. Complicated root canal configuration of mandibular first premolars is correlated with the presence of the distolingual root in mandibular first molars: a cone-beam computed tomographic study in taiwanese individuals. *J Endod* 2017;43:1064-71.
14. Aktekin M, Celik HM, Celik HH, Aldur MM, Aksit MD. Studies on the location of the mental foramen in Turkish mandibles. *Morphologie* 2003;87:17-9.
15. Liu N, Li X, Liu N, Ye L, An J, Nie X, et al. A micro-computed tomography study of the root canal morphology of the mandibular first premolar in a population from southwestern China. *Clin Oral Investig* 2013;17:999-1007.
16. Cleghorn BM, Christie WH, Dong CC. The root and root canal morphology of the human mandibular second premolar: a literature review. *J Endod* 2007;33:1031-7.
17. Kuttler Y. Microscopic investigation of root apices. *J Am Dent Assoc* 1955;50:544-52.

18. Lagiseti AK, Korath A, Hegde MN, Hegde P, Shetty A. Study of the apices of human mandibular premolar teeth With the use of cone-beam computed tomography. *Indian J Dent Res* 2015;4:216-8.
19. Martos J, Lubian C, Silveira LF, Suita de Castro LA, Ferrer Luque CM. Morphologic analysis of the root apex in human teeth. *J Endod* 2010;36:664-7.
20. Alkaabi W, AlShwaimi E, Farooq I, Goodis HE, Chogle SM. A micro-computed tomography study of the root canal morphology of mandibular first premolars in an Emirati population. *Med Princ Pract* 2017;26:118-24.
21. Khedmat S, Assadian H, Saravani AA. Root canal morphology of the mandibular first premolars in an Iranian population using cross-sections and radiography. *J Endod* 2010;36:214-7.
22. Velmurugan N, Sandhya R. Root form and canal morphology of mandibular premolars in a Jordanian population. *Int Endod J* 2009;42:54-8.
23. Awawdeh LA, Al-Qudah AA. Root form and canal morphology of mandibular premolars in a Jordanian population. *Int Endod J* 2008;41:240-8.
24. Lu TY, Yang SF, Pai SF. Complicated root canal morphology of mandibular first premolar in a Chinese population using the cross section method. *J Endod* 2006;32:932-6.
25. Carruth P, He J, Benson BW, Schneiderman ED. Analysis of the size and position of the mental foramen using the CS 9000 cone-beam computed tomographic unit. *J Endod* 2015;41:1032-6.
26. Chen Z, Chen D, Tang L, Wang F. Relationship between the position of the mental foramen and the anterior loop of the inferior alveolar nerve as determined by cone beam computed tomography combined with mimics. *J Comput Assist Tomogr* 2015;39:86-93.
27. Haghanifar S, Rokouei M. Radiographic evaluation of the mental foramen in a selected Iranian population. *Indian J Dent Res* 2009; 20:150.
28. Gada SK, Nagda SJ. Assessment of position and bilateral symmetry of occurrence of mental foramen in dentate asian population. *J Clin Diagn Res* 2014;8:203.
29. Kumar V, Hunsigi P, Kaipa BR, Reddy R, Ealla KK, Kumar CB, et al. Radiographic localization of mental foramen in northeast and south indian ethnic groups of indian population. *J Contemp Dent Pract* 2014;15:766-9.
30. Lopes P, Pereira G, Santos A. Location of the MF in dry mandibles of adult individuals in Southern Brazil. *J Morphol Sci* 2010; 27:23-5.
31. Khojastepour L, Mirbeigi S, Mirhadi S, Safaee A. Location of mental foramen in a selected iranain population: a cbct assessment. *Iran Endod J* 2015;10:117.
32. Dabbaghi A, Shams N, Yousefimanesh H, Robati M, Shams B, Salehi P, et al. Evaluation of mental foramen Position to First and Second Premolar and First Molar Teeth in Cone Beam Computed Tomography (CBCT). *Jundishapur Sci Med J* 2014; Suppl: 37-45. [In Persian]
33. Tafakhori Z, Karimi M. Evaluation Of horizontal position of mental foramen in relation to mandibular premolar in the panoramic radiograph in rafsanjan city in 2014. *J Rafsanjan Univ Med Sci Health Serv* 2016; 14:913-22. [In Persian]
34. Zamani Naser A, Hekmatian E, Rahmani L. Evaluation of horizontal position of mental foramina in the panoramic radiograph of patients referring to radiology department of Isfahan dental school. *J Isfahan Med Sch* 2011; 6:720-25. [In Persian]
35. Afkhami F, Haraji A, Boostani HR. Radiographic localization of the mental foramen and mandibular canal. *J Dent (Tehran)* 2013; 10:436.