

Full mouth rehabilitation with fixed prostheses in the case of unaligned and malpositioned implants: clinical report

Faezeh Atri¹, Ehsan Mohamadian Amiri^{2✉}

1. Assistant Professor, Department of Prosthodontics, Faculty of Dentistry, Tehran University of Medical Sciences, Tehran, IR Iran.
2. Assistant Professor, Department of Prosthodontics, Faculty of Dentistry, Babol University of Medical Sciences, Babol, IR Iran.

✉Corresponding Author: Ehsan Mohamadian Amiri, Faculty of Dentistry, Babol University of Medical Sciences, Babol, IR Iran.

Email: ehsan_mohamadian@yahoo.com

Tel: +98911 115 1715

Received: 5 Aug 2017 Accepted: 23 Sept 2017

Abstract

Full mouth rehabilitation with fixed implant supported prostheses is one of the challenging treatments, because important factors in aesthetic and function should be considered. Implants' alignments and locations should be planned before the insertion unless the improper inclination and location of implants would lead to difficulties in patient's comfort, oral hygiene problem and inability to reconstruct the acceptable functional and aesthetical prosthesis.

This clinical report described the step by step prosthetic treatment procedure of full mouth rehabilitation and 1-year follow-up of a patient who underwent 10 and 8 implants in upper and lower jaw respectively, which were unaligned and malpositioned. In the cases of improper alignment and position of implants, modified prosthetic design with consideration of biomechanical principles should be incorporated to overcome the limitations.

Keywords: Dental prosthesis, Rehabilitation, Dental implants

Citation for article: Atri F, Mohamadian Amiri E. Full mouth rehabilitation with fixed prostheses in case of unaligned and malpositioned implants: clinical report. Caspian J Dent Res 2017; 6: 53-7.

بازسازی کامل دهان با پروتز ثابت در بیماری با ایمپلنت های با زوایا و موقعیت های نامناسب: گزارش بالینی

فائزه عطری، احسان محمدیان امیری*

چکیده

بازسازی کامل دهان با پروتزهای ثابت متکی بر ایمپلنت یکی از درمان های چالش برانگیز است، زیرا که فاکتورهای مهمی در زمینه زیبایی و فانکشن باید در نظر گرفته شود. موقعیت و زوایای ایمپلنت ها باید از قبل از جراحی طرح ریزی شود، در غیر این صورت محل و تمایل های نامناسب موجب بروز مشکلاتی در راحتی بیمار، دشواری رعایت بهداشت و سختی در ساخت پروتز با زیبایی و فانکشن مناسب می شود.

در این گزارش کلینیکی مراحل گام به گام بازسازی پروتزی کامل و یک سال فالو آپ بیماری با ۱۰ ایمپلنت در فک بالا و ۸ ایمپلنت در فک پایین با موقعیت و زوایای نامناسب توضیح داده می شود. در شرایط نامناسب بودن محل و تمایل های ایمپلنت، تغییراتی در مراحل درمان پروتزی با توجه به اصول بیومکانیک لازم است که بتواند محدودیت ها را برطرف کند.

واژگان کلیدی: پروتز دندان، بازسازی، ایمپلنت های دندان

Introduction

Complete edentulism has some complications like poor aesthetics, difficulty in chewing and functional problems. Some patients do not accept the conventional treatment of complete denture and severe resorption of alveolar bone reduces the success and; therefore, recently the gold standard for treatment of edentulism has become implant-supported overdenture. [1] Fixed implant-supported rehabilitation is an ideal treatment option with high success rate. [2] For lower post-operative complication and higher satisfaction of the patient and clinician, the treatment steps should be planned exactly and the implants should be placed according to this plan. [3] Improper inclination and location of implants would lead to difficulties in fabrication of an ideal prosthesis, patient's comfort, oral hygiene, mechanical and aesthetic problems.

The aim of this paper was to report the treatment steps of a full-mouth implant supported fixed prostheses of a fully edentulous patient who underwent surgical insertion of 10 and 8 implants in upper and lower jaws, respectively with improper inclination and location.

Case report

A 63-year-old Iranian women was referred to the Prosthodontics Department in order to rehabilitate the fully edentulous maxilla and mandible with implant-supported fixed prosthesis. Her medical history was

clear and she had missed all her teeth because of car accident and caries. She received 18 implants (XiVE® Screw Implant) in upper and lower jaws after extensive bilateral alveolar nerve reposition and sinus lift. After healing period of 9 months, osseointegration was checked using percussion and reverse torque tests. [4] In primary examination, the location of mandibular implants was so buccally, and the location of maxillary implants was palatally with divergent angles. The worse location of implant was maxillary canine, which was inserted in labial vestibule (Fig 1). The final impression was taken with pick up impression copings in splinted fixture-level method by using polyvinyl siloxane impression material. [5] Studies have shown that the splinted open tray impression technique is more accurate for completely edentulous patients. [6] In this case, divergent implants angulations resulted in tray removal difficulty and so, the accuracy of impression should be verified before any further step. After pouring the master casts, impression verification jig was fabricated and tried in the mouth. Jaw relations were recorded. After mounting, tooth set up was checked for esthetics, labial support, vertical dimension and centric relations and silicon index was made to gain the same contour for final prosthesis.

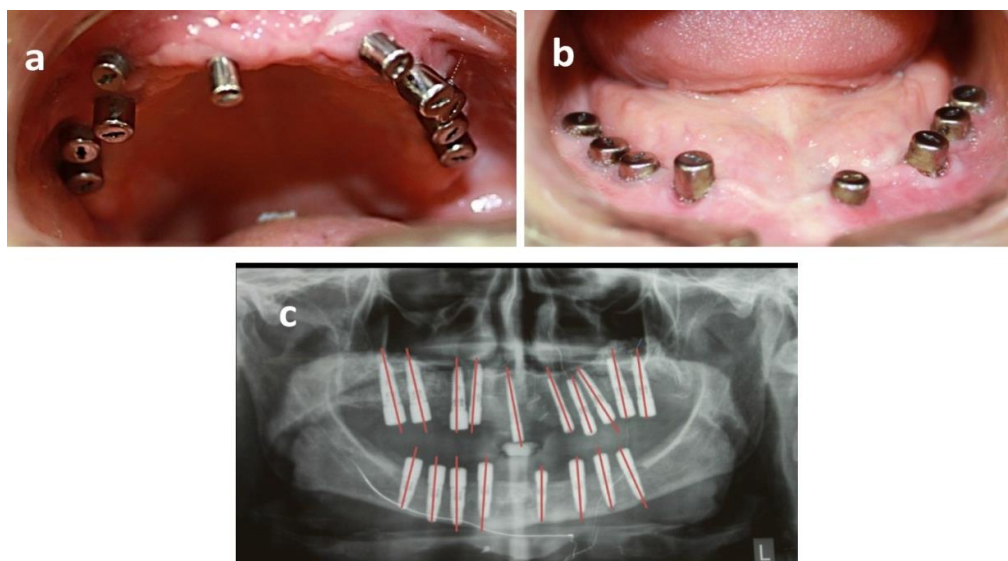


Fig1. Pre-prosthetic examination: a) maxillary view b) mandibular view c) radiographic view

Abutments were selected after evaluating the vertical and horizontal space. The available inter arch space was relatively high and FP3 prosthesis was indicated.^[7]

Degree of abutment angulation was selected in accordance with the esthetic requirements and the path

of insertion of the cement-retaining prosthesis based on set up index. All the abutments were chosen from Implant Company except maxillary right canine implant and because of its high angulation, the UCLA castable type was used to correct the implant angulation and inclination.^[8] (Fig 2)




Fig 2. Selected abutments on the articulator (notice right maxillary canine)

Then, the prosthesis was designed in three section in lower jaw according to Misch treatment option 5 to avoid mandibular deflection effect.^[7] The maxillary prosthesis was designed in four sections owing to fixtures angulations and disability of making one single

path of insertions for whole prosthesis. Resin pattern of implant frameworks was fabricated according to index and tried intraorally for checking of impression accuracy and framework design. (Fig 3)

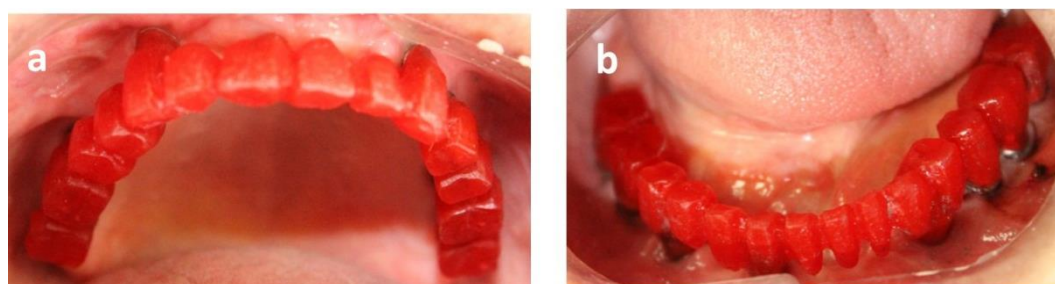


Fig 3. Intraoral view of resin framework try-in: a) maxillary view b) mandibular view

Then, cobalt chromium frameworks were fabricated by conventional lost wax method. Frame trial was carried out in patient's mouth for passive fitness and the marginal accuracy was checked using parallel radiography. In the porcelain try-in stage, the occlusion of the prosthesis was adjusted to achieve the

simultaneous centric relation contacts and canine-protected occlusion.^[7] After tightening the screws with the recommended torque, the prosthesis was delivered with temporary cement. Baseline radiography was captured as document for future follow up and comparison. (Fig 4) The patient was followed at 1, 6 and 12 months post-delivery.

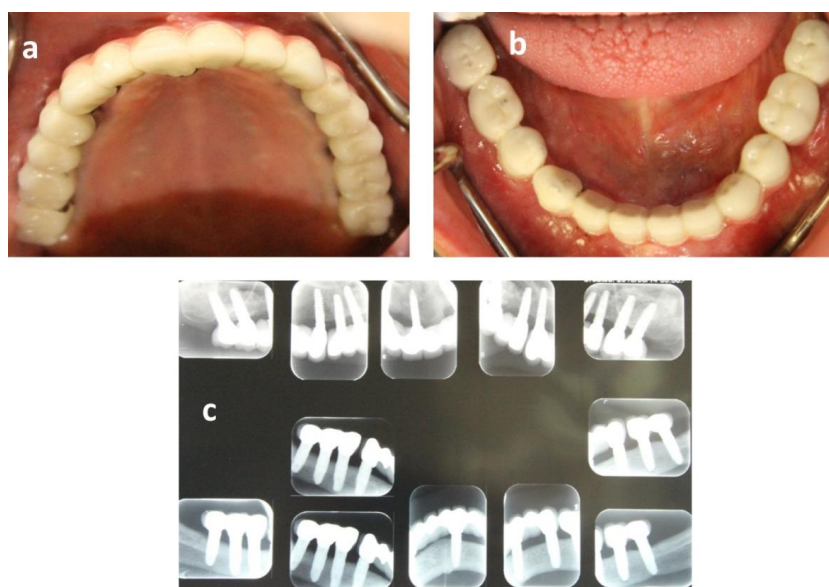


Fig 4. Post treatment documents: a) maxillary view b) mandibular view c) radiographic view

Discussion

In case of full mouth rehabilitation with implant supported fixed prosthesis, the exact planning of the treatment steps and designing of the final prosthesis are mandatory. The concept of prosthesis-directed implant-supported restoration with ideal implant location would optimize the prosthetic procedure and outcome.^[9] Surgical guide is strongly recommended. In the present case, this important step was missed, which led to an inappropriate insertion of implants out of the neutral zone, difficulty in paralleling of abutments and non-axial loading of fixtures. Malpositioned implants are associated with mechanical and esthetic problems.

Mechanical problems due to unfavorable position of restorations, increase probability of component fracture, screw loosening and implant pillar failure. Esthetic problems include soft and hard tissue volume insufficiency and improper restoration contour.^[10]

Malpositioned implants are considered as failure with incidence rate of more than 10%.^[11] Positional failures are associated with difficulty in prosthetic treatment and abutment selection. In severe cases, the relocation of the malpositioned fixture by segmental osteotomies or surgical removal of fixture, grafting and a second implant placement is recommended. In single implant beside natural teeth, re-submerging of

osseointegrated implant and fixed dental prosthesis is also considered. In mild to moderate misalignment, implants could be restored with prefabricated angulated abutments, customized abutment and UCLA type.^[12] Prefabricated angulated abutments compensate angulation from 17 to 35 degree.

They have accurate connection and provide precise fitness. Customized abutments are manually formed in favorite direction but the thickness of restoration is increased. In the case of screw restoration, sometimes screw access hole comes out in buccal and it should be masked by aesthetic direct restoration or veneer porcelain. In the case of cemented restoration, over-contouring is a common problem.^[13]

In this patient, maxillary right canine fixture had angulation more than 45 degree and a customized cast abutment was designed with an UCLA plastic type abutment and other angulated implants were restored with prefabricated angled abutments. All the crowns were cemented and there was no problem on screw hole covering.

Another important issue, in these cases, is to control the stress distribution. Loads are enhanced with steeper cusp inclination and broader occlusal table. It is advocated that occlusal table should be narrow, with axial loading in central fossa in centric contact, and low cusp inclination should be minimized the lateral loading in ex-centric movements. Mutually protected occlusion would reduce loading, too.^[14] As a final point, oral hygiene instruction and periodic recall are key factors of long-term success.

Author's contributions

The study was designed by Faezeh Atri and Ehsan Mohamadian Amiri. Data were collected by Faezeh Atri. Results were evaluated by Faezeh Atri and Ehsan Mohamadian Amiri. Supervision of the study was performed by Faezeh Atri.

References

1. Zarb GA, Hobkirk J, Eckert S, Jacob R. Prosthodontic Treatment for Edentulous Patients: Complete Dentures and Implant-Supported Prostheses. 13th ed. Missouri:Elsevier Health Sciences; 2013.p.1-27 .
2. Rajgiri SU, Dayalan M. Full-mouth. Rehabilitation with implant-supported fixed Prosthesis. *Int J Oral Implantol Clin Res* 2016;7:73-80.
3. Çötört HS, Zeytinoglu B, Zeytinoglu M. Mock-Up Driven Designing of Full-Mouth Implant-Supported Metal-ceramic Fixed Prostheses. *Dentistry* 2014;4:1.
4. Atri F, Zarati SK. Early loading implant failure of congenitally missing maxillary lateral incisor after orthodontic space opening: A case report. *J Craniomax Res* 2017; 4:324-7.
5. Papaspyridakos P, Chen CJ, Gallucci GO, Doukoudakis A, Weber HP, Chronopoulos V. Accuracy of implant impressions for partially and completely edentulous patients: a systematic review. *Int J Oral Maxillofac Implants* 2014;29:836-45.
6. Lee H, So JS, Hochstedler JL, Ercoli C. The accuracy of implant impressions: a systematic review. *J Prosthet Dent* 2008;100:285-91.
7. Misch CE. Dental implant prosthetics. 2nd ed. St. Louis, Missouri: Elsevier Mosby; 2015.p. 874-911.
8. Montero J, Manzano G, Beltrán D, Lynch CD, Suárez-García MJ, Castillo-Oyagüe R. Clinical evaluation of the incidence of prosthetic complications in implant crowns constructed with UCLA castable abutments: a cohort follow-up study. *J Dent* 2012; 40:1081-9.
9. Ellis E 3rd, McFadden D. The value of a diagnostic setup for full fixed maxillary implant prosthetics. *J Oral Maxillofac Surg* 2007; 65: 1764-71.
10. Froum SJ, editor. Dental implant complications: etiology, prevention, and treatment.2nd ed. Hoboken, New Jersey: John Wiley & Sons; 2015. p. 711-30.
11. Chee W, Jivraj S. Failures in implant dentistry. *Br Dent J* 2007;10:123.
12. Chatterjee A, Ragher M, Patil S, Chatterjee D, Dandekeri S, Prabhu V. Prosthetic management of malpositioned implant using custom cast abutment. *J Pharm Bioallied Sci* 2015; 7(Suppl 2):S740.
13. Pigliacelli S. Correcting malpositioned dental implants: Where do we go from here? *Perio-Implant Advisory* [Internet]. 2016 [cited 5 September 2017] Available from: <http://www.perioimplantadvisory.com/articles/2016/03/correcting-malpositioned-dental-implants-where-do-we-go-from-here.html>.
14. Klineberg IJ, Trulsson M, Murray GM. Occlusion on implants - is there a problem. *J Oral Rehabil* 2012; 39:522-37.