

Plexiform schwannoma of the floor of the mouth: a case report

Mohammad Koochek Dezfuli¹, Maryam Seyedmajidi², Shabnam Sohanian^{1✉},
Hamed Hossein Kazemi³, Khashayar Dehshiri⁴

1. Postgraduate Student, Department of Oral & Maxillofacial Pathology, Faculty of Dentistry, Babol University of Medical Sciences, Babol, Iran.
2. Associate Professor, Dental Materials Research Center, Faculty of Dentistry, Babol University of Medical Sciences, Babol, Iran.
3. Assistant Professor, Department of Oral Medicine, Faculty of Dentistry, Babol University of Medical Sciences, Babol, Iran.
4. Postgraduate Student, Department of Oral and Maxillofacial Surgery, Faculty of Dentistry, Babol University of Medical Sciences, Babol, Iran.

✉Corresponding Author: Shabnam Sohanian, Faculty of Dentistry, Babol University of Medical Sciences, Babol, Iran.

Email: shabnam.sohanian@gmail.com

Tel: +981132199592

Received : 29 Jan 2017

Accepted: 13 Mar 2017

Abstract

Plexiform schwannoma is a type of schwannoma that can be occurred at any age and any site of the oral cavity. In the gross and histopathological features, it shows plexiform or multinodular growth pattern. This variant of schwannoma is sometimes associated with neurofibromatosis type II or schwannomatosis. Histopathologically, plexiform schwannoma is composed of schwann cells that show Antoni A growth pattern. Mitosis are rare or absent. This study reports a case of a healthy 34 year old female with swelling in floor of her mouth; according to the clinical and histopathological findings, the diagnosis was Plexiform schwannoma.

Keywords: Schwannomatosis, Plexiform, Neurofibromatosis type 2, Schwannoma

Citation for article: koochek Dezfuli M, Seyedmajidi M, Sohanian S, Hossein Kazemi H, Dehshiri K. Plexiform schwannoma of the floor of the mouth: a case report. Caspian J Dent Res 2017; 6:49-53.

شوانومای پلکسی فرم در کف دهان: گزارش مورد

محمد کوچک دزفولی، مریم سید مجیدی، شبنم سوهانیان*، حامد حسین کاظمی، خشایار دهشیری

چکیده

شوانومای پلکسی فرم واریانته از شوانوماست که در هر سنی و هر ناحیه ای از حفره دهان امکان مشاهده آن وجود دارد. این واریانت شوانوما از نظر نمای gross و هیستوپاتولوژی الگوی رشدی پلکسی فرم یا مولتی ندولار نشان داده و گاهی در ارتباط با نور فیبرو ماتوزیس تیپ II و یا شوانوماتوزیس دیده میشود. از لحاظ هیستوپاتولوژیکی، شوانومای پلکسی فرم از سلولهای شوان تشکیل شده که الگوی آنتونی A نشان می دهند. میتوز نادر بوده و یا این که اصلاً دیده نمی شود. این مطالعه به گزارش موردی در خانم ۳۴ ساله ی سالم با شکایت از تورم کف دهان می پردازد که بر اساس یافته های بالینی و هیستوپاتولوژیک برای این ضایعه، تشخیص شوانومای پلکسی فرم داده شد.

واژگان کلیدی: شوانوماتوزیس، پلکسی فرم، نورفیبروماتوزیس تیپ ۲، شوانومای

Introduction

Schwannoma or neurilemoma is a benign neoplasm with neural origin derived from schwann cells. Head and neck involvement of this neoplasm is 25-48% and can appear at any age, although the most common site of involvement is the oral cavity, it may be seen in any area of the oral cavity.^[1-3] Histopathologically, there are various types of schwannomas including cellular schwannoma, plexiform schwannoma and reticular (microcytic) schwannoma.^[4] Cellular schwannoma mainly consists of spindle cells arranged in storiform or nonspecific pattern. In microcytic variant, cystic structure can be seen. Plexiform schwannoma is rare variant of schwannoma, introduced by Harkin and Redd for the first time in 1978^[5] and in the gross and histopathological feature, it shows plexiform or multinodular growth pattern.^[1, 4, 5, 6] This variant of schwannoma is sometimes associated with neurofibromatosis type II (NF₂) or schwannomatosis^[4, 7] and in terms of histopathology, plexiform schwannoma which shows Anthony A growth pattern is composed of schwann cells. Mitosis is rare or absent. Like all types of schwannoma, this tumor is positive for S100 protein. EMA is positive around perineurium briefly.^[8] The purpose of this paper was to introduce plexiform schwannoma in oral cavity of a patient with no particular syndrome and this was very significant.

Case report

A 34-year-old female patient with swelling in the floor of the mouth referred to the Oral Medicine Department of Babol University of Medical Sciences. This lesion has been appeared in the floor of the mouth four years ago and its size has gradually increased. In intraoral examination, there was an exophytic mass which was sessile and covered with intact mucosa with the same color. It was 1/5×1×0/5 cm³ lesion in the floor of the mouth on the left side of the midline (figure1). The patient did not have any disorders in submandibular gland. The patient had no marked medical history, but a history of rheumatism.

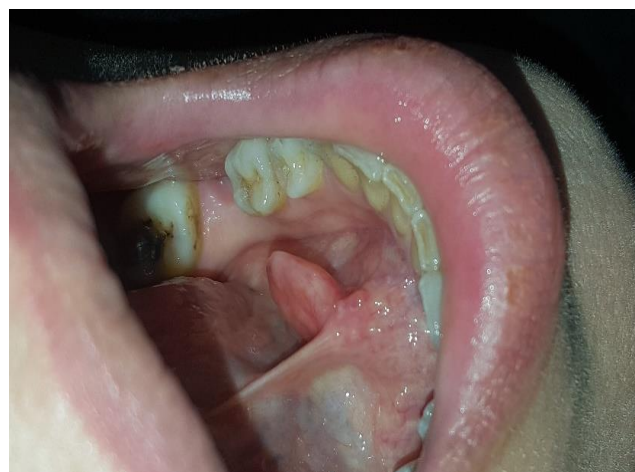

Figure 1. Clinical feature

The excisional biopsy was done and fibroma, neurofibroma and lipoma were considered as clinical differential diagnosis. The sample in formalin included a half oval-shaped soft tissue which was firm and white-creamy in color. The size was $1/2 \times 1 \times 0/2 \text{ cm}^3$ that was solid, uniform, cream-colored and lobular in section. In the microscopic examination, benign neoplastic

proliferation of schwann cells that formed multiple neurological fascicles was observed. Fascicles have spherical and elliptical structures with storiform pattern. The lesion was unencapsulated but limited and its surface was covered by stratified squamous epithelium of oral mucosa (figure 2). According to the histopathologic view, the diagnosis was plexiform schwannoma.

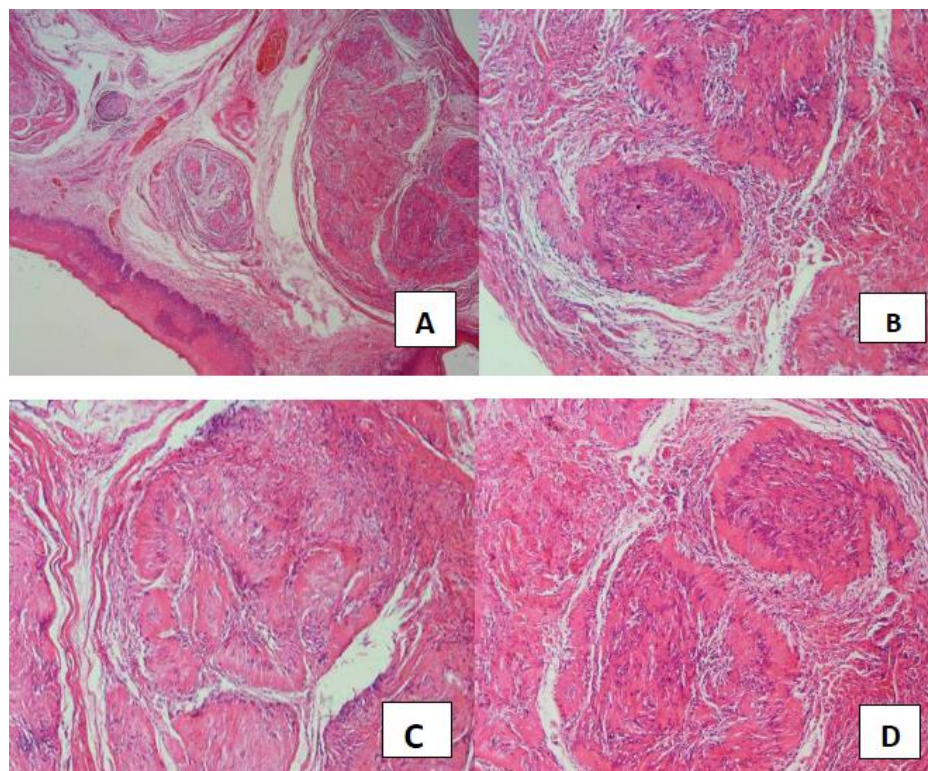


Figure 2. Histopathologic feature, A-multiple neurological fascicle in storiform pattern were covered by stratified squamous epithelium ($\times 10$), B-Fascicles had spherical and elliptical structures ($\times 400$), C and D-Antoni A pattern ($\times 400$)

Discussion

Schwannoma or neurilemoma is a benign neoplasm with neural origin derived from schwann cells. This is an encapsulated slow-growing tumor that is usually associated with nerve trunk and appeared as an asymptomatic mass at any age. The most common site for oral schwannoma is the tongue, but it may involve any area of the oral cavity. There are also more intraosseous cases seen in the posterior part of the mandible and in radiography, it is observed as unilocular or multilocular radiolucency. Intraosseous tumors have pain and paresthesia.^[1-3] Schwannoma may be a part of an inherited disorder, called neurofibromatosis type II (NF₂). NF₂ is an autosomal

dominant inherited disorder related to the mutations in the NF₂, which is tumor suppressor gene located on the chromosome 22 and produces Merlin protein. It is necessary to mention that the bilateral vestibular nerve schwannoma, progressive sensorineural deafness, dizziness, tinnitus as symptoms of this genetic disorder. Neurofibroma and café-au-lait pigmentations are sometimes seen. Schwannomatosis is another disorder which is associated with the mutation of SMARCB1 on chromosome 22. One of the characteristics of this disorder is multiple painful schwannomas in different areas, but there is not auditory nerve vestibular involvement.^[1] Microscopic feature of schwannoma is

an encapsulated tumor with two types of growth patterns. Antoni A pattern includes the areas of spindle cells organized in palisaded whorls and waves. These cells often surround an acellular eosinophilic zone which is named Verocay body, representing reduplicated basement membrane and cytoplasmic cellular processes. The other pattern is the so-called Antoni B tissue, consisting of spindle cells haphazardly distributed in a delicate fibrillar microcystic matrix.^[1-3] Microscopically, schwannoma is divided into cellular schwannoma, plexiform and reticular (microcystic) types.^[4] Plexiform schwannoma is a variant of schwannoma, occurred at any age, but usually involves younger people. Grossly and microscopically, it indicates plexiform or multi-nodular growth pattern.^[4,5] This variant of schwannomas may sometimes associate with neurofibromatosis type II (Nf2) or schwannomatosis.^[1, 4, 5, 8] Histopathologically, plexiform schwannoma which shows Antoni A pattern is composed of schwann cells. Few mitosis is usually seen or may not exist at all. Like the other types of schwannoma, this tumor is positive for S100 protein. EMA is positive around Perineurium briefly.^[4] Rare cases of this type are observed in the literature review.

Nisa et al. reported a 38-year-old female with 20-year history of a slow-growing tumor on her tongue. There was a family history of hypothyroidism and evaluations of the patient confirmed Hashimoto's disease. In histopathological examination of the lesion, ladder-shaped bundles of positive S100 cells and the diagnosis of plexiform schwannoma were reported.^[9]

Val-Bernal et al. reported a 19 year-old woman who had a plexiform schwannoma on the preauricular region. The patient had 6 café-au-lait pigmentations on her body and MRI evaluation indicated bilateral tumors on the auditory nerve, which were schwannomas. The patient also had other masses in the spinal cord and large wing of sphenoid that were the signs of neurofibromatosis type II.^[10]

In the study of Ali et al two cases of plexiform schwannoma were reported. First patient was a 15-year-old boy with swelling in his right cheek which clearly created facial asymmetry. In intraoral examination, 5 cm palpable swelling was observed in buccal mucosa.^[5] MRI evaluation of the patient showed no aggression to maxillary area, orbit, mandible, oropharynx, nasal cavity and surrounding muscles. In the histopathological feature, plexiform schwannoma was diagnosed. The patient had no signs of recurrence after a year and remodeling of the nasomaxillary complex was satisfactory. The second patient was a 46-year-old man with a long-term swelling on the tongue, which had slow and asymptomatic growth. The patient has no disease or syndrome. For the differential diagnosis, granular cell tumor or mucocele was considered, but after histopathological evaluation, a plexiform schwannoma was reported.^[4] Totally, 57 cases of plexiform schwannoma have been reported in PubMed articles in the whole body, of which 10 cases have been intraorally occurred and our case is the only one which has ever seen in the floor of the mouth since 1994 up to present (Table 1)

Table 1. Intraoral plexiform schwannoma reported in PubMed since 1994

No.	Author	Year	Location	Sex	Age
1	Krolls et al ¹¹	1994	Hard palate	Female	21
2	Lobo et al ¹²	2009	Lip mucosa	-----	---
3	Vera-Sempere et al ¹³	2010	Mandible	-----	---
4	Nisa et al ⁹	2011	Tongue	Female	38
5	Kapetanakis et al ¹⁴	2012	Soft palate	Female	21
6	Al-Mahdi et al ¹⁵	2012	Tongue and mandibular region	-----	27
7	Lambado et al ⁶	2013	Intramaxillary	-----	---
8	Couto et al ¹⁷	2014	Hard palate	Female	14
9	Ali et al ⁵	2014	Buccal mucosa	Male	15
10	Ali et al ⁵	2014	Tongue	Male	46
11	Present case	2017	Floor of the mouth	Female	34

Malignant peripheral nerve sheath tumor, palisaded encapsulated neuroma, plexiform neurofibroma, lipoma, hemangioma, eosinophilic granuloma, epidermoid and dermoid cysts, epithelial hyperplasia, granular cell tumor, benign tumors of the salivary glands, rhabdomyoma, leiomyoma, lingual thyroid, mucocele and lymphangioma were considered as differential diagnosis of plexiform schwannoma in several studies. [4, 5, 9] MPNSTs have mitotic activity and metastasis. PEN contains axons that can be seen by silver staining. Plexiform neurofibromas are less cellular, less S100 immunoreactive and have a mucin-rich matrix. [4] Plexiform schwannoma can be easily differentiated from the other lesions mentioned above by the microscopic and immunohistochemical studies.

In some cases, the malignant processes of cancer such as squamous cell carcinoma and sarcoma show similar clinical features [5, 8] and in these cases the accurate diagnosis is crucial, because plexiform schwannoma has a benign process and is treated by an excisional surgery. [5]

References

1. Neville BW, Dam DD, Allen CM, Bouquot JE. Oral and maxillofacial pathology. 3rd ed. Philadelphia: WB. Saunders; 2016.p.492.
2. Regezi J, Sciubba JJ, Jordan RC. Oral pathology: clinical pathologic correlations. 7th ed. St.louis, Mo: Elsevier/Saunders;2017.p.176.
3. Gnepp Douglas R. editor. Diagnostic surgical pathology of the head and neck .2nd ed. Philadelphia, PA: Saunders/Elsevier; 2009.p.245-6.
4. Kurtkaya-Yapicier O, Scheithauer B, Woodruff JM.The pathobiologic spectrum of Schwannomas, Histol Histopathol 2003;18: 925-34.
5. Ali S, Vassiliou L, Stenhouse P. Plexiform schwannoma: a report of two unusual cases, and a review of the literature. Open J Stomatol 2014; 4: 174-8.
6. Lambade PN, Lambade D, Saha TK, Dolas RS,Dhobley A. Unusual intramaxillary plexiform schwannoma .Oral Maxillofac Surg 2013;17: 137-40.
7. Agaram NP, Prakash S, Antonescu CR. Deep-seated plexiform schwannoma: a pathologic study of 16 cases and comparative analysis with the superficial variety. Am J Surg Pathol 2005;29:1042-8.
8. Berg JC, Scheithauer BW, Spinner RJ, Allen CM, Koutlas IG. Plexiform schwannoma: a clinicopathologic overview with emphasis on the head and neck region. Hum Pathol 2008;5:633–40.
9. Nisa L, von Büren T, Tiab A, Giger R.Giant Plexiform Schwannoma of the Tongue. Case Rep Otolaryngol 2011; 2011:1-3.
- 10.Val-Bernal JF, Figols J, Vázquez-Barquero A. Cutaneous plexiform schwannoma associated with neurofibromatosis type 2.Cancer 1995;76:1181-6.