

A comparative study on the mast cells count in oral squamous cell carcinoma and normal oral mucosa

Mahsa Dastpak¹, Shima Nafarzadeh(DDS)^{2✉}, Soraya Khafri(PhD)³

1. Dental Student, Student Research Committee, Faculty of Dentistry, Babol University of Medical Sciences, Babol-Iran.
2. Assistant Professor, Department of Oral and Maxillofacial Pathology, Faculty of Dentistry, Babol University of Medical Sciences, Babol- Iran.
3. Assistant Professor, Department of Social Medicine and Health, Faculty of Medicine, Babol University of Medical Sciences, Babol-Iran.

✉**Corresponding Author:** Shima Nafarzadeh, Faculty of Dentistry, Babol University of Medical Sciences, Babol- Iran.

Email: shima_nafar2004@yahoo.com

Tel: +989113259433

Received: 3 June 2014

Accepted: 17 Dec 2014

Abstract

Introduction: Oral squamous cell carcinoma (OSCC) is one of the 10 most common malignant tumors and SCC accounts 94% of all oral malignancies. Mast cells are regarded as complex and multifunctional cells, playing a significant role in immunopathology. The aim of this study is to evaluate the number of mast cells in tissue sections of oral squamous cell carcinoma (OSCC) in comparison with normal mucosa.

Materials & Methods: Sixty paraffin-embedded specimens were obtained from the archives of the Department of Oral and Maxillofacial Pathology, dental school of Babol university of medical science (15 high grade, 15 low grade and 30 Irritation Fibroma). Classification of OSCC cases was according to the BRODER'S malignancy grading system. Hematoxylin and Eosin-stained slides were re-evaluated before entering the samples in our study. Toluidine blue (1%) staining was used to identify Mast cells in samples. We used SPSS software version 18 and one way ANOVA test for analyzing data.

Results: The highest mast cell count was seen in normal tissue and it was higher in low grade OSCC in comparison with high grade, but the differences between groups weren't statistically significant. The Mean count of mast cell between OSCC and normal oral mucosa was statistically significant different ($p=0.019$). We didn't observe any statistically significant difference between Mast cell counts of control group and low grade OSCC. The same result was seen between high grade and low grade OSCC. The Mean mast cell count difference between male and female groups weren't statistically significant. The Mean mast cell count difference between high grade OSCC and control group was significant ($p<0.05$).

Conclusion: According to the results, the average amount of mast cells decreased in OSCC in comparison with normal oral mucosa. It does not seem that mast cells play an important role in tumor progression, although further study is needed.

Keywords: Squamous cell carcinoma, Mast cell, Toluidine blue

Citation for article: Dastpak M, Nafarzadeh S, Khafri S. A comparative study on the mast cells count in oral squamous cell carcinoma and normal oral mucosa. *Caspian J Dent Res* 2015; 4: 17-22.

بررسی مقایسه‌ای تعداد ماست سل‌ها در کارسینوم سلول سنگفرشی دهانی و مخاط نرمال دهان

مهسا دست‌پاک، شیما نفرزاده*، ثریا خفری

چکیده

مقدمه: کارسینوم سلول سنگفرشی دهانی یکی از ۱۰ تومور بدخیم شایع می‌باشد که ۹۴ درصد از بدخیمی‌های حفره دهان را شامل می‌گردد. ماست سل‌ها به سلول‌های چندکاره‌ای اطلاق می‌گردند که نقش مهمی در ایمنوپاتولوژی و تومورژنیز دارند. هدف از این مطالعه بررسی مقایسه‌ای تعداد ماست سل‌ها در کارسینوم سلول سنگفرشی دهانی و مخاط نرمال دهان می‌باشد.

مواد و روش‌ها: ۶۰ بلوک پارافینه موجود در آرشیو بخش آسیب‌شناسی دهان، فک و صورت دانشکده دندانپزشکی دانشگاه علوم پزشکی بابل مورد بررسی قرار گرفت (۱۵ عدد گرید بالا، ۱۵ عدد گرید پایین، ۳۰ عدد فیبروم تحریکی). طبقه‌بندی نمونه‌های کارسینوم سلول سنگفرشی دهانی بر اساس BRODER`malignancy grading system انجام شد. بررسی مجدد نمونه‌های رنگ آمیزی شده بوسیله هماتوکسیلین - ائوزین قبل از ورود نمونه‌ها به مطالعه انجام شد. از رنگ آمیزی تولوئیدین بلو جهت تشخیص ماست سل در نمونه‌ها استفاده شد. از نرم افزار SPSS 18 و تست one way ANOVA جهت آنالیز داده‌ها استفاده کردیم.

یافته‌ها: بیشترین تعداد ماست سل‌ها در مخاط نرمال دهان دیده شد. تعداد ماست سل‌ها در کارسینوم سلول سنگفرشی دهانی گرید پایین نسبت به گرید بالا بیشتر بود. اما اختلاف بین گروه‌ها از لحاظ آماری معنادار نبود. میانگین تعداد ماست سل‌ها بین کارسینوم سلول سنگفرشی دهانی و مخاط نرمال دهان از لحاظ آماری به طور معناداری متفاوت بود ($p=0.019$). ما هیچ تفاوت آماری معناداری در تعداد ماست سل‌ها بین گروه کنترل و کارسینوم سلول سنگفرشی دهانی گرید پایین مشاهده نکردیم. نتایج مشابه بین کارسینوم سلول سنگفرشی دهانی گرید بالا و پایین مشاهده شد. تفاوت میانگین تعداد ماست سل‌ها بین دو گروه مذکور و مونث از نظر آماری معنادار نبود. تفاوت میانگین تعداد ماست سل‌ها بین کارسینوم سلول سنگفرشی دهانی گرید بالا و گروه کنترل معنادار بوده است. ($p<0.05$)

نتیجه‌گیری: با توجه به نتایج به دست آمده میانگین تعداد ماست سل‌ها در کارسینوم سلول سنگفرشی دهانی در مقایسه با مخاط نرمال دهان کاهش پیدا کرد. به نظر می‌رسد که ماست سل‌ها نقش مهمی در پیشرفت تومور ایفا کنند. که مطالعات بیشتری را در این زمینه می‌طلبد.

واژگان کلیدی: کارسینوم سلول سنگفرشی، ماست سل، تولوئیدین بلو

Introduction

Oral squamous cell carcinoma (OSCC) remains a serious problem of oral cavity worldwide.^[1] OSCC has a complex biological behavior and despite the advances in the treatment modalities, the 5-year survival rates of the patients with oral squamous cell carcinoma have improved only slightly. This has led to an interest in predicting its possible future behavior, so alternative therapeutic strategies can be used to treat the severity of the tumor.^[2-4] Mast cells are inflammatory cells which are found in the normal connective tissue.^[5] Mast cells are well known to be

involved in allergic, inflammatory, and immune reactions. In addition, they are also involved in pain, tissue damage as well as repair. However, in the recent past, mast cells abound in intense peritumoral inflammation that often surrounds aggressive cancers, including melanoma, breast carcinoma and colorectal adenocarcinoma.^[6] Mast cells have been implicated in conferring the angiogenic activity in pre-malignant lesions, and contributing to neovascularization during squamous epithelial carcinogenesis.^[7] The effects of mast cells on carcinogenesis are likely to be mediated through multiple pathways, including immunosuppression, enhancement of angiogenesis,

disruption of the extracellular matrix, and promotion of tumor cell mitosis.^[8] An increased mast cell count may be the result of tumor invasiveness; on the other hand, these mast cells may elicit tumor progression.^[9] Recent data suggests that mast cells may play opposing roles in tumor biology and that the microenvironment may polarize these cells to render either a promoting or inhibiting effect on tumors.^[8,10] Some studies suggest the pro-angiogenic and thus pro-tumorogenic role of mast cells in OSCC, whereas some studies do not support this theory.^[8,10,11-13] In this study, we investigated mast cell counts in OSCC and normal oral mucosa by using toluidine blue staining method.

Methods

Sixty paraffin-embedded specimens were obtained from the archive of the Department of Oral and Maxillofacial Pathology, Babol dental school. They included Irritation Fibroma samples (n=30) as control group, high grade OSCC (n=15), low grade OSCC (n=15). Classification of OSCC cases was according to the BRODER'S malignancy grading system.^[14] In order to confirm the diagnosis, Hematoxylin and Eosin-stained slides were re-evaluated before entering the samples in our study.

Toluidine blue staining assay: Toluidine blue staining was performed with a 1% Toluidine blue solution (Merck, Darmstadt, Germany) diluted in phosphate buffer (pH 4–6) for 45 seconds. After following the same initial steps as for Hematoxylin and Eosin staining, the sections were immersed in toluidine blue (Merck, Darmstadt, Germany) working solution for 10 min and washed in distilled water, for three changes. They were then dehydrated quickly through 90% and two changes of 100% alcohol (10 dips each since stain fades quickly in alcohol). Sections were then cleared in xylene, two changes, and 3 min each and mounted with DPX mounting medium.^[10] The mast cell cytoplasm contains granules (metachromatic) composed of heparin and histamine. The sulfated proteoglycans in secretory granules of mast cells have a metachromatic property being stained by toluidine blue. Toluidine blue stains mast cells red-purple (metachromatic staining) and the background blue (orthochromatic staining), so mast cells could be detected.^[1]

For the determination of mast cell density, the stained sections were screened at low power ($\times 5$) to

identify the areas of the hot spots. A pathologist evaluated the mast cells count under Olympus BX41 (Olympus, Tokyo, Japan) light microscope at the $400\times$ magnification in five hot spots and the average number was determined as mast cell count.^[15]

Results

The average age of patients in OSCC group was $65.89(\pm 11.47)$ years and in control group was $33.93(\pm 10.90)$ years. Twenty four males and thirty six females were involved in this study (OSCC: 14 males, 16 females, control group: 10 males, 20 females). 13 samples in OSCC group was located in buccal mucosa 14 cases in alveolar ridge, one case in lip and one case in tongue. The highest mast cell count was seen in normal tissue and between OSCC high grade and low grade the mast cell count was higher in low grade OSCC, but the differences between groups weren't statistically significant ($p=0.056$). (figure 1) (table 1)

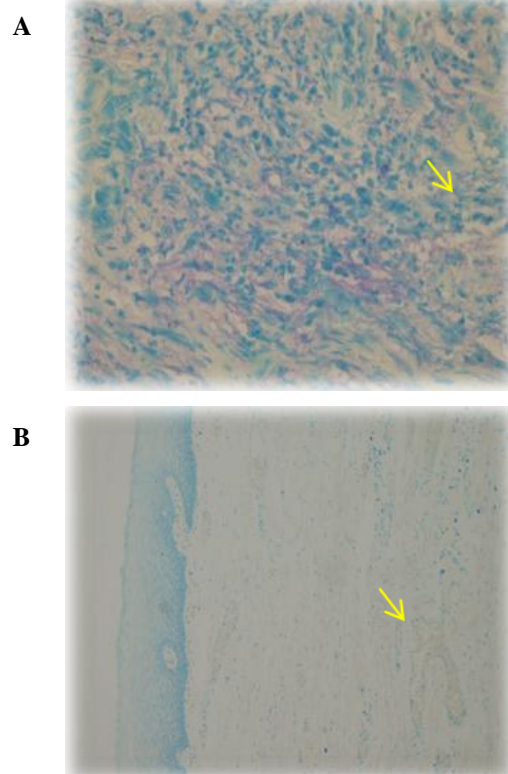


Figure 1. Shows Mast cells with toluidine blue staining in normal oral tissue low power (A) and high power (B).

The Mean count of mast cell between OSCC and normal oral mucosa was statistically significant different ($p=0.019$). We didn't observe any statistically significant difference between Mast cell counts of control group and low grade OSCC ($p=0.106$). The same result was seen between high grade and low grade OSCC ($p=0.582$). (figure 2) (table 1)

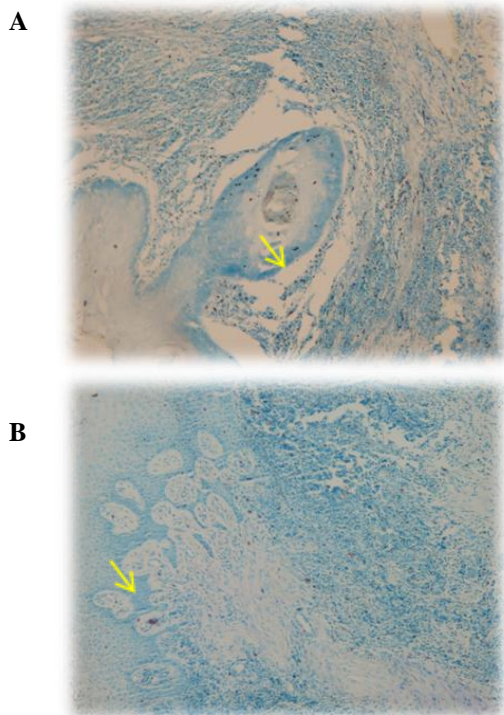


Figure2. Shows Mast cells with toluidine blue staining in low grade OSCC low power (A) high power (B).

The mast cell count difference between high grade OSCC and normal oral mucosa was significant ($p<0.05$). (figure3) (table 1)

Table1. Mean mast cell number among groups

Groups	Mean mast cell Mean±SD	Min- max
High grade OSCC	4.87±2.99*	0-12
Low grade OSCC	5.33±2.05	2-10
OSCC(total)	5.10±2.537**	0-12
Normal oral mucosa	6.53±2.03	4-14

* statistically significant difference in $\alpha=0.05$ with normal oral mucosa ($p=0.026$)

** statistically significant difference in $\alpha=0.05$ with normal mucosa ($p=0.019$)

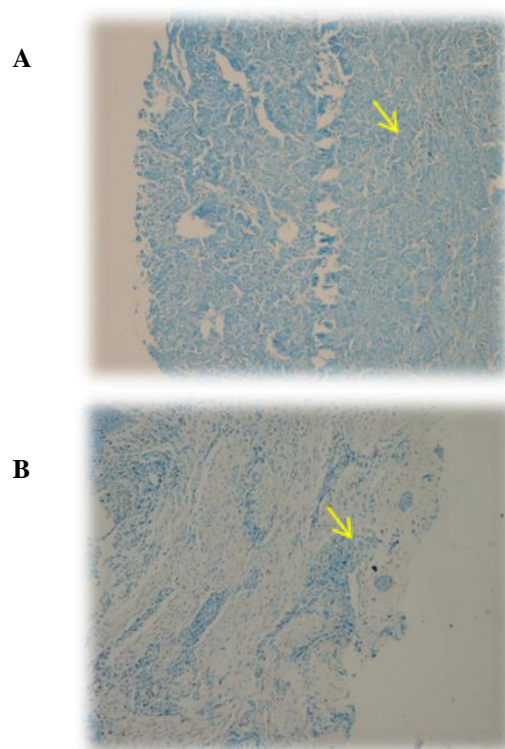


Figure3. Shows Mast cells with toluidine blue staining in high grade OSCC low power (A) high power (B).

The Mean count of mast cell between male and female totally and in each groups weren't statistically significant different ($p>0.05$) (table 2)

Table2. Mean of mast cell among groups based on gender

Groups	Mean mast cell Mean±SD	
	Male	Female
High grade OSCC	5.25±1.708	4.73±3.40
Low grade OSCC	5.00±1.944	6.00±2.34
Normal mucosa	7.10±1.85	6.25±2.09
Total	5.92±2.062	5.75±2.612

Discussion

In this study we assessed the number of mast cells in low grade and high grade OSCC and normal oral mucosa. According to the result, the average amount of mast cells decreased in OSCC in comparison with normal oral mucosa. The result of this study is similar to Cheema et al [16], and Oliveira-Neto et al. [10] In several studies mast cells count in well differentiated

OSCC was reported significantly higher than moderately and poorly differentiated.^[10,16]

However, Oliveira-Neto et al. found that the mast cell density was lower in OSCC and in premalignant lesions in comparison with control group. They attributed it to the migration failure of the mast cells, which possibly reflected a modification in the microenvironment during the tumor initiation and progression. Some researchs have shown the antitumor function of the mast cells, including natural cytotoxicity and antitumor components release.^[10]

Several investigators^[1,11,13] observed that mast cell count in high grade OSCC was significantly higher than normal oral mucosa, so it is in contrast with present study. This difference may be explained by the difference between location of tumors, patients age, sex, and stains were used.

Jandinski et al.^[17] did not found any significant difference in mast cells number between normal tissue and benign hyperkeratotic and dyskeratotic tissues. Increased number of mast cells was observed in low-grade carcinoma suggesting an immunological cause for this increase. A decrease in mast cell number was observed in the medium-high grade carcinomas which was attributed to an unfavorable cellular environment. They spitulated that the transition from an increased to a decreased number of mast cells in oral mucosa represents a competition between the immunologic system and the tumor cellular environment.^[18]

Tahir et al. report that angiogenesis does increase in OSCC and mast cells also invade the peri-tumoral tissue, but they are not directly correlated they suggested the difference in results of various studies could be attributed to the difference of immune-markers and stains used. Another factor affecting the results, could be the degranulation of mast cells at a given point of time.^[1]

Tomita et al. have proposed two reasons for such findings about the role of mast cells. The cytotoxic functions of the mast cells is the tumor activity suppression which may be seen when the mast cells infiltrate the tumor tissue. But, after the infiltration, tumoral cells may accelerate the angiogenic activities of the mast cells, and suppress their cytotoxic activities, this may lead to tumor angiogenesis. The effect of the mast cells on cancer cells may depend on the concentration of the mast cell products in the microenvironment. According to these findings,

hypothesized that reversing this process, i.e., promoting the cytotoxic functions of mast cells and suppressing their angiogenic activity, could lead to a new anti-cancer treatment strategy. Furthermore, it has been reported that mast cell heparin inhibitors, protamine and platelet factor 4, inhibit angiogenesis.^[19] The pattern of inflammatory and immune cell infiltration in the tumor microenvironment could contribute to cancer progression and metastasis or to the inhibition of tumor growth.^[18] Mast cells exert their tumorigenic effect through four mechanisms, i.e., (1) immunosuppression (2) angiogenesis (3) degradation of extracellular matrix and (4) mitogenesis.^[1,8]

Among these, angiogenesis have a critical role in tumor growth. In order to outgrow the size of 2 cubic mm, solid tumors need oxygen supply and angiogenesis is necessary to remove waste products and to provide nutrition and immune cells for growing of tumor.^[20]

Anuradha et al. revealed a definitive increase in mast cells count in oral squamous cell carcinoma as compared to normal mucosa. They put fourth following possible reasons for their findings. Mast cells play a significant roles in the early stages of cancer progression. Whereas, they decrease in second cancer face, because tumor cells are not dependent on this cells anymore for neovascularization and another reason may be inter observer mistake to classifying oral squamous cell carcinoma.^[21]

Conclusion

According to the results, the average number of mast cells decreased in OSCC in comparison with normal oral mucosa. A significant difference was observed in the mast cell count in high grade OSCC in comparison with normal oral mucosa. This degradation may be due to exposure of cytokines or chemokines released by tumor cells or other inflammatory. Although further study is needed for healthy cells around tumor.

Funding: This study was a part of thesis and research project (Grant No: 9134834) supported and funded by Babol University of Medical Sciences.

Conflict of interest: We declare that there is no conflict of interest.

References

1. Tahir A, Nagi AH, Ullah E, Janjua OS. The role of mast cells and angiogenesis in well-differentiated oral squamous cell carcinoma. *J Cancer Res Ther* 2013;9:387-91.
2. Tae K, El-Naggar AK, Yoo E, Feng L, Lee JJ, Hong WK, et al. Expression of the vascular endothelial growth factor and the micro vessel density in the head and neck tumorigenesis. *Clin Cancer Res* 2000;6:2821-8.
3. Boring CC, Squires TS, Tong T, Montgomery S. Cancer statistics, 1994. *CA Cancer J Clin* 1994;44:7-26.
4. Field JK. Oncogenes and tumour-suppressor genes in squamous cell carcinoma of the head and neck. *Eur J Cancer B Oral Oncol* 1992; 28B:67-76.
5. Balica N, Raica M, Cotulbea S, Doros C. Mast cell reaction in malignant laryngeal neoplasm. *Rom J Morphol Embryol* 2007;48:395-401.
6. Norrby K, Wooley D. Role of mast cells in mitogenesis and angiogenesis in normal tissue and tumor tissue. *Adv Biosci* 1993, 89:71-115.
7. Coussens LM, Raymond WW, Bergers G, Laig-Webster M, Behrendtsen O, Werb Z, et al. Inflammatory mast cells up-regulate angiogenesis during squamous epithelial carcinogenesis. *Genes Dev* 1999; 13:1382-97.
8. Ch'ng S, Wallis RA, Yuan L, Davis PF, Tan ST. Mast cells and cutaneous malignancies. *Mod Pathol* 2006;19:149-59.
9. Galinsky DS, Nechushtan H. Mast cells and cancer - no longer just basic science. *Crit Rev Oncol Hematol* 2008;68:115-30.
10. Oliveira-Neto HH, Leite AF, Costa NL, Alencar RC, Lara VS, Silva TA, et al. Decrease in mast cells in oral squamous cell carcinoma: possible failure in the migration of these cells. *Oral Oncol* 2007;43:484-90.
11. Kalra M, Rao N, Nanda K, Rehman F, Girish KL, Tippu S, et al. The role of mast cells on angiogenesis in oral squamous cell carcinoma. *Med Oral Patol Oral Cir Bucal* 2012;17:e190-6.
12. Iamaroon A, Pongsiriwet S, Jittidecharaks S, Pattanaporn K, Prapayasatok S, Wanachantararak S. Increase of mast cells and tumor angiogenesis in oral squamous cell carcinoma. *J Oral Pathol Med* 2003;32:195-9.
13. Michailidou EZ, Markopoulos AK, Antoniadis DZ. Mast Cells and Angiogenesis in Oral Malignant and Premalignant Lesions. *Open Dent J* 2008;2:126-32.
14. Bhagava A, Saigal S, Chalishazar M. Histopathological Grading System In Oral Squamous cell Carcinoma:A Review. *J Int Oral Health* 2010;2:1-10
15. Jaafari Ashkavandi Z, Moshref M, Mashhadi-Abbas F, Sargolzaie S, Taghavi N. Evaluation of CD31 Expression and Mast Cell Count in Dysplastic Lesions and Squamous Cell Carcinoma of the Oral Cavity. *Iran Red Cres Med J* 2010;12: 272-6.
16. Cheema VS, Ramesh V, Balamurali PD. The relevance of mast cells in oral squamous cell carcinoma. *J Clin Diagn Res* 2012;6:1803-7.
17. Jandinski JJ, Sonis S, Doku HC. The incidence of mast cells in selected oral lesions. *Oral Surg Oral Med Oral Pathol* 1972;34:245-8.
18. Balkwill F. Cancer and the chemokine network. *Nat Rev Cancer* 2004;4:540-50.
19. Tomita M, Matsuzaki Y, Onitsuka T. The effect of mast cells on the tumor angiogenesis in lung cancer. *Ann Thorac Surg* 2000;69:1686-90.
20. Makrilia N, Lappa T, Xyla V, Nikolaidis I, Syrigos K. The role of angiogenesis in solid tumours: an overview. *Eu J Intern Med* 2009;20:663-71.
21. Anuradha A, Kiran Kumar Naik B, Vijay Srinivas G, Devi RS, Puneet HK. Incidence of mast cells in oral squamous cell carcinoma.a short study. *J Oncol* 2014; 2014:614291.