

Case Report

A case report of neurofibromatosis

Shimae Nafarzadeh (DDS)^{1✉}, Mina Motallebnejad (DDS)²,
Anahita Ghorbani (DDS)³, Naghmeh Jamaatlou (DDS)⁴

1. Assistant Professor, Department of Oral & Maxillofacial Pathology, Faculty of Dentistry, Babol University of Medical Sciences, Babol-Iran.
2. Associate Professor, Cellular & Molecular Biology Research Center, Department of Oral Medicine, Faculty of Dentistry, Babol University of Medical Sciences, Babol-Iran.
3. Postgraduate Student, Department of Oral Medicine, Faculty of Dentistry, Babol University of Medical Sciences, Babol-Iran.
4. Postgraduate Student, Department of Oral & Maxillofacial Pathology, Faculty of Dentistry, Babol University of Medical Sciences, Babol-Iran.

✉ **Corresponding Author:** Shimae Nafarzadeh, Faculty of Dentistry, Babol University of Medical Sciences, Babol-Iran.

Email: shima_nafar2004@yahoo.com

Tel: +98112291408

Abstract

Introduction: Neurofibromatosis is a genetic disease characterized by multifocal benign tumors of peripheral nerves, called neurofibromas, and pigmented spots on the skin which inherited as autosomal-dominant. The most common form of the disease is neurofibromatosis type 1, also known as von Recklinghausen's disease of the skin. When an individual has small number of lesions in a limited region of the his body, it could be missed by the patient or not acknowledged by the clinicians as a form of neurofibromatosis. We present here, a case of an 18-year-old male with neurofibromatosis type 1 who referred to Babol Dental School for a routine dental examination.

Keywords: Neurofibromatosis type I, Neurofibroma, Cutaneous neurofibroma, Hard palate

Received: 17 Sept 2013

Accepted: 3 Feb 2014

Citation for article: Nafarzadeh Sh, Motallebnejad M, Ghorbani A, Jamaatlou N. A case report of neurofibromatosis. *Caspian J Dent Res* 2014; 3: 47-51.

گزارش موردی از نوروفیبروماتوزیس

شیما نفرزاده*، مینا مطلب نژاد، آناهیتا قربانی، نغمه جماعتلو

چکیده

مقدمه: نوروفیبروماتوزیس یک بیماری ژنتیکی است که مبتلایان دارای تومورهای خوش خیم متعدد اعصاب محیطی به نام نوروفیبروما و لکه های رنگدانه در پوست می باشند. از نظر ژنتیکی به صورت اتوزومال غالب به ارث می رسد. رایجترین شکل از بیماری نوروفیبروماتوزیس نوع ۱ یا بیماری Recklinghausen Von پوست شناخته شده است. هنگامی که یک فرد دارای تعداد کمی از ضایعات در یک منطقه محدود از بدن باشد، ممکن است مورد توجه قرار نگیرد و یا توسط پزشکان تشخیص داده نشود. در اینجا موردی از یک پسر ۱۸ ساله مبتلا به نوروفیبروماتوزیس نوع ۱ که برای معاینه معمول دندانپزشکی به دانشکده دندانپزشکی بابل مراجعه کرده است، گزارش می شود.

واژگان کلیدی: نوروفیبروماتوزیس، نوروفیبروما، گزارش مورد

Introduction

Neurofibroma is a benign slow growing tumor (1). It is the most common neoplasm in peripheral nervous system, originating from "Schwann cells" and perineural fibroblasts (2). This neoplasm may manifest as a solitary nodule or as a generalized syndrome called Neurofibromatosis or Von Recklinghausen disease (1). However, neurofibroma is a common neurogenic tumor, it is rare in oral cavity (3) and skin is the most common region of involvement (4-8).

It is usually seen in the 3rd decade of life without any sex predilection (5). Clinically neurofibroma is a pedunculated or sessile slow growing nodule in oral cavity. It is usually painless, but pain and parasthesia may occur due to nerve compression.

Tongue is the most frequent region of intraoral involvement, but it may be seen in other regions such as palate, buccal mucosa and floor of the mouth (9-11). Cases of mandibular bone involvement have been reported (12-15).

At least eight different form of neurofibromatosis is known and type I is the most common form. In this type, patients suffer from several neurofibromas, Skin is the most common affected site. Any organs maybe affected. Tumors may be present at birth or maybe seen first at adolescent and grow gradually and slowly. Hyperpigmentation in skin, called café au lait macules

and macules on the axilla or the groin regions (crave's sign) are the pathognomonic signs of the disease. Lisch nodules in iris are seen in all affected patients (2).

Here, we report a case of Neurofibromatosis type I with cutaneous and oral lesions.

Case report

An 18 year old male with no history of any specific disease and alcohol or nicotine consumption referred to the Oral Medicine Department of Babol University of Medical Sciences for routine dental examination. We found a soft, sessile, exophytic mass with pink homogenous color and fluctuant in texture, located in his hard palate, approximately 2 x 1.6 cm (figure 1). In radiographic examination, we found no abnormal changes. We found several subcutaneous nodules on his hand and trunk and 4-5 café au lait macules were seen in his thoracic region (figure 2). An incisional biopsy of the hard palate mass was done. On gross examination, 2 pieces of triangular, firm and creamy tissues covered by oral mucosa, measured 0.8×0.7×0.2 cm, were seen.

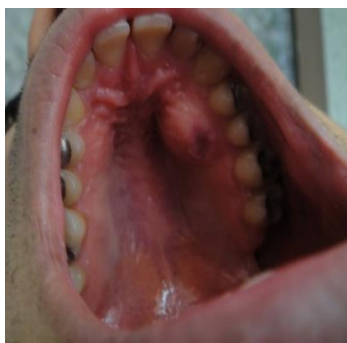

Figure 1. Clinical view of the patient's oral lesion

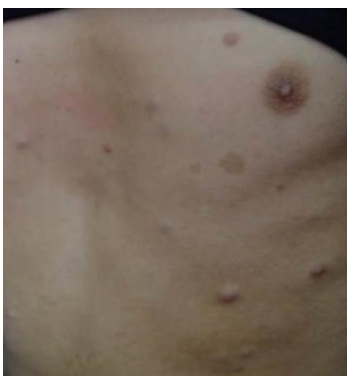

Figure 2. Clinical view of subcutaneous nodules and café au lait macules on the patient's trunk

The microscopic examination revealed a tumor that composed of spindle shaped cells with wavy nuclei scattered in a fibrous to myxoid stroma (figure 3 and 4). Neurofibroma, neurilemmoma and palisaded encapsulated neuroma can be considered as differential diagnoses. Considering the whole microscopic features, neurofibroma was rendered as the histopathologic diagnosis and also, neurofibromatosis was described as the final diagnosis based on combining clinical and microscopic findings.

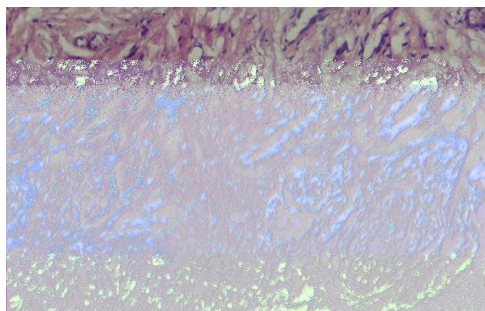


Figure 3. Microscopic view showing some sections of neurons and spindle shaped cells with wavy nuclei scattered in a fibrotic stroma (H&E staining; x 100)

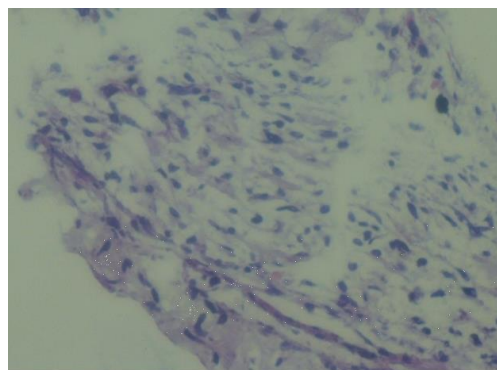


Figure 4. Microscopic view showing spindle shaped cells with wavy nuclei scattered in a myxoid stroma (H&E staining x 400)

Discussion

The symptoms of neurofibromatosis have been observed for a long time before Robert William Smith described it in 1849 (16). The classic variety is the one which German pathologist, Friedrich Daniel von Recklinghausen reported, who precisely described the diverse findings as a single entity in 1882; so the condition is often directed to as von Recklinghausen's disease (17).

On the basis of the most widely accepted classification, there are four recognized forms of neurofibromatosis: von Recklinghausen's neurofibromatosis (or neurofibromatosis type 1 [NF-1] or peripheral neurofibromatosis). Bilateral acoustic neurofibromatosis (or neurofibromatosis type 2 [NF-2] or central neurofibromatosis).

Segmental neurofibromatosis cutaneous neurofibromatosis (17). Advances in molecular genetics have produced a sharp delineation between, the variants of NF. NF-1 has been related to alterations in the long arm of chromosome 17 (18-23), characterized by the formation of tumors surrounding the nerves and a variety of other pathological features (17).

In childhood or early adolescence, the characteristic clinical features would be apparent (21, 24). NF-1 which is the most common type accounts for 90% of cases and is characterized by multiple café-au-lait spots and the incidence of neurofibromas along peripheral nerves (17).

Café-au-lait discoloration generally emerge before the development of neurofibromas and their amounts increase with age (25). Cutaneous neurofibromas are soft, fleshy -pink colored tumors, most enormous on the trunk and limbs as sessile or dome-shaped masses.

Other clinical aspects contain Lisch's nodules (melanocytic pigmented iris hamartomas) and oral lesions (17).

Although bilateral Lisch's nodules are indicative of the disease, they are not quite diagnostic (26). Possible childhood complexities contain the optic glioma growth, endocrine disturbances and entailment of the lower urinary tract. Learning disabilities may also be presented in children (17). For all cases, histopathologic examination is needed.

It is important to mention that numerous variants of the classic neurofibroma may be seen in the oral cavity (i.e. 1-classic neurofibroma, 2-plexiform neurofibroma or neuroma, 3-the pseudo-schwannoma form of neurofibroma, 4-hemangioneurofibroma) (27).

For diagnosing NF-1, at least two of the below criteria must be present according to the National Institute of Health Consensus Development Conference (28).

1. Five or more cafe-au-lait spots larger than 5 mm in diameter in prepubertal patients; six or more cafe-au-lait spots larger than 15 mm in diameter in postpubertal patients
2. Two or more neurofibromas of any type, or one plexiform neurofibroma
3. Axillary or inguinal freckling
4. Optic glioma
5. Two or more Lisch's nodules (iris hamartomas)
6. A distinctive osseous lesion (pseudoarthrosis of the tibia or sphenoid wing dysplasia)
7. A first-degree relative diagnosed (17).

The patient, presented here, had multiple tumors on his arms and trunk other than the one existed on his hard palate; so we referred him to compatible centers for treatment. He did not respond to our calls for following up his treatment procedure.

Conclusions

The patient described here is a very typical case of NF-1. In such a case, a detailed patient investigation is required because of the possibility for generalized involvement of other organs.

The proper clinical and genetic analysis is important for the determination of the genetic risk and evaluation of the prognosis of the disease. The treatment of such kind of patient is surgery, seeking to achieve cosmetic improvement, and may be only palliative (17).

References

1. Greinwald J, Derkay CS, Schechter GL. Management of massive head and neck neurofibromas in children. *Am J Otolaryngol* 1996; 17: 136-42.
2. Damm DD, Bouquot JE, Neville BW, Allen C. *Oral & Maxillofacial Pathology*. 3rd ed. St.louis: Saunders Elsevier; 2009. p. 528,530.
3. Boedeker CC, Ridder GJ, Kayser G, Schipper J, Maier W. Solitary neurofibroma of the maxillary sinus and pterygopalatine fossa. *Otolaryngol Head Neck Surg* 2005; 133: 458-9.
4. Alatli C, Oner B, Ünür M, Erseven G. Solitary plexiform neurofibroma of the oral cavity A case report. *Int J Oral Maxillofac Surg* 1996; 25: 379-80.
5. Gómez-Oliveira G, Fernández-Alba Luengo J, Martín-Sastre R, Patiño-Seijas B, López-Cedrún-Cembranos JL. Plexiform neurofibroma of the cheek mucosa. A case report. *Med Oral* 2004; 9: 263-7. [In English, Spanish]
6. Badger GR. Solitary neurofibromatosis in the maxilla: report of oral findings. *J Am Dent Assoc* 1980; 100: 213-4.
7. Che Z, Nam W, Park WS, Kim HJ, Cha IH, Kim HS, et al. Intraosseous nerve sheath tumors in the jaws. *Yonsei Med J* 2006; 47: 264-70.
8. Güneri EA, Akoğlu E, Sütay S, Ceryan K, Sağol O, Pabuçcuoğlu U. Plexiform neurofibroma of the tongue: a case report of a child. *Turk J Pediatr* 2006; 48: 155-8.
9. Zachariades N, Mezitis M, Vairaktaris E, Triantafyllou D, Skoura-Kafoussia C, Konsolaki-Agouridaki E, et al. Benign neurogenic tumors of the oral cavity. *Int J Oral Maxillofac Surg* 1987; 16: 70-6.
10. Richards D. Neurofibroma of the oral cavity. *Br J Oral Surg* 1983; 21: 36-43.
11. Skouteris CA, Sotereanos GC. Solitary neurofibroma of the maxilla: report of a case. *J Oral Maxillofac Surg* 1988; 46: 701-5.
12. Vivek N, Manikandhan R, James PC, Rajeev R. Solitary intraosseous neurofibroma of mandible. *Indian J Dent Res* 2006; 17: 135-8.
13. Ueda M, Suzuki H, Kaneda T. Solitary intraosseous neurofibroma of the mandible: report of a case. *Nagoya J Med Sci* 1993; 55: 97-101.
14. Apostolidis C, Anterriotis D, Rapidis AD, Angelopoulos AP. Solitary intraosseous

- neurofibroma of the inferior alveolar nerve: report of a case. *J Oral Maxillofac Surg* 2001; 59: 232-5.
15. Sigillo R, Rivera H, Nikitakis NG, Sauk JJ. Neurofibromatosis type 1: a clinicopathological study of the orofacial manifestations in 6 pediatric patients. *Pediatr Dent* 2002; 24: 575-80.
 16. Kobrin JL, Blodi FC, Weingeist TA. Ocular and orbital manifestations of neurofibromatosis. *Surv Ophthalmol* 1979; 24: 45-51.
 17. Dimitrova V, Yordanova I, Pavlova V, Valtchev V. A case of neurofibromatosis type 1. *J of IMAB* 2008; 14 book 1: 63-7.
 18. Geist JR, Gander DL, Stefanac SJ. Oral manifestations of neurofibromatosis types I and II. *Oral Surg Oral Med Oral Pathol* 1992; 73: 376-82.
 19. Aoki S, Barkovich AJ, Nishimura K, Kjos BO, Machida T, Cogen P, et al. Neurofibromatosis types 1 and 2: cranial MR findings. *Radiology* 1989; 172: 527-34.
 20. Wertelecki W, Rouleau GA, Superneau DW, Forehand LW, Williams JP, Haines JL, et al. Neurofibromatosis 2: clinical and DNA linkage studies of a large kindred. *N Engl J Med* 1988; 319: 278-83.
 21. Arendt DM, Schaberg SJ, Meadows JT. Multiple radiolucent areas of the jaw. *J Am Dent Assoc* 1987; 115: 597-9.
 22. Riccardi VM. Neurofibromatosis: challenges for applied cellular and molecular biology. *Lab Invest* 1988; 59: 726-8.
 23. Spence MA, Sparkes RS, Parry DM, Bale SJ, Cortessis V, Mulvihill JJ. Genetic linkage studies with neurofibromatosis: the question of heterogeneity. *J Med Genet* 1987; 24: 527-9.
 24. Adekeye EO, Abiose A, Ord RA. Neurofibromatosis of the head and neck: clinical presentation and treatment. *J Maxillofac Surg* 1984; 12: 78-85.
 25. White AK, Smith RJ, Bigler CR, Brooke WF, Schauer PR. Head and neck manifestations of neurofibromatosis. *Laryngoscope* 1986; 96: 732-7.
 26. Reynolds RL, Pineda CA. Neurofibromatosis: review and report of case. *J Am Dent Assoc* 1988; 117: 735-7.
 27. Baden E, Fischer RJ. Multiple neurofibromatosis and neurofibroma of the palate. Report of a case. *Oral Surg Oral Med Oral Pathol* 1963; 16: 1356-64.
 28. Neurofibromatosis. Conference statement. National Institutes of Health Consensus Development Conference. *Arch Neurol* 1988; 45: 575-8.