

Original Article

Evaluation of the accuracy of panoramic radiograph in determining the location of the lingula

Ehsan Moudi (DDS)¹, Mohammad Mehdizadeh (DDS)^{2✉}, Sina Haghanifar (DDS)³,
Maryam Sheikhi⁴, Ali Bijani (MD)⁵.

1. Assistant Professor, Department of Oral and Maxillofacial Radiology, Faculty of Dentistry, Babol University of Medical Sciences, Babol-Iran.
2. Assistant Professor, Department of Oral and Maxillofacial Surgery, Faculty of Dentistry, Babol University of Medical Sciences, Babol-Iran.
3. Associate Professor, Department of Oral and Maxillofacial Radiology, Faculty of Dentistry, Babol University of Medical Sciences, Babol-Iran.
4. Dental Student, Faculty of Dentistry, Babol University of Medical Sciences, Babol-Iran.
5. General Practitioner, Non-Communicable Pediatrics Diseases Research Center, Babol University of Medical Sciences, Babol-Iran.

✉**Corresponding Author:** Mohammad Mehdizadeh, Faculty of Dentistry, Babol University of
Medical Sciences, Babol-Iran

Email: dr.rmohammad@yahoo.com

Tel: +98121512840

Abstract

Introduction: The purpose of this study was to determine the accuracy of panoramic radiograph in locating the position of lingula as an index to estimate the location of mandibular foramen.

Methods: The distance measurement in this study was carried out on 30 dry mandibles, composed of at least 2 first molars and one canine. Photography and panoramic radiography of the mandible was performed in a steady reproducible position. 10 lines (including 2 horizontal and 8 vertical) were drawn from the lingula to the anterior and posterior borders of ramus, the coronoid process and the lower border of the mandible. These lines were measured and compared in photographs and panoramic radiographs. The data were analyzed using SPSS 20 software, paired t-test, Pearson correlation and linear regression analysis.

Results: Considering all different distances, there was no significant difference between the findings of panoramic radiographs and photographs with regard to 3 indices as follows: cd (posteroinferiormostpoint of mandibular foramen to the posterior border of the mandible); ln (5 mm behind the postero inferior most point of mandibular foramen to the lower border of mandible) gh (5 mm ahead of superior most point of mandibular foramen to the coronoid notch). Whereas, a significant difference was observed in other indices.

Conclusions: It seems that the Panoramic radiograph is an inaccurate guide to display the precise location of the lingula.

Keywords: Panoramic radiography, Mandible, Dimensional measurement

Received:11 Jun 2013

Accepted:13 Aug 2013

ارزیابی دقت رادیوگرافی پانورامیک در تعیین محل لینگولا

چکیده

مقدمه: هدف از این مطالعه، ارزیابی دقت رادیوگرافی پانورامیک در تعیین محل لینگولا به عنوان شاخصی جهت شناسایی موقعیت سوراخ مندیولار می باشد.

مواد و روش ها: در مطالعه حاضر ۳۰ عدد فک پایین خشک با دندان که حداقل دو دندان مولر اول و یک کانین دارند برای اندازه گیری انتخاب شدند. در یک موقعیت ثابت و قابل تکرار، از فک های پایین، فوتوگرافی و رادیوگرافی پانورامیک به عمل آمد. ۱۰ خط (شامل ۲ خط افقی و ۸ خط عمودی) از لینگولا به بوردر قدامی و خلفی راموس، زائده کورونوئید و بوردر تحتانی فک پایین، رسم شد. این خطوط در فوتوگرافی و رادیوگرافی پانورامیک اندازه گیری گردیده و با هم مقایسه شدند. اطلاعات با استفاده از نرم افزار آماری SPSS 20 و با استفاده از آزمون Paired T test، ضریب همبستگی پیرسون و رگرسیون خطی مورد تجزیه و تحلیل قرار گرفتند.

یافته ها: فقط در سه شاخص cd (تحتانی خلفی ترین نقطه ی سوراخ مندیولار تا بوردر خلفی فک پایین)، gh (پنج میلی متر جلوتر از فوقانی ترین نقطه ی سوراخ مندیولار تا زائده کورونوئید) و ln (پنج میلی متر عقب تر از خلفی تحتانی ترین نقطه ی سوراخ مندیولار تا بوردر تحتانی فک پایین) بین رادیوگرافی پانورامیک و فوتوگرافی تفاوت معناداری وجود نداشت. در مورد سایر شاخص ها اختلاف رادیوگرافی پانورامیک و فوتوگرافی معنادار بود.

نتیجه گیری: به نظر می رسد رادیوگرافی پانورامیک ابزار دقیقی در نشان دادن محل واقعی لینگولا نیست.

واژگان کلیدی: رادیوگرافی پانورامیک، فک پایین، اندازه گیری ابعادی

Introduction

The lower jaw bone as one of the facial bones is composed of symphysis, ramus and body (1). Lingula is located on the medial surface of ramus, close to lumen of the mandibular canal and in many cases at its entrance (2).

The shape of lingula varies among different populations and is classified as truncated, nodular and triangular (3). In more than 50% of adults, lingula is encountered in the development of half to 2/3 of wall of mandibular foramen. Mylohyoid ridge extends from the posterior border of the lingula (4). Lingula is a remarkable bony landmark in the identification of the mandibular foramen during dental treatment and maxillofacial surgery (5-10). Panoramic radiograph provides information about the location of symphysis, body and ramus of the mandible (11).

The mandibular foramen and the lingula are among the recognizable anatomical landmarks on panoramic radiographs. This technique (panoramic radiograph) is beneficial in the estimation of the mandibular foramen distance to the anteroposterior and superoinferior borders of the mandible (12).

Total measurements obtained from panoramic radiographs have been opposed as a result of extensive variability in methods and errors. Some researchers suggest that the use of standardized head position, bite block and accurate imaging technique make panoramic radiograph as a beneficial guide for this purpose (13). The aim of this study was to determine the location of lingula on panoramic radiograph and compare it with the correct location on dry mandible.

Methods

This study was performed on 30 dry mandibles, which prepared in Oral and Maxillofacial Radiology Department of Babol University of Medical Sciences, which had at least 2 first molars and canine.

These 2 teeth were selected as reference points to draw an imaginary occlusal plane. All photographs of mandible were taken with Canon EOS 450D (Japan) camera using EF 100 mm F/2.8 MACRO USM (Japan) lens. In all the photographs, the distance between camera lens and the mandibular foramen was equal. Then all the images were printed in actual dimensions on A4 please mention the dimentions paper. On this paper, the location of mandibular foramen was specified and the lines were drawn. Posterior border of

ramus, coronoid process, inferior border of mandible, 5mm ahead and behind the mandibular foramen to the coronoid process and inferior border of mandible were marked. The mandibular foramen was identified at the superoinferiormost and posteroinferiormost points.

The measured 10 line distances are as follows:

- 1.The superiormost and anteriormost points of mandibular foramen to the anterior border of ramus (ab).
- 2.The inferiormost and posteriormost points of mandibular foramen to the posterior border of mandible (cd).
- 3.The superiormost and anteriormost points of mandibular foramen to the coronoid notch (perpendicular to connecting line between tip of condylar head and coronoid process) (ae)
- 4.The superiormost and anteriormost points of mandibular foramen to the lower border of mandible.(perpendicular to the connecting line between tip of condylar head and coronoid process) (af)
- 5.5mm ahead of superiormost point of mandibular foramen to the coronoid notch (perpendicular to the connecting line between tip of condylar head and coronoid process) (gh).
- 6.5mm ahead of anteriormost and superiormost points of mandibular foramen to the inferior border of mandible (perpendicular to the connecting line between the tip of condylar head and coronoid process) (gi)
- 7.Posteriormost and inferiormost points of mandibular foramen to the coronoid notch (perpendicular to the connecting line between tip of condylar head and coronoid process) (cj)
- 8.Posteriormost and inferiormost points of mandibular foramen to the lower border of mandible (perpendicular to the connecting line between tip of condylarhead and coronid process) (ck)
- 9.5mm behind the posteriormost&inferiormost points of mandibular foramen to the coronid notch (prependicular to the connecting line between tip of condylar head and coronid process) (lm)
- 10.5mm behind the posteriormost and inferiormost points of mandibular foramen to the lower border of mandible (perpendicular to the line connecting the tip of condylar head and coronid process) (ln). (figure 1)

An electronic digital caliper was used to measure a total of 10 lines with the minimum error being 1% mm. One observer repeated the measurements twice in 30 dry mandibles. 2 weeks after the first measurement, the second measurement was performed.

Two lines were drawn parallel to the connecting line between the tip of condylar head to the tip of coronoid process, the first line from the anterosuperiormost point of mandibular foramen to the anterior border of ramus and the second line from the posteroinferiormost point of mandibular foramen to the posterior border of ramus of mandible.

In this study, a routine panoramic radiographic technique without the application of metallic landmark was used to localize the place of lingula. Dry human mandibles were put in panoramic machine. The occlusal plane (an imaginary line drawn through the canine to the first molar) was aligned parallel with the floor. In the anterior region, a bite block was used.

To counteract lack of soft tissue on skull 3, layers of lead foil present in intraoral occlusal film were used. Dry human mandible was secured on a plate made of PVC material, located within the image layer of panoramic machine (centered on midline with the Frankfort horizontal plane parallel to the floor and Y line passing through the canine.)

All panoramic images were taken with the Cranex Tome Ceph (Soredex, Helsinki Finland) panoramic unit and Agfa (Ortho CP-Plus Belgium) x-ray film. Setting of 60 KVP, 4mA and exposure duration of 15 seconds with the standard panoramic program were used for all exposures. Then the images were processed by a Dental-Max (HOPE x-ray product, U.S.A) processor at 24.5 c using (Tetenal AG &Co,Germany) solution. (figure 2)

The images were shown on a light box. All the lines (10 lines) were drawn on zinc acetate sheet. A digital caliper with smaller gradation was used to measure the magnification of machine. The data were analyzed using SPSS 20 software, paired t-test, Pearson correlation and linear regression analysis.

Results

The distance differences between panoramic radiographs and photographs were statistically significant with regard to cd, gh& In ($p>0.05$). The data for other indices are as follows: Mean±SD of cd line in the photograph and panoramic radiograph is respectively 12.78 ± 2.88 and 12.60 ± 2.12 . Mean±SD of gh line in the photograph and panoramic radiograph is respectively 22.77 ± 8.42 and 24.48 ± 6.48 and for the In it is in order 19.03 ± 5.27 and 18.11 ± 4.36 . (The data for other indices are mentioned in table 1). Figure 3 shows

the relationship between the photographic and radiographic findings.

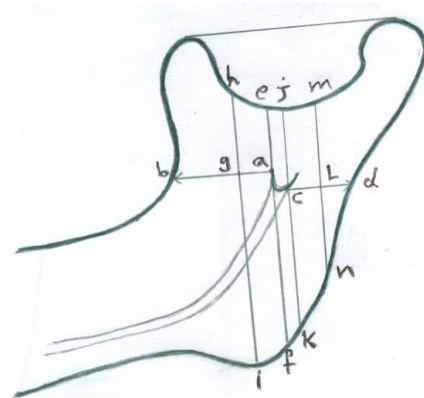


Figure 1. This schematic diagram shows the mandible and various mentioned distances

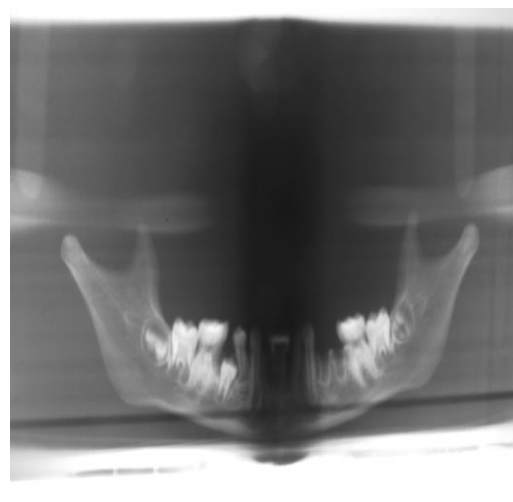


Figure 2. Image represents the panoramic radiograph of mandible Evaluation of image

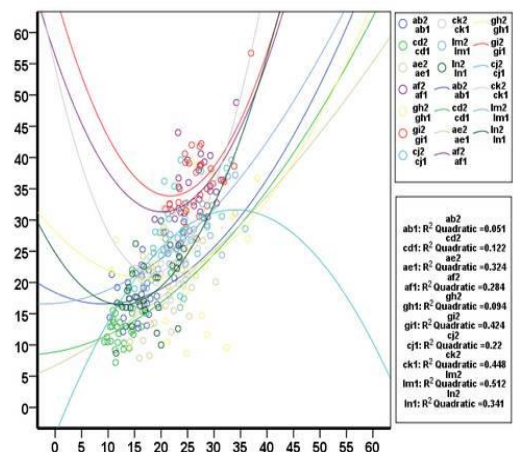


Figure 3. The relationship between the photographic and radiographic findings

Table 1. Differences between photographic and radiographic findings

index	Photographic	Panoramic	p-value	Pearson	p-value
	measurement	measurement		Correlation	
	Mean±SD	Mean±SD		coefficient	
ab	15.69±2.62	17.58±3.33	0.01	0.216	0.251
cd	12.60±2.12	12.78±2.88	0.748	0.349	0.58
ae	21.16±4.98	18.61±6.25	0.014	0.569	0.001
af	25.96±3.56	34.09±5.21	0.000	0.499	0.005
gh	24.48±6.48	22.77±8.42	0.318	0.253	0.178
gi	26.74±3.68	36.47±5.32	0.000	0.602	0.000
cj	23.69±4.80	27.64±6.03	0.001	0.443	0.014
ck	21.51±3.63	23.81±4.49	0.002	0.587	0.001
lm	24.01±4.75	26.98±5.30	0.000	0.711	0.000
ln	18.11±4.36	19.03±5.27	0.285	0.552	0.002

Discussion

The results of this study showed panoramic radiograph is not accurate to localize the place of lingula and statistically a significant difference exists between the panoramic radiographs and photographs. Among all the 10 evaluated indices (lines) no significant difference was observed between the photographs and panoramic radiographs with regard to 3 indices: cd, gh, ln.

There is a statistically significant difference in ck and ab but clinically a difference of 2 mm is acceptable. There is no significant difference in the measurements of cd between photographs and panoramic radiographs. Therefore, it can be a valuable guidance in inferior alveolar nerve block injection and vertical ramus osteotomy for surgeons.

Ln index can be used a determinant of the vertical height of inferior alveolar nerve block injection with respect to the height of ramus and it is also helpful in vertical ramus osteotomy. In existence of contradiction in the three above indices is because of the even surface of the mandible in mentioned regions. While in other indices, convexity and concavity of the inner surface of ramus causes distortion in panoramic radiography. gh is located on the even surface of ramus therefore, it is exposed to lesser amount of qualitative and quantitative changes during panoramic radiography.

In the present study, the mandibular photographs were used as the gold standard. The actual sizes of the horizontal and vertical dimensions were printed and the measurement of distances were performed on them. Perhaps this is the reason for the difference between

the present study and other researches on the same topic. Kositbowornchai et al. concluded that a high correlation was present between the panoramic and dry mandibular measurements (14). They performed the measurements directly on the dry mandible.

This is different from the present study. The specific anatomy of dry mandible causes a considerable error in direct measurements, therefore in the present study, photograph was used and calculation of its magnification coefficient was performed to reduce the measurement errors. They used the occlusal plane as reference line in their study, whereas, the occlusal plane and ramus were geometrically parallel. The drawing of horizontal lines parallel and vertical lines perpendicular to this plane cannot be done.

da Fontoura et al., nominated panoramic radiograph as a useful technique in localizing the position of lingula. Their study is not in accordance with our study. It can be due to the considerable errors in direct measurements on dry mandible. While a reliable reference line (connecting line between the tip of condylar head and coronoid process) was used in the present study, lack of this line was among the other error factors in their study(12).

In order to perform a correct inferior alveolar nerve block injection in clinic, Ezoddini Ardakani et al., used panoramic radiograph to locate the position of lingula and determine its distance with occlusal plane. They concluded that lingula is not an appropriate landmark for this injection (15). These studies are alike as they could not identify a precise location of lingula on panoramic radiograph and their injections were associated with a high risk of error. The restriction of measurements to the panoramic radiograph and lack of

the gold standard to locate the lingula were the other reasons for this error. They consider the success of anesthesia as a reason for consistency of clinical and panoramic radiography but the author does not accept its accuracy. Despite localizing the correct position of lingula, other factors such as the skill of surgeon, psychological and pathological factors, infection, misuse of drugs and surgical techniques can be effective on success of injection (16-19).

The difference in the nature of mandibular bone in children and adults and the location of lingula are among the other causative factors for the high risk of error in inferior alveolar nerve block injection (20).

Conclusion

According to the findings obtained from panoramic radiographs and dry human mandible photographs, panoramic radiograph is not an accurate technique to localize the position of lingula but the width and length ratios are among the helpful factors to locate the lingula.

Limitations

Because of the specific anatomy of the mandible, the performance of measurement on dry mandible is impossible, therefore, the measurements were taken on photographs. The inadequate number of samples is another limiting factor and it can be effective on the results of this study.

Acknowledgments

We are grateful for the support of Iman Gooran, Mr. Jabbari and the staff and personnel of the Department of Oral and Maxillofacial Radiology of Babol Dental School.

Funding: This study was a part of thesis and research project (Grant No: 9133630) which was supported and funded by Babol University of Medical Sciences.

Conflict of interest: There was no conflict of interest.

References

1. Standring S, editor. Gray's Anatomy: The Anatomical Basis of Clinical Practice. 40th ed. Edinburgh: Elsevier Churchill Living Stone; 2008. p.481-3.

2. Smith GI, Brennan PA, Oh SS, Markus AF. Modification of the Hunsuck sagittal split osteotomy using a nerve hook. Technical note. J Craniomaxillofac Surg 2002; 30: 292-4.
3. Kositbowornchai S, Siritapetawee M, Damrongrungruang T, Khongkankong W, Chatrchaiwiwatana S, Khamanarong K, et al. Shape of the lingual and its localization by panoramic radiograph versus dry mandibular measurement. Surg Radiol Anat 2007; 29:689-94.
4. Fabian FM. Observation of the position of the lingual in relation to the mandibular foramen and the mylohyoid groove. Ital J Anat Embryol 2006; 111: 151-8.
5. Kang SH, Byun IY, Kim JH, Park HK, Kim MK. Three-dimensional anatomic analysis of mandibular foramen with mandibular anatomic landmarks for inferior alveolar nerve block anesthesia. Oral Surg Oral Med Oral Pathol Oral Radiol 2013; 115: e17-23.
6. Thangavelu K, Kannan R, Kumar NS, Rethish E, Sabitha S, Sayeeganesh N. Significance of localization of mandibular foramen in an inferior alveolar nerve block. J Nat Sci Biol Med 2012; 3:156-60.
7. Monnazzi MS, Passeri LA, Gabrielli MF, Bolini PD, de Carvalho WR, da Costa Machado H. Anatomic study of the mandibular foramen, lingula and antilingula in dry mandibles, and its statistical relationship between the true lingula and the antilingula. Int J Oral Maxillofac Surg 2012; 41:74-8.
8. Keros J, Kobler P, Baucic I, Cabov T. Foramen mandibulae as an indicator of successful conduction anesthesia. Coll Antropol 2001; 25:327-31.
9. Jansisyanont P, Apinhasmit W, Chompoopong S. Shape, height, and location of the lingula for sagittal ramus osteotomy in Thais. Clin Anat 2009; 22: 787-93.
10. Aziz SR, Dorfman BJ, Ziccardi VB, Janal M. Accuracy of using the antilingula as a sole determinant of vertical ramus osteotomy position. J Oral Maxillofac Surg 2007; 65:859-62.
11. Fujimura K, Segami N, Kobayashi S. Anatomical study of the complications of intraoral vertical ramus osteotomy. J Oral Maxillofac Surg 2006; 64: 384-9.
12. da Fontoura RA, Vasconcellos HA, Campos AE. Morphologic basis for the intraoral vertical ramus

- osteotomy: anatomic and radiographic localization of the mandibular foramen. *J Oral Maxillofac Surg* 2002; 60: 660-5.
13. Laster WS, Ludlow JB, Bailey LJ, Hershey HG. Accuracy of measurements of mandibular anatomy and prediction of asymmetry in panoramic radiographic images. *Dentomaxillofac Radiol* 2005; 34:343-9.
 14. Kositbowornchai S, Siritapetawee M, Damrongrungruang T, Khongkankong W, Chatrchaiwiwatana S, Khamanarong K, et al. Shape of lingual and its localization by panoramic radiograph versus dry mandibular measurement. *Surg Radiol Anat* 2007; 29: 689-94.
 15. Ezoddini Ardakani F, Bahrololoumi Z, Zangouie Booshehri M, Navab Azam A, Ayatollahi F.. The position of lingula as an index for inferior alveolar nerve block injection in 7-11-year-old children. *J Dent Res Dent Clin Dent Prospects* 2010; 4: 47-51.
 16. Keetley A, Moles DR A clinical audit into the success rate of inferior alveolar nerve block analgesia in general dental practice. *Prim Dent Care* 2001; 8:139-42.
 17. Potocnik I, Bajrović F. Failure of inferior alveolar nerve block in endodontics. *Endod Dent Traumatol*. 1999; 15:247-51.
 18. Meechan JG. How to overcome failed local anaesthesia. *Br Dent J* 1999;186:15-20.
 19. Milles M. The missed inferior alveolar block: a new look at an old problem. *Anesth Prog* 1984; 31:87-90.
 20. Ashkenazi M, Taubman L, Gavish A. Age-associated changes of the mandibular foramen position in anteroposterior dimension and of the mandibular angle in dry human mandibles. *Anat Rec (Hoboken)* 2011; 294: 1319-25.