

## Impact of Endodontic Access Cavity Designs on Canal Transportation and Centering Ability in Mandibular Molars: An Ex Vivo Study

Moeine Mousavi<sup>1</sup> , Azadeh Harandi<sup>2</sup> , Ehsan Moudi<sup>3</sup> ,  
Hemmat Gholinia<sup>4</sup> , Ali Soleymani<sup>2\*</sup> 

1. Student Research Committee, Babol University of Medical Sciences, Babol, I.R.Iran.
2. Dental Materials Research Center, Health Research Institute, Babol University of Medical Sciences, Babol, I.R.Iran.
3. Oral Health Research Center, Health Research Institute, Babol University of Medical Sciences, Babol, I.R.Iran.
4. Health Research Institute, Babol University of Medical Sciences, Babol, I.R.Iran.

### Article type

### ABSTRACT

#### Research Paper

**Introduction:** The Contracted Endodontic Cavity (CEC) design emphasizes preserving tooth structure as an alternative to the Traditional Endodontic Cavity (TEC) design. However, this approach may result in canal transportation and reduced centering ability during cleaning and shaping. The aim of this study was to evaluate the effect of the CEC design on canal transportation and centering ability in mandibular molars using Cone-Beam Computed Tomography (CBCT).

**Materials & Methods:** In this ex vivo study, 30 mandibular molars with mature roots and closed apices were randomly assigned to two groups: TEC and CEC. All root canals were cleaned and shaped. Canal transportation and centering ability were assessed at 1-, 3-, and 5-millimeter intervals from the apex, following Gambill's method. Data were analyzed using the Kruskal-Wallis and Mann-Whitney tests.

**Results:** Canal transportation was significantly greater in the CEC group compared to the TEC group for both mesio-buccal and distal canals at 1 mm ( $P=0.04$  and  $P=0.022$ , respectively), 3 mm ( $P=0.021$  and  $P=0.019$ , respectively), and 5 mm ( $P=0.04$  and  $P=0.013$ , respectively) from the apex. In contrast, centering ability was significantly lower in the CEC group compared to the TEC group for both mesio-buccal and distal canals at 1 mm ( $P=0.011$  and  $P=0.032$ , respectively), 3 mm ( $P=0.035$  and  $P=0.001$ , respectively), and 5 mm ( $P=0.005$  and  $P=0.001$ , respectively) from the apex. No significant differences in canal transportation or centering ability were observed between the mesio-buccal and distal canals within each group, nor at different levels within the same canal.

**Conclusion:** According to the results of the present study, the TEC design provides better preservation of canal anatomy during the cleaning and shaping process.

**Keywords:** Endodontics, Root Canal Preparation, Root Canal Therapy, Cone-Beam Computed Tomography

**Received:** 8 Oct 2025

**Revised:** 25 Nov 2025

**Accepted:** 19 May 2026

**Pub. online:** 23 May 2026

**Cite this article:** Mousavi M, Harandi A, Moudi E, Bagheri T, Gholinia H, Soleymani A. Impact of Endodontic Access Cavity Designs on Canal Transportation and Centering Ability in Mandibular Molars: An Ex Vivo Study. *Caspian J Dent Res.* 2025; 14: 49-58.



© The Author(s).

Publisher: Babol University of Medical Sciences

### Introduction

The primary goal of root canal therapy is the long-term preservation of teeth in a healthy and functional state [1]. However, some endodontically treated teeth - particularly maxillary

\* **Corresponding Author:** Ali Soleymani, Department of Endodontics, School of Dentistry, Babol University of Medical Sciences, Noushirvani Blvd., Babol, Mazandaran, Iran.

**Tel:** +981132291408

**E-mail:** soleymani\_ali@yahoo.com

premolars and mandibular molars - may eventually require extraction due to fractures or extensive decay, with mechanical stress being a major contributing factor [2, 3].

Loss of dentin during access cavity preparation is a key risk factor for tooth fracture [4]. The Traditional Endodontic Cavity (TEC), which involves complete removal of the pulp chamber roof to facilitate canal access and instrumentation, has remained largely unchanged for decades [3, 5, 6].

In contrast, the Contracted Endodontic Cavity (CEC) was introduced to preserve coronal dentin by retaining part of the pulp chamber ceiling, thereby maintaining structural integrity and reducing susceptibility to fracture [7-9].

While inadequate access design may hinder canal location, negotiation, debridement, disinfection, and obturation [3], studies suggest that the CEC can improve fracture resistance in certain teeth, although it may complicate cleaning and shaping procedures in mandibular molars [1, 3, 10].

Canal transportation is a common procedural complication during cleaning and shaping, often resulting from limited access to the apical third or canal curvature [11, 12]. This displacement of the canal path compromises cleaning efficiency and may adversely affect treatment prognosis [12, 13].

Cone Beam Computed Tomography (CBCT) provides a reliable, non-invasive method for evaluating canal morphology and preparation-induced changes, enabling precise three-dimensional assessment of canal transportation without altering the original anatomy [14-16]. Given that the effect of the CEC on different teeth may vary, there is a need for a comprehensive investigation into its impact on treatment outcomes and procedural errors. The present study aims to evaluate the effect of the CEC on canal transportation and centering ability in the mesio-buccal and distal canals of mandibular molars using CBCT.

## Materials & Methods

This *ex vivo* study was conducted on mandibular molars that were extracted for various reasons and had fully matured roots. The study protocol was approved by the Ethics Committee of Babol University of Medical Sciences (IR.MUBABOL.HRI.REC.1397.197). The inclusion criteria were pulp chamber height greater than 2 mm, root canal lengths between 19 and 22 mm, and canal curvature between 10 and 25 degrees, as measured using the Schneider method (canal curvature was measured after placement of the initial file). Teeth with decay, restorations, previous root canal treatments, fractures, root resorption, or any other anomalies were excluded [9, 11].

The minimum sample size was calculated based on the results of a previous study by Asha et al. [17], considering a study accuracy of 95% ( $\alpha=0.05$ ) and a power of 80% ( $\beta=0.2$ ), with 15 samples per group. A total of 43 mandibular molars with mature roots, closed apices, and free from decay, restorations, previous root canal treatments, fractures, root resorption, or other anomalies were collected. The teeth were disinfected for 1 hour in a 5.25% sodium hypochlorite solution and stored in normal saline at 4°C until the study was conducted [9].

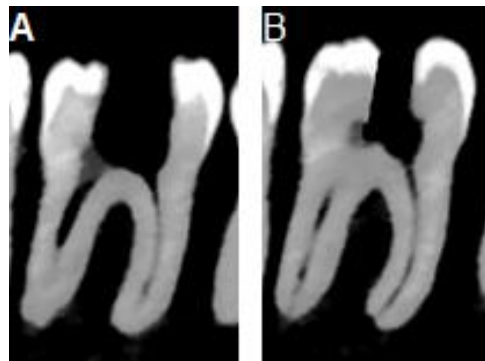
The teeth were mounted in a standardized manner, both vertically and horizontally, in a wax block up to the cemento-enamel junction (CEJ). CBCT scans were then acquired using a

Newtom 5G device (Newtom, Verona, Italy) with a field of view (FOV) of 6×8 cm and a voxel size of 75 microns. The anatomical characteristics of the teeth, along with the inclusion criteria, were reviewed, and any teeth that did not meet the inclusion criteria were excluded from the study. Ultimately, 30 teeth met the criteria and were included in the analysis.

The teeth were randomly divided into two groups, and access cavities were prepared under dental loupes (ML4 LED HeadLight with HR/HRP Binocular Loupes, Heine, Germany) with 2.5X magnification:

**TEC Group:** It was prepared according to conventional guidelines. The pulp chamber ceiling was completely removed, and direct access to the apical third of the root canal was created [9].

**CEC Group:** It was prepared on the mesial side relative to the central fossa. The cavity was extended apically and distally while preserving part of the pulp chamber ceiling. The mesiodistal, buccolingual, and circumferential removal of coronal dentin was minimized, extending only enough to maintain part of the pulp chamber ceiling and allow identification of the root canal orifices. The occlusal enamel was beveled at a 45-degree angle. The extent of the access cavity between the buccal and lingual orifices was unequal, with the cavity slightly tilted toward the buccal side [5, 18]. The sample CBCT images of the teeth after preparation of each access cavity is shown in Figure 1.

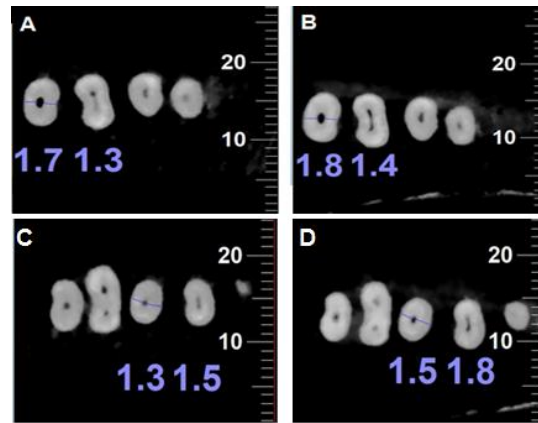


**Figure 1.** CBCT images of the teeth; A: Traditional Endodontic Access Cavity (TEC) design; B: Contracted Endodontic Access Cavity (CEC) design.

The canals were negotiated using size 10 K-files (Dentsply Maillefer, Ballaigues, Switzerland). To determine the working length, a size 15 file (Dentsply Maillefer, Ballaigues, Switzerland) was inserted into the canal, and radiographs were taken to measure the working length, which was set 1 mm shorter than the apex. Canal curvature was calculated using the Schneider method. Teeth that did not meet the inclusion criteria were excluded, resulting in 15 teeth in each group.

The root canals were cleaned and shaped according to the manufacturer's instructions using ProTaper Gold rotary files (Dentsply Maillefer, Ballaigues, Switzerland) with an NSK ENDO-MATE DT motor. Irrigation was performed with 2.5% sodium hypochlorite (Domestons, Alvand, Iran). Canal preparation was performed using file F2 for the mesio-buccal canal and file F3 for the distal canal, with RC-Prep (Dentsply Maillefer, Ballaigues, Switzerland) as the lubricant [19].

After preparation, CBCT scans were repeated using the same parameters for each sample. Canal transportation and centering ability were assessed using the Show Distances Toolbar in Newton Viewer software (Cefla S.C., Imola, Italy) at three horizontal sections: 1, 3, and 5 mm from the apex of the root (Figure 2).



**Figure 2.** Axial section images before (B) and after (A) canal preparation without transportation in the TEC group, and before (D) and after (C) canal preparation with transportation in the CEC group.

### Measurement of Canal Transportation

Canal transportation was evaluated using the method described by Gambill et al. with the following formula:

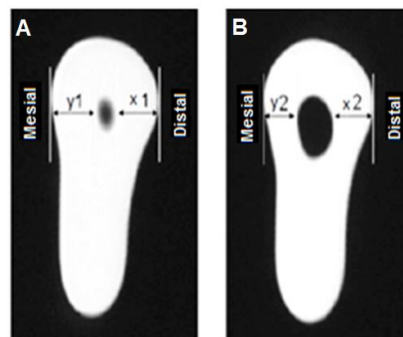
$$(Y_1 - Y_2) - (X_1 - X_2)$$

Where:

**X<sub>1</sub> and Y<sub>1</sub>:** The minimum distance from the external root surface to the distal and mesial unprepared canal wall.

**X<sub>2</sub> and Y<sub>2</sub>:** The minimum distance from the external root surface to the distal and mesial prepared canal wall (Figure 3).

A result of zero indicates no transportation, while any deviation from zero signifies canal transportation [20].



**Figure 3.** Schematic representation of the values X<sub>1</sub>, X<sub>2</sub>, Y<sub>1</sub>, and Y<sub>2</sub>, before (A) and after (B) canal preparation.

### Measurement of Canal Centering Ability

Canal centering ratio was evaluated using the following formula:

$$\frac{Y_1 - Y_2}{X_1 - X_2} \quad \text{or} \quad \frac{X_1 - X_2}{Y_1 - Y_2}$$

If the result of the fraction is 1, it indicates that centralization has not changed and the instrument has remained perfectly centered. The closer this value is to zero, the less ability the file has to remain centered in the canal [9].

### Statistical analysis

The data were analyzed using SPSS software (IBM Corp., Armonk, NY, USA), version 26. To compare the mean canal transportation and centering ability at the 1, 3, and 5 mm root sections from the apex based on access cavity design, as well as within each access cavity design according to canal type, the Mann-Whitney U test was applied. To compare differences between sections, the Kruskal-Wallis test was used. A p-value less than 0.05 was considered statistically significant.

### Results

The mean canal curvature of the mesio-buccal canal in the TEC and CEC groups was  $19 \pm 2.6^\circ$  and  $17.8 \pm 3.8^\circ$ , respectively, while the mean curvature of the distal canal was  $18.1 \pm 2.5^\circ$  and  $16.7 \pm 4.1^\circ$ , respectively. No statistically significant difference was observed in the curvatures of the mesio-buccal and distal canals between the two groups. In this case study, no rotary file separation occurred during instrumentation.

The mean and standard deviation values for canal transportation and centering ratio at the 1, 3, and 5 mm root sections for the mesio-buccal and distal canals are presented in Table 1.

**Table 1.** Comparison of mean canal transportation (mm) and centering ratio between different access cavity designs of mesio-buccal and distal canals at 1, 3, and 5 mm apical sections

Canal	Section	Access Cavity	Transportation	p-value*	Centering Ratio	p-value*
Mesio-buccal	1 mm	TEC	0.02 ± 0.04	0.040	0.921 ± 0.16	0.011
		CEC	0.104 ± 0.05		0.502 ± 0.48	
	3 mm	TEC	0.04 ± 0.06	0.021	0.897 ± 0.16	0.035
		CEC	0.121 ± 0.07		0.463 ± 0.48	
	5 mm	TEC	0.053 ± 0.08	0.040	0.899 ± 0.15	0.005
		CEC	0.14 ± 0.12		0.48 ± 0.42	
Distal	1 mm	TEC	0.027 ± 0.04	0.022	0.906 ± 0.16	0.032
		CEC	0.106 ± 0.06		0.5 ± 0.5	
	3 mm	TEC	0.053 ± 0.08	0.019	0.883 ± 0.17	0.001
		CEC	0.147 ± 0.11		0.383 ± 0.43	
	5 mm	TEC	0.067 ± 0.10	0.013	0.847 ± 0.23	0.001
		CEC	0.18 ± 0.12		0.37 ± 0.37	

\*Mann-Whitney Test

The minimum canal transportation was observed in the mesio-buccal canal at the 1 mm apical section in the TEC group, while the maximum canal transportation occurred in the distal canal at the 5 mm apical section in the CEC group. Additionally, the minimum centering ratio was observed in the distal canal at the 5 mm apical section in the CEC group, while the maximum centering ratio was observed in the mesio-buccal canal at the 1 mm apical section in the TEC group.

Statistically significant differences between the TEC and CEC groups were observed in both the mesio-buccal and distal canals at all three apical sections, with the CEC group exhibiting greater canal transportation and poorer centering ability compared to the TEC group.

When comparing the mean canal transportation and centering ratio of the mesio-buccal and distal canals across the 1, 3, and 5 mm apical sections within each access cavity design, no statistically significant differences were found (Table 2).

**Table 2.** Comparison of mean canal transportation and centering ratio of mesio-buccal and distal canals between 1, 3, and 5 mm apical sections within each access cavity design

Canal	Access Cavity	Section	Transportation	p-value*	Centering Ratio	p-value*
Mesio-buccal	TEC	1 mm	0.02 ± 0.04	0.53	0.921 ± 0.16	0.81
		3 mm	0.04 ± 0.06		0.897 ± 0.16	
		5 mm	0.053 ± 0.08		0.899 ± 0.15	
	CEC	1 mm	0.104 ± 0.05	0.12	0.502 ± 0.48	0.46
		3 mm	0.121 ± 0.07		0.463 ± 0.48	
		5 mm	0.14 ± 0.12		0.48 ± 0.42	
Distal	TEC	1 mm	0.027 ± 0.04	0.68	0.906 ± 0.16	0.78
		3 mm	0.053 ± 0.08		0.883 ± 0.17	
		5 mm	0.067 ± 0.10		0.847 ± 0.23	
	CEC	1 mm	0.106 ± 0.06	0.21	0.5 ± 0.5	0.83
		3 mm	0.147 ± 0.11		0.383 ± 0.43	
		5 mm	0.18 ± 0.12		0.37 ± 0.37	

\*Kruskal-Wallis Test

No statistically significant differences were found between the mesio-buccal and distal canals within each group, based on the type of access cavity and section (Table 3).

**Table 3.** Comparison of mean canal transportation and centering ratio based on canal type (mesio-buccal vs. distal) at 1, 3, and 5 mm apical sections within each access cavity design

Access Cavity	Section	Canal	Transportation	p-value*	Centering Ratio	p-value*
TEC	1 mm	Mesio-buccal	0.02 ± 0.04	0.67	0.921 ± 0.16	0.73
		Distal	0.027 ± 0.04		0.906 ± 0.16	
	3 mm	Mesio-buccal	0.04 ± 0.06	0.8	0.897 ± 0.16	0.72
		Distal	0.053 ± 0.08		0.883 ± 0.17	
	5 mm	Mesio-buccal	0.053 ± 0.08	0.84	0.899 ± 0.15	0.65
		Distal	0.067 ± 0.10		0.847 ± 0.23	
CEC	1 mm	Mesio-buccal	0.104 ± 0.05	0.39	0.502 ± 0.48	0.45
		Distal	0.106 ± 0.06		0.5 ± 0.5	
	3 mm	Mesio-buccal	0.121 ± 0.07	0.21	0.463 ± 0.48	0.31
		Distal	0.147 ± 0.11		0.383 ± 0.43	
	5 mm	Mesio-buccal	0.14 ± 0.12	0.35	0.48 ± 0.42	0.45
		Distal	0.18 ± 0.12		0.37 ± 0.37	

\*Mann-Whitney Test

## Discussion

The results of the present study demonstrate that canal transportation was significantly greater in both the mesio-buccal and distal canals at all three levels (1 mm, 3 mm, and 5 mm from the apex) in the CEC group compared to the TEC group. In contrast, the centering ability was significantly superior in the TEC group at all three levels for both the mesio-buccal and distal canals. These findings suggest that the CEC had a negative impact on both canal displacement and centering ability in the mesio-buccal and distal canals of mandibular molars.

This may be explained by the conservative nature of CEC preparation, which preserves part of the pulp chamber ceiling. While this is structurally beneficial, it can create coronal interference and compromise straight-line access to the canal or its initial curvature [21]. Limited access increases pressure on the outer canal wall, particularly in the apical region, leading to excessive dentin removal and transportation [9, 11]. In this study, access preparation was performed under magnification to minimize operator-related interference.

Our findings are consistent with previous studies. Kishan et al. reported that conventional access better preserved canal anatomy compared to truss cavities, although their evaluation was limited to mesial canals [7]. Similarly, Alovizi et al. found that TEC preserved canal geometry better and resulted in less transportation during shaping [11]. Rover et al., studying maxillary molars, also reported greater transportation and reduced centering ability in CEC groups [9].

A notable limitation of their study was the lack of specification regarding the method used to standardize canal curvature, which could represent a confounding factor, as increased canal curvature is known to exacerbate transportation and reduce centering ability.

Although not statistically significant, transportation was greater in distal canals than in mesio-buccal canals, while centering ability was superior in mesio-buccal canals. This may be related to the use of larger and less flexible F3 files (30#, 0.09 taper) in distal canals compared to F2 files (25#, 0.08 taper) in mesio-buccal canals. Larger tapers reduce flexibility and may increase transportation. Additionally, transportation and loss of centering ability increased with distance from the apex, likely due to the greater taper of the shaping files.

Moore et al. found no difference between TEC and CEC in canal wall alteration <sup>[1]</sup>, possibly due to their use of smaller, more flexible instruments (0.06 taper), which exert less pressure on canal walls <sup>[9]</sup>. In contrast, Asha et al. reported improved centering and reduced transportation with conservative designs <sup>[17]</sup>; however, they used different file systems with smaller tapers, which may explain the discrepancy.

Since canal geometry strongly influences preparation outcomes, preoperative anatomical assessment is essential <sup>[22]</sup>. CBCT provides a reliable, non-destructive method for evaluating canal morphology before and after preparation <sup>[18, 23]</sup>, though its accuracy depends on appropriate voxel size selection <sup>[24]</sup>.

Both mesio-buccal and distal canals were included due to the reported prevalence of type II canals in mesial roots <sup>[25]</sup>. The mesio-buccal canal was selected for analysis because it typically offers less direct access to the apex, allowing for a more challenging evaluation. ProTaper Gold files were used due to their enhanced fatigue resistance while maintaining similar geometry to ProTaper Universal instruments <sup>[26]</sup>.

Although CEC preserves more tooth structure, the resulting coronal interference may compromise shaping quality. The findings of this study suggest that CEC increases canal displacement and reduces centering ability, highlighting the need for further refinement of conservative access designs to balance structural preservation with procedural accuracy.

## Conclusion

Based on the results of the present study, the traditional endodontic cavity is more effective in preserving the original canal anatomy during the shaping process than the contracted endodontic cavity.

## Acknowledgments

The authors express their sincere gratitude and appreciation to the staff of Dental Materials Research Center for their help during this study.

## Conflict of interest

The authors declare no potential conflict of interest with respect to the authorship or publication of this paper.

## Author's Contribution

Moeine Mousavi: Conducted the project work, collected data, and drafted the manuscript. Azadeh Harandi: Conceptualization and design. Ehsan Moudi: Conceptualization and design.

Hemmat Gholinia: Formal data analysis. Ali Soleymani: Supervised the project and revised the manuscript. All authors read and approved the final manuscript.

## References

1. Moore B, Verdelis K, Kishen A, Dao T, Friedman S. Impacts of contracted endodontic cavities on instrumentation efficacy and biomechanical responses in maxillary molars. *Journal of endodontics*. 2016;42:1779-83.
2. Touré B, Faye B, Kane AW, Lo CM, Niang B, Boucher Y. Analysis of reasons for extraction of endodontically treated teeth: a prospective study. *Journal of endodontics*. 2011;37:1512-5.
3. Hargreaves KM, Berman LH, Rotstein I. Cohen's pathways of the pulp. 11 ed. 11, editor2016.
4. Silva EJNL, Rover G, Belladonna FG, De-Deus G, da Silveira Teixeira C, da Silva Fidalgo TK. Impact of contracted endodontic cavities on fracture resistance of endodontically treated teeth: a systematic review of in vitro studies. *Clinical oral investigations*. 2018;22:109-18.
5. Plotino G, Grande NM, Isufi A, Ioppolo P, Pedullà E, Bedini R, et al. Fracture strength of endodontically treated teeth with different access cavity designs. *Journal of endodontics*. 2017;43:995-1000.
6. Barbosa AFA, Silva E, Coelho BP, Ferreira CMA, Lima CO, Sassone LM. The influence of endodontic access cavity design on the efficacy of canal instrumentation, microbial reduction, root canal filling and fracture resistance in mandibular molars. *International Endodontic Journal*. 2020;53:1666-79.
7. Kishan KV, Savaliya K, Shroff M, Saklecha P. Comparative evaluation of the effect of conventional and truss access cavities on remaining dentin thickness, canal transportation, and canal centering ability in mandibular molars using cone-beam computed tomography. *Endodontology*. 2023;35:137-41.
8. Neelakantan P, Khan K, Hei Ng GP, Yip CY, Zhang C, Pan Cheung GS. Does the Orifice-directed Dentin Conservation Access Design Debride Pulp Chamber and Mesial Root Canal Systems of Mandibular Molars Similar to a Traditional Access Design? *Journal of endodontics*. 2018;44:274-9.
9. Rover G, Belladonna FG, Bortoluzzi EA, De-Deus G, Silva EJNL, Teixeira CS. Influence of access cavity design on root canal detection, instrumentation efficacy, and fracture resistance assessed in maxillary molars. *Journal of endodontics*. 2017;43:1657-62.
10. Shroff M, Kishan KV, Shah N, Saklecha P. Impact of contracted endodontic cavities on instrumentation efficacy—A systematic review. *Australian Endodontic Journal*. 2023;49:202-12.
11. Alovise M, Pasqualini D, Musso E, Bobbio E, Giuliano C, Mancino D, et al. Influence of contracted endodontic access on root canal geometry: an in vitro study. *Journal of endodontics*. 2018;44:614-20.
12. Karabucak B, Gatan AJ, Hsiao C, Iqbal MK. A comparison of apical transportation and length control between EndoSequence and Guidance rotary instruments. *Journal of endodontics*. 2010;36:123-5.
13. Schäfer E, Dammaschke T. Development and sequelae of canal transportation. *Endodontic topics*. 2006;15:75-90.
14. Bernardes RA, Rocha EA, Duarte MAH, Vivian RR, de Moraes IG, Bramante AS, et al. Root canal area increase promoted by the EndoSequence and ProTaper systems: comparison by computed tomography. *Journal of Endodontics*. 2010;36:1179-82.
15. Estrela C, Bueno MR, Sousa-Neto MD, Pécora JD. Method for determination of root curvature radius using cone-beam computed tomography images. *Brazilian Dental Journal*. 2008;19:114-8.
16. Gergi R, Rjeily JA, Sader J, Naaman A. Comparison of canal transportation and centering ability of twisted files, Pathfile-ProTaper system, and stainless steel hand K-files by using computed tomography. *Journal of Endodontics*. 2010;36:904-7.
17. Asha K, Ghivari S, Pujar M, Sait S. Comparative evaluation of different endodontic access cavity designs on canal transportation and centering ability using bondent platinum file system on mandibular molar – An in vitro cone-beam computed tomography study. *Endodontology*. 2025;37:39-43.
18. Bóveda C, Kishen A. Contracted endodontic cavities: the foundation for less invasive alternatives in the management of apical periodontitis. *Endodontic Topics*. 2015;33:169-86.
19. Arslan H, Yildiz ED, Gunduz HA, Sumbullu M, Bayrakdar IS, Karatas E, et al. Comparative study of ProTaper gold, reciproc, and ProTaper universal for root canal preparation in severely curved root canals. *Journal of conservative dentistry: JCD*. 2017;20:222-4.
20. Gambill JM, Alder M, del Rio CE. Comparison of nickel-titanium and stainless steel hand-file instrumentation using computed tomography. *Journal of endodontics*. 1996;22:369-75.

21. Saygili G, Uysal B, Omar B, Ertas ET, Ertas H. Evaluation of relationship between endodontic access cavity types and secondary mesiobuccal canal detection. *BMC oral health*. 2018;18:121.
22. Peters OA, Laib A, Göhring TN, Barbakow F. Changes in root canal geometry after preparation assessed by high-resolution computed tomography. *Journal of Endodontics*. 2001;27:1-6.
23. Hartmann MSM, Barletta FB, Fontanella VRC, Vanni JR. Canal transportation after root canal instrumentation: a comparative study with computed tomography. *Journal of endodontics*. 2007;33:962-5.
24. Sberna M, Rizzo G, Zacchi E, Cappare P, Rubinacci A. A preliminary study of the use of peripheral quantitative computed tomography for investigating root canal anatomy. *International endodontic journal*. 2009;42:66-75.
25. Madani ZS, Mehraban N, Moudi E, Bijani A. Root and canal morphology of mandibular molars in a selected Iranian population using cone-beam computed tomography. *Iranian endodontic journal*. 2017;12:143.
26. Pereira F, Martins RF, Ginjeira A. Cyclic fatigue resistance of ProTaper Gold and comparison with ProTaper Universal instruments. *Rev Port Estomatol Med Dent Cir Maxilofac*. 2018;59:75-9.