

Multiple mucous retention cysts of the oral mucosa and lower lip: A rare entity

Faezeh Khozeimeh ^{1✉}, Fatemeh Abbasi ^{2✉}, Sabra Forootan ^{3*}

1. Associate Professor, Department of Oral and Maxillofacial Diseases, Dental Research Center, Dental Research Institute, School of Dentistry, Isfahan University of Medical Sciences, Isfahan, Iran.

2. Assistant Professor, Department of Oral and Maxillofacial Diseases, Dental Research Center, Dental Research Institute, School of Dentistry, Isfahan University of Medical Sciences, Isfahan, Iran.

3. Postgraduate Student, Student Research Committee, Isfahan University of Medical Sciences, Isfahan, Iran.

Article type

ABSTRACT

Case Report

Multiple mucous retention cysts are relatively rare conditions, particularly on the lower lip. This case report presents a 60-year-old man with multiple swelling structures located in the right and left buccal mucosa, and lower labial mucosa. A biopsy was done, and a histologic assessment confirmed dilation of minor salivary ducts and cystic formation. Several factors may interfere with the creation of this uncommon phenomenon, such as alteration in salivary secretion, and congenital or acquired weakness in the ductal structure. In addition, it is suggested that ductal narrowing may be due to the long-term application of some mouthwash containing hydrogen peroxide, deodorant also anti-plaque, and tartar-control toothpaste.

Received: 17 Jul 2023

Revised: 25 Aug 2023

Accepted: 21 Sept 2023

Pub. online: 30 Sept 2023

Keywords: Cysts, Mouth Mucosa, Lip

Cite this article: Khozeimeh F, Abbasi F, Forootan S. Multiple mucous retention cysts of the oral mucosa and lower lip: A rare entity. *Caspian J Dent Res* 2023; 12:99-103.



© The Author(s).

Publisher: Babol University of Medical Sciences

Introduction

Mucous retention cysts are cyst-like dilatation of salivary ducts that may develop secondary to ductal obstruction (e.g., mucus plug) due to abnormally viscous saliva, which creates increased intraluminal pressure or due to an anomaly of the ducts. Such lesions probably represent salivary ductal ectasia rather than a true cyst. A mucous retention cyst is different from a Mucocele. Mucocele is swelling with the accumulation of saliva probably caused by trauma or obstruction of ductal minor salivary glands. ^[1-3] Although mucocele is often called a mucous retention cyst, this is a misnomer as the mucocele does not have an epithelial lining. Multiple mucous retention oral cysts are very rare or published with other names. Therefore, diagnosis is important to avoid multiple unnecessary surgical operations. Multiple mucous retention oral cysts were reported by Kuffer et al. in 2006 ^[3], Jahanshahi

* **Corresponding Author:** Sabra Forootan, Department of Oral and Maxillofacial Diseases, School of Dentistry, Isfahan University of Medical Sciences, Isfahan, Iran.

Tel: +98 9163232368

E-mail: dr.sabra.forootan1370@gmail.com

et al. in 2007 ^[4], and Tal et al. in 1984. ^[5] In this article, we present a 60-year-old man with multiple swelling structures located in the oral cavity which had caused the patient's phobia about its malignancy.

Case Report

This project was approved by the Ethics Committee of Isfahan University of Medical Sciences (ethical code: IR.MUI.RESEARCH.REC.1400.311). A 60-year-old male patient with a chief complaint of multiple small exophytic lesions in the buccal and labial oral mucosa was referred to the Oral and Maxillofacial Medicine Department of Dental School of Isfahan University of Medical Sciences in November 2019. These lesions had been first observed through himself approximately two years ago.

The patient has been edentulous since 2010. In his medical history assessment, non-insulin-dependent diabetes mellitus (type 2), hyperlipidemia, and anxiety and nervous condition were recorded, and the patient had taken Metformin (500 mg), Atorvastatin (20 mg), Clonazepam (1 mg) once a day. There was no familial history of similar oral lesions, and no traumatic accident or parafunctional habits. The extraoral examination confirmed not anything relevant only the oral mucosa was atrophic and dry. In the oral exam, multiple small nodules varying in size from a few millimeters to one centimeter in diameter were scattered in the right and left buccal mucosa and lower labial mucosa (Figures 1a and b). The upper lip was normal.

The nodules were sessile, non-tender, pink, smooth in surface, firm in palpation, unchangeable in size, and painless. On application of pressure, no secretion was seen from the nodules. The other part of the oral mucosa was normal.

According to the clinical features, the first differential diagnosis was Cheilitis Glandularis, papillary cystadenoma, intraoral warthin tumor, and the last was mucous retention cyst. According to the first item on the differential diagnosis list, these lesions were first conservatively treated with an Intralesional injection of Triamcinolone acetonide (10 mg/mL) twice a week, however, follow-up visits reveal no significant improvement. Unfortunately, the pandemic of COVID-19 happened, and the patient didn't return for his monthly check-up.

He returned by May 2021 and became very anxious about the malignant nature of his lesions and had discomfort during eating and speaking. Thus, a biopsy was scheduled to remove five closely spaced nodules under local anesthesia and histological examination revealed a section of minor salivary gland tissue, composed of acinar or mucous secretion cells and dilated ducts arising from cystic cavities with atrophic stratified epithelial lining (Figure 2 a and b). In conclusion, the final diagnosis of multiple mucous retention cysts was made. Figure 3 shows oral mucosa after 10 days of follow-up. Due to the elimination of the patient's cancer phobia and his unwillingness to remove all the nodules, no additional treatment was performed.

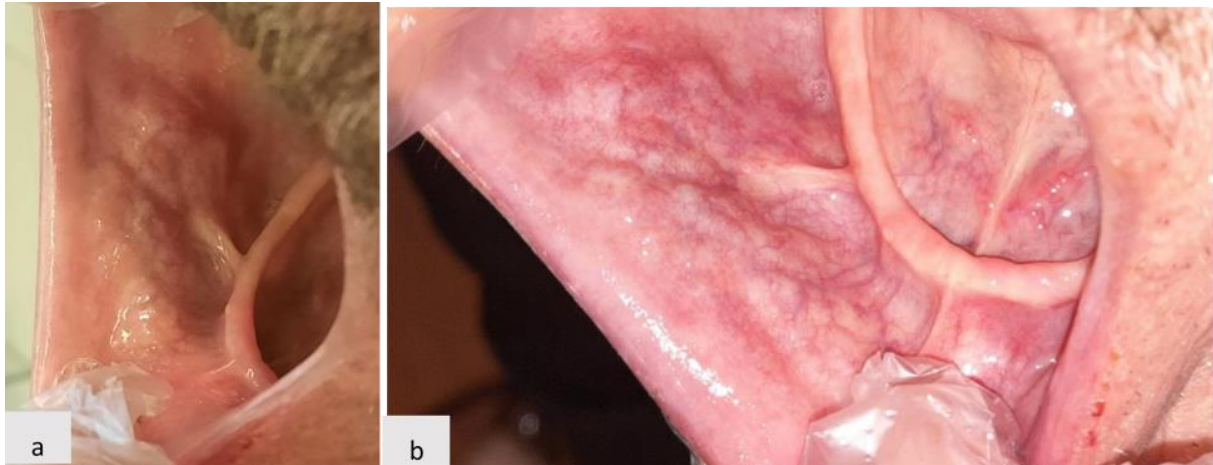


Figure 1. Multiple small nodules varying in size from a few millimeters to one centimeter in diameter were scattered in the right and left buccal mucosa (a) and lower labial mucosa (b)

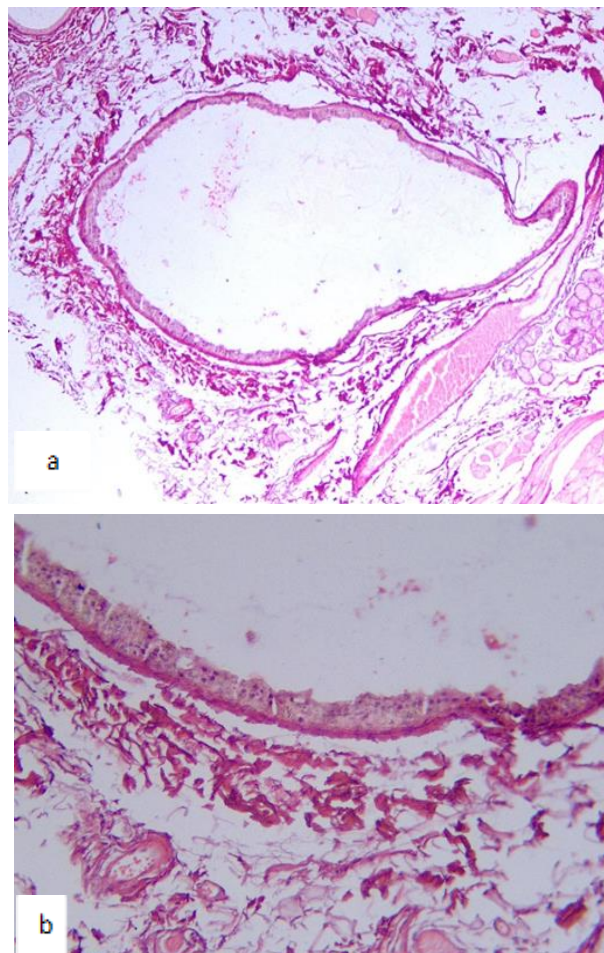


Figure 2. A. Dilated excretory duct. Section of minor salivary gland tissue, composed of acinar or mucous secretion cells and dilated ducts arising from cysts. (H&E stain, original magnification, X4) B. Dilated duct orifice with secretory columnar epithelium (H&E stain, original magnification, X40)

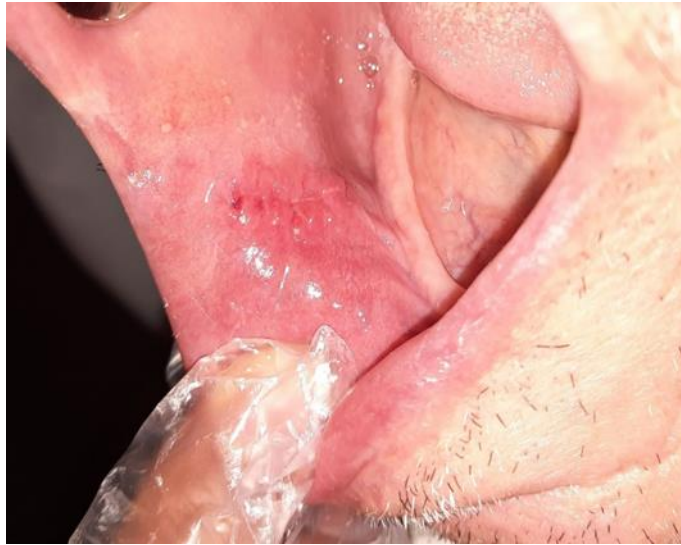

Figure 3. After 10 days of follow-up

Discussion

In the present case with multiple swelling in the buccal and lower lip mucosa, the differential diagnosis list includes Cheilitis glandularis, papillary cystadenoma, intraoral Warthin tumor, and mucous retention cyst.

The first suggestion was Cheilitis glandularis which is a chronic inflammatory disorder affecting the minor salivary glands and their ducts. [1] So conservative treatment of intralesional injection of Triamcinolone acetonide was made, but not receiving any response did not visit the clinic because of Covid pandemic. He came after two years with a complaint of cancer phobia of his lesions. So, we decided to remove five nodules for the biopsy specimen, and a definitive diagnosis of a mucous retention cyst was established. Histological examination revealed a section of minor salivary gland tissue, composed of acinar and mucous secretion cells and dilated ducts arising from cystic cavities with atrophic stratified epithelial lining. Although the dilatation of salivary ducts may occur in Cheilitis glandularis, cyst formation has not been described. [6] In this case, there was neither lymphocytic proliferation nor papillary enfolding in the cyst wall. So intra-oral Warthin's tumor and papillary cystadenoma were excluded respectively. [7]

Excitingly, this was the second case of multiple mucous retention cysts, referred to our department. The first referral case with this disorder was described by Jahanshahi et al. in 2007. [4] Determination of the true incidence of multiple mucous retention cysts is difficult because these lesions are uncommon. They are often not biopsied, not reported, or published with other names. As it was mentioned, only a few cases of multiple mucous retention cysts were reported in the literature. [3-5]

Multiple mucous retention cysts in this case may be due to cystic formation from dilation of the minor salivary gland duct. In addition, it is suggested that ductal narrowing may be due to the long-term application of some mouthwash containing hydrogen peroxide, deodorant anti-plaque, and tartar-control toothpaste [8] but this patient did not use such items.

Tal et al. concluded that multiple mucous retention cysts may be induced by the alteration of minor salivary gland secretion to very tenacious and viscid mucous or as a result of congenital or acquired weakness in the ductal structure that may lead to stasis of the secretion in the dilated ducts. [5] Since there

were no clinical signs of inflammation around the nodules, heat or traumatic incidence secondary to heavy smoking were excluded. However, more investigations are needed to establish a possible explanation for this rare phenomenon.

In this present case, chronic minor trauma due to being edentulous for over 10 years and not using complete dentures, and cystic dilatation of minor salivary glands excretory ducts caused these lesions. The patient's phobia of malignancy was resolved when a pathology report was explained to him, and no additional treatment was necessary.

Author's Contribution

Faezeh Khozeimeh accomplished the Study concept and design, manuscript preparation, patient examination, and study supervision, and reviewed the article. Fatemeh Abbasi collected data and patient examination and reviewed the article. Sabra Forootan performed the patient examination, drafted the manuscript, and edited and reviewed the article.

References

1. Bowers L M, Vissink A, Brennan M T. Salivary Gland Diseases. In: Glick M, Greenberg MS, Lockhart PB, Challacombe SJ, editors. 13th ed. New York: wiley; 2021.p. 303-7.
2. Neville BW, Damm DD, Allen CM, Chi AC. Oral and maxillofacial pathology. 4th ed. St. louis: Missouri; 2016.p. 425-7.
3. Kuffer R, Husson C, Plantier F, Samson J, Lombardi T. Rare cases of multiple retention cysts of minor salivary glands. Proceeding of the 13th International Congress of Oral Pathology and Medicine; 2006; Geneva, Switzerland or: J Oral Pathol Med (2006)35, 414-58.
4. Jahanshahi G, Shirani AM, Khozeimeh F. Multiple Mucous Retention Cysts (Mucocele) of the Oral Mucosa: A Case Report. Dent Res J 2007;4:111-3.
5. Tal H, Altini M, Lemmer J. Multiple mucous retention cysts of the oral mucosa. Oral Surg Oral Med Oral Pathol 1984; 58:692-5.
6. Stoopler ET, Carrasco L, Stanton DC, Pringle G, Sollecito TP. Cheilitis glandularis: an unusual histopathologic presentation. Oral Surg Oral Med Oral Pathol Oral Radiol Endod 2003;95:312-7.
7. Goto M, Ohnishi Y, Shoji Y, Wato M, Kakudo K. Papillary oncocytic cystadenoma of a palatal minor salivary gland: A case report. Oncol Lett 2016;11:1220-2.
8. Tandon A, Sircar K, Chowdhry A, Bablani D. Salivary duct cyst on lower lip: a rare entity and literature review. J Oral Maxillofac Pathol 2014;18(Suppl 1):S151-6.