

## Relationship between palatal canine impaction and sella turcica bridging

Nedasadat Tavooosi<sup>1</sup>, Mehdi Rafiei<sup>2\*</sup>, Eilnaz Ehrami<sup>3</sup>, Nasim Jafari Pozveh<sup>4</sup>

1. Dental Student, Faculty of Dentistry, Isfahan (Khorasgan) Branch, Islamic Azad University, Isfahan, Iran.
2. Assistant Professor, Department of Orthodontics, Faculty of Dentistry, Isfahan (Khorasgan) Branch, Islamic Azad University, Isfahan, Iran.
3. Postgraduate Student, Department of Orthodontics, Faculty of Dentistry, Isfahan (Khorasgan) Branch, Islamic Azad University, Isfahan, Iran.
4. Assistant Professor, Department of Oral & Maxillofacial Radiology, Faculty of Dentistry, Isfahan (Khorasgan) Branch, Islamic Azad university, Isfahan, Iran.

### Article type

Research Paper

### ABSTRACT

**Introduction:** After the third molars, the maxillary canines are the most frequently impacted teeth. Sella turcica bridging (STB) can be used as a predictive factor to help orthodontists in early diagnosis. The aim of this study was to investigate the relationship between palatal canine impaction (PCI) and STB.

**Materials & Methods:** In this case-control study, in available lateral cephalograms and panoramic radiographs of 53 patients with PCI and 53 controls with normal dentition and no impacted canines the dimensions of STB were measured and graded. Grade I (no calcification): The length of the sella is greater than  $\frac{3}{4}$  of its diameter. Grade II (partial calcification): The length of the sella is equal to or less than  $\frac{3}{4}$  of its diameter. Grade III (complete calcification): A separation bridge is clearly visible on the radiograph. The patients and controls were between 12 and 20 years of age. The relationship between STB and PCI was analyzed using the Chi-square test, Mann-Whitney test, and Fisher's exact test. A value of  $P < 0.05$  was considered significant.

**Results:** There was a significant relationship between STB and PCI ( $P < 0.001$ ). A significant relationship was also found between STB severity grade and PCI ( $P < 0.001$ ). The probability of the presence of Grade II STB in patients with PCI was three times higher than in those with normal dentition. The probability of the presence of Grade III STB in patients with PCI was approximately 46 times higher than in individuals with normal dentition. The length: diameter ratio of the sella turcica was not significantly different between the two groups of patients and controls. No significant relationship was found between gender and STB.

**Conclusion:** The relationship between STB and PCI could be used as diagnostic early indicator to confirm PCI.

**Keywords:** Patients, Diagnosis, Palate, Sella Turcica

Received: 15 May 2022

Revised: 16 Aug 2022

Accepted: 21 Aug 2022

Pub. online: 4 Dec 2022

**Cite this article:** Tavooosi N, Rafiei M, Ehrami E, Jafari Pozveh N. Relationship between palatal canine impaction and sella turcica bridging. Caspian J Dent Res 2023; 12:1-7.



© The Author(s).

Publisher: Babol University of Medical Sciences

\*Corresponding Author: Mehdi Rafiei, Faculty of Dentistry, Isfahan (Khorasgan) Branch, Islamic Azad University, Isfahan, Iran.

Tel: +98 2433473779

E-mail: mehdi.rafiei@khuif.ac.ir

## Introduction

Impacted teeth are those that have not erupted after complete formation of their roots or at the time of complete eruption of their contralateral counterpart. <sup>[1]</sup> After the third molars, maxillary canines are the most commonly impacted teeth, with palatal canine impaction (PCI) occurring in 1-2% of the population. Permanent impaction of the maxillary canines is often suspected in 10-year-old children whose primary canine is not loose. If not properly treated, PCI can lead to problems such as root resorption and mobility of adjacent teeth, development of dentigerous cyst, and discrepancies in arch length. <sup>[2]</sup> PCI may be due to a number of local factors such as lack of space, impaired exfoliation of the primary canine, ankylosis of the primary canine, the presence of cysts or neoplasms at the site, or systemic factors such as genetics. <sup>[3]</sup> The sella turcica is a saddle-shaped bony structure located on the upper surface of the body of the sphenoid bone. Its anterior border is tuberculum sella and its posterior border is dorsum sella. The pituitary gland is located in the sella turcica, and the anterior and posterior clinoid processes are located above the pituitary gland. <sup>[4]</sup> The anterior and posterior clinoid processes are connected by the interclinoid ligament. Sella turcica bridging (STB) refers to calcification and ossification of this ligament. Assessment of patients' lateral cephalograms is the easiest way to detect STB. <sup>[5]</sup>

It has been established that the cells of the neural crest cells are involved in the formation of the anterior wall of the sella turcica as well as in the formation of dental progenitor cells. Therefore, it is assumed that the sella turcica and the teeth have the same fetal origin. <sup>[6]</sup> STB has been shown to be associated with several congenital developmental anomalies in the craniofacial region, such as ectopic tooth eruption, hypodontia, absence of mandibular second premolars, and PCI. <sup>[6, 7]</sup> On the other hand, there is evidence that PCI often occurs in association with other abnormal conditions or genetic disorders such as submerged primary molars, hypoplastic enamel, mandibular molar aplasia, and peg-shaped maxillary lateral incisors. <sup>[6, 7]</sup> Thus, early detection of PCI is important to minimize the cost, complexity, and duration of orthodontic treatment. Orthodontists should have sufficient knowledge of the morphological variations of the sella turcica to distinguish between its normal and abnormal morphology. STB has been shown to occur very early in life, before 6 years of age. If there is a positive family history and evidence of ectopic eruption or other dental anomalies, and lateral cephalograms should be requested to expedite the process of diagnosis and treatment. <sup>[4]</sup> Since there is a correlation between PCI and STB, STB can be used as an indicator for early detection of PCI to help orthodontists in early management. In this way, the complexity and cost of treatment would also decrease.

Dadgar et al. <sup>[8]</sup> in their study on the relationship between PCI with STB and the formation of atlas arcuate foramen (ponticulus posticus) concluded that PCI was 2.5 times more common in people with STB than in the normal population. In a study by El Wak et al. <sup>[9]</sup> STB on CBCT and lateral cephalometric images had no statistically significant relationship with age, gender, facial type, skeletal type, and canine impaction. Ali et al. <sup>[10]</sup> investigated the relationship between STB and PCI and declared that STB was significantly more common in patients with PCI and could be used as a diagnostic parameter to confirm canine impaction. Considering the limited number of studies on this topic, further investigations are required to draw a definitive conclusion regarding the relationship between STB and PCI. Thus, the aim of the present study was to determine the prevalence of STB in patients with and without PCI to evaluate the relationship between PCI and STB.

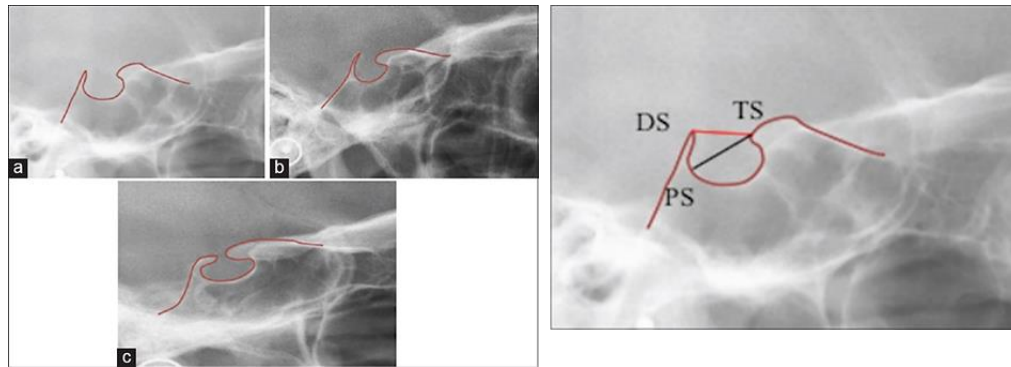
## Materials & Methods

This study was approved by the Ethics Committee of Islamic Azad University, Isfahan (Khorasgan) Branch (IR.IAU.KHUISF.REC.1399.008). In this descriptive case-control study, the available lateral cephalograms and panoramic radiographs of patients retrieved from the archives of the Orthodontic Department of the School, Dentistry, Islamic Azad University, Khorasgan, in 2020 were evaluated. The patients already had orthodontic records and CBCT images in their records. According to the position and eruption path of the canine, the canines of these patients had no chance of eruption, and all had definite canine impaction noted in records. The minimum sample size was 53 according to a previous study by Divya et al. [5] with  $\alpha=0.05$ ,  $\beta=0.2$ , power of 90%, and relative frequency of STB of grade III (complete calcification) in patients with PCI and normal controls of 17.9% and 5.6%, respectively. The inclusion criteria were the presence of at least one palatally impacted maxillary canine on the panoramic radiograph of the patients in the test group (depth, position, direction or severity of impaction were not important) and the presence of lateral cephalograms with optimal contrast and density and optimal visualization of the sella turcica. In addition, the right and left borders of the sella turcica had to match perfectly and could not differ by more than 1 mm. The control group had no impaction or dental anomaly.

Exclusion criteria were canine rotation, missing teeth (except third molars), cleft lip/palate, dental or skeletal syndromes affecting tooth eruption or skull base (such as Down syndrome and ectodermal dysplasia), and dentin or enamel hypoplasia. A total of 53 patients with PCI and 53 control subjects with normal dentition and no impaction or dental anomaly were included. Participants were between 12 and 20 years old, and were randomly selected using the convenience sampling. The type of dental malocclusion was not considered in the selection of patients and controls. The available lateral cephalograms of the patients were evaluated to determine the grade of STB and to measure the length and diameter of the sella turcica. For this purpose, the distance between the tip of the dorsum sella and the tuberculum sella was traced to determine the overall shape and contour of the pituitary fossa. To measure sella length, a straight line was drawn between the dorsum sella and the tuberculum sella, and its length was measured. To determine the maximum anteroposterior diameter of the sella, a straight line was drawn from the tuberculum sella to the most posterior point of the inner wall of the PS and its length was measured (Figure 1). STB grade was determined as follows:

- Grade I (no calcification): The length of the sella is greater than  $\frac{3}{4}$  of its diameter.
- Grade II (partial calcification): The length of the sella is equal to or less than  $\frac{3}{4}$  of its diameter.
- Grade III (complete calcification): A separation bridge is clearly visible on the radiograph.

Data were analyzed using SPSS version 22. The degree of STB was compared between the two groups of patients and controls using the Chi-square test. The Mann-Whitney test was used to analyze the difference in the length: diameter ratio of the sella turcica between the two groups. Fisher's exact test was used to analyze the correlation between gender and STB. The significance level was set at 0.05.



**Figure 1. Measuring the sella turcica dimensions**

## Results

Of 53 patients with PCI, 40 (75.5%) and 13 (24.5%) were female and male, respectively. Of the 53 healthy control subjects, 42 (79.2%) and 11 (20.8%) were female and male, respectively. The Chi-square test revealed no significant difference in gender distribution between the two groups ( $P=0.643$ ). STB was detected in 43 (81.1%) patients with PCI and 24 (45.3%) control subjects with normal teeth. The Chi-square test demonstrated a significant correlation between STB and PCI ( $P<0.001$ ). The number of patients with STB was significantly higher in the PCI group. Table 1 illustrates the frequency distribution of the different grades of STB in the two groups. As shown, the Chi-square test revealed a significant correlation between the severity (grade) of STB and PCI ( $P<0.001$ ), such that patients with PCI had a significantly higher frequency of grade III and a lower frequency of grade I STB.

The odds ratio for patients with grade II STB was 3.40, meaning that a patient with grade II STB was three times more likely to have PCI than a patient with grade I STB. The odds ratio for patients with grade III STB was 46.40, indicating that a patient with grade III STB was 46 times more likely to have PCI than a patient with grade I STB. The mean length: diameter ratio of sella turcica was  $6.21\pm 1.14$  in PCI and  $6.31\pm 1.24$  in the control group. The Mann-Whitney test indicated no significant difference between the patients and controls in the length: diameter ratio of the sella turcica ( $P=0.954$ ). Table 2 displays the mean length: diameter ratio of sella turcica in the two groups ( $n=53$ ), based on the grade of STB. As shown, the Mann-Whitney test revealed that the mean length: diameter ratio of sella turcica was not significantly different in any grade between the two groups. Table 3 represents the correlation of gender with STB in the two groups. The Chi-square test suggested no significant correlation between gender and STB in general ( $P=0.690$ ). Fisher's exact test showed no significant correlation between gender and STB in either group ( $P=1.00$ ).

**Table 1. Frequency distribution of different grades of STB in the two groups**

Grade	PCI		Control		P value*
	Number	Percentage	Number	Percentage	
I	10	18.9	29	54.7	
II	27	50.9	23	43.4	
III	16	30.2	1	1.9	

\*by Chi-square test

**Table 2. Mean length: diameter ratio of sella turcica in the two groups (n=53), based on the STB grade**

STB grade	Group	Number	Mean	Std. Deviation	P value*
	PCI	10	6.30	1.59	
	Control	29	6.23	1.06	
	PCI	27	6.57	1.37	
	Control	23	6.42	1.48	
	PCI	16	5.56	1.32	
	Control	1	6.0	-	

\*by Mann-Whitney test

**Table 3. Correlation between gender and STB in the two groups**

Group	Gender	Absence of STB		Presence of STB		P value*
		Number	Percentage	Number	Percentage	
	Female	23	79.3	19	79.2	
	Male	6	20.7	5	20.8	
	Total	29	100.0	24	100.0	
	Female	8	80.0	32	74.4	
	Male	2	20.0	11	25.6	
	Total	10	100.0	43	100.0	
	Female	31	79.5	51	76.1	
	Male	8	20.5	16	23.9	
	Total	39	100.0	67	100.0	

\* by Fisher's exact test

## Discussion

In this study, the relationship between PCI and STB was investigated. In the present study, the female-to-male ratio was 3 to 1, and the gender distribution was equal in both groups. Thus, the effect of this confounding factor on the results was eliminated. The results showed a significant correlation between the frequency of STB and PCI, such that STB was significantly more frequent in patients with PCI. In addition, patients with PCI were five times more likely to have STB than control subjects with normal dentition. Baidas et al. [7] reported that STB was common in patients with PCI. Ali et al. [10] showed a significantly higher frequency of STB in patients with PCI, and stated that STB can be used as a diagnostic indicator to confirm PCI. Leonardi et al. [11] demonstrated a higher frequency of STB in adolescents with dental anomalies. Scribante et al. [12] indicated a significantly higher frequency of STB in patients with PCI. Haji Ghadimi et al. [13] pointed out the relationship between PCI and STB and its severity. Dadgar et al. [8] reported that PCI was 2.5 times more common in patients with STB. Divya et al. [5] discussed that the detection of STB can help in the early detection of canine impaction. The current results were also in line with those of Baidas et al., [7] Ali et al., [10] Leonardi et al., [11] and Scribante et al., [12].

The reason for this could be the fact that the neural crest cells are involved in the formation of the anterior wall of the sella turcica as well as in the formation of dental progenitor cells. Thus, the sella turcica and the teeth have the same fetal origin. [6] On the other hand, Ortiz et al. [6] found no significant correlation between PCI and STB on cone-beam computed tomography (CBCT) scans. El Wak et al. [9] reported similar results with CBCT. The difference between their results and ours may be due to the different imaging modality since the present study evaluated the patients' lateral cephalograms and panoramic radiographs, whereas they assessed the patients' CBCT scans. Further studies are needed to reach a definitive conclusion in this regard.

The current results showed a significant correlation between the grade of STB and PCI, such that the probability of the presence of grade II STB was three times higher in patients with PCI than in normal individuals. The probability of the presence of grade III STB in patients with PCI was 46 times higher than that in healthy individuals. Thus, it can be concluded that one method of predicting PCI is through the detection of STB. STB occurs early in life, before age 6, and thus, can be used as a predictor of PCI. In patients with a positive family history and evidence of ectopic eruption or other dental anomalies, lateral cephalometry may be requested before the age of 11-12 years (age of canine eruption) to expedite the process of diagnosis and treatment in the case of PCI. [7, 10, 12, 13] The length: diameter ratio of the sella turcica was not significantly different between the two groups of patients and control subjects, and the three STB grades. This parameter has not been investigated in any previous study to compare our results with it. Gender also had no significant correlation with STB in any group in the ongoing study. Leonardi et al. [11] reported that age and gender had no significant effect on calcification of the interclinoid ligament, which is consistent with the present result.

## Conclusion

The current results indicated a significant correlation between STB and PCI since STB occurs earlier than 6 years of age, and the age of canine eruption is 11-12 years, STB can be used as a diagnostic indicator for early confirmation of PCI and implementation of appropriate preventive and therapeutic strategies.

## Funding

This study was a research project (Grant No: 174145), supported and funded by Isfahan (Khorasgan) Branch, Islamic Azad University, Isfahan, Iran.

## Conflicts of Interest

There is no conflict of interest.

## Author's Contribution

The study was designed by Mehdi Rafiei. The study data were collected by Nedasadat Tavoosi and Eilnaz Ehrami. Mehdi Rafiei, Nasim Jafari and Eilnaz Ehrami edited and reviewed the article.

## References

1. Jain S, Debbarma S. Patterns and prevalence of canine anomalies in orthodontic patients. *Med Pharm Rep* 2019;92:72-8.
2. Proffit WR, Fields HW, Larson B, Sarver DM. *Contemporary orthodontics*. 6<sup>th</sup> ed. Philadelphia: Elsevier; 2019. p. 167–268.
3. Cruz RM. Orthodontic traction of impacted canines: Concepts and clinical application. *Dental Press J Orthod* 2019;24:74-87.
4. Sathyanarayana HP, Kailasam V, Chitharanjan AB. Sella turcica-Its importance in orthodontics and craniofacial morphology. *Dent Res J (Isfahan)* 2013; 10:571-5.
5. Divya S, Urala AS, Prasad GL, Pentapati KC. Sella turcica bridging a diagnostic marker for impacted canines and supernumerary teeth. *J Int Oral Health* 2018;10:94-8.
6. Ortiz PM, Tabbaa S, Flores-Mir C, Al-Jewair T. A CBCT Investigation of the Association between sella-turcica bridging and maxillary palatal canine impaction. *Biomed Res Int* 2018; 2018:4329050.
7. Baidas LF, Al-Kawari HM, Al-Obaidan Z, Al-Marhoon A, Al-Shahrani S. Association of sella turcica bridging with palatal canine impaction in skeletal Class I and Class II. *Clin Cosmet Investig Dent* 2018;10:179-87.
8. Dadgar S, Alimohamadi M, Rajabi N, Rakhshan V, Sobouti F. Associations among palatal impaction of canine, sella turcica bridging, and ponticulus posticus (atlas arcuate foramen). *Surg Radiol Anat* 2021;43:93-9.
9. El Wak T, Akl R, Mati M, Khoury E, Ghoubril J. Association between sella turcica bridging and palatal canine impaction: evaluation using lateral cephalograms and CBCT. *Int Orthod* 2018 ;16:338-48.
10. Ali B, Shaikh A, Fida M. Association between sella turcica bridging and palatal canine impaction. *Am J Orthod Dentofacial Orthop* 2014;146:437-41.
11. Leonardi R, Barbato E, Vichi M, Caltabiano M. A sella turcica bridge in subjects with dental anomalies. *Eur J Orthod*. 2006; 28:580-5.
12. Scribante A, Sfondrini MF, Cassani M, Fraticelli D, Beccari S, Gandini P. Sella turcica bridging and dental anomalies: is there an association? *Int J Paediatr Dent* 2017;27:568-73.
13. Haji Ghadimi M, Amini F, Hamed S, Rakhshan V. Associations among sella turcica bridging, atlas arcuate foramen (ponticulus posticus) development, atlas posterior arch deficiency, and the occurrence of palatally displaced canine impaction. *Am J Orthod Dentofacial Orthop* 2017;151:513-20.