

Root canal morphology assessment of the maxillary first premolar using cone-beam computed tomography (CBCT) imaging in a selected Iranian population

Zahra Tafakhori^{1*}, Mehrad Rafiei²

1. Associate Professor, Department of Oral and Maxillofacial Radiology, School of Dentistry, Rafsanjan University of Medical Sciences, Rafsanjan, Iran.
2. Dental Student, Student Research Committee, Rafsanjan University of Medical Sciences, Rafsanjan, Iran.

Article Type

Research Paper

ABSTRACT

Introduction: Considering the effect of ethnicity and race on the root canal morphology of different teeth, this study was conducted to determine the root canal anatomy of permanent maxillary first premolars using cone-beam computed tomography (CBCT) in an Iranian population.

Materials & Methods: This descriptive cross-sectional study was performed on 150 CBCT radiographs of an Iranian population, referred to a Radiology Clinic in Rafsanjan, Iran. The CBCT images were evaluated in terms of the number of roots and canals of maxillary first premolar and also canal types in axial and sagittal images. The Vertucci classification was used for assessing the root morphology. Data were collected using a checklist. The independent t-test and Chi-square test were used and analyzed at a significance level of 0.05.

Results: A study of 150 radiographs showed that 81 and 69 ones had one root and two roots, respectively. In terms of canal type in the single-root teeth, 13 radiographs (16%) were type I, 36 (44.4%) were type II, 6 (7.4%) were type III, 17 (21%) were type IV, two (2.5%) were type V, four (4.9%) were type VI, and three (16%) were type VII. It should be noted that none of the radiographs had a type-VIII canal.

Conclusion: This study has indicated that the Iranian population has a complex maxillary first premolars root canal morphology, and according to Vertucci classification, types II and IV are more common; hence, the Clinician must be very careful before treating the root canal of the first maxillary premolars.

Received: 6 May 2021

Accepted: 18 Sept 2021

Keywords: Cone-Beam Computed Tomography, Anatomy, Maxilla, Premolar

Cite this article: Tafakhori Z, Rafiei M. Root canal morphology assessment of the maxillary first premolar using cone-beam computed tomography (CBCT) imaging in a selected Iranian population. *Caspian J Dent Res* 2021; 10: 30-37.



© The Author(s).

Publisher: Babol University of Medical Sciences

* **Corresponding Author:** Zahra Tafakhori, School of Dentistry, Rafsanjan University of Medical Sciences, Rafsanjan, Iran.

Tel: +989153104726

E-mail: ztakhori@yahoo.com

Introduction

Success in root canal treatment depends on various factors, two of which are more important: the biomechanical preparation of the canal and the acquisition of strong and solid seal through the complete occlusion of the root canal, which in turn depend on having sufficient and thorough knowledge about the root canal anatomy of the treated tooth.^[1, 2] Therefore, to be successful in endodontic treatment, the dentist must be aware of the potential variations in root canal type and must know not just the natural anatomy of the pulp but also any possible variations.^[3]

Numerous studies have been conducted to identify the internal anatomy of teeth in different countries, and racial differences are reflected in this anatomy. Therefore, the ideal treatment of roots requires knowing about the internal anatomy of teeth in each country and ethnicity.^[2, 4-6]

Several methods have been used to examine the root canal anatomy of permanent teeth.^[7] Sectioning^[8, 9], clearing techniques^[10], conventional radiography^[11], advanced and digital imaging techniques^[12] such as micro-computed tomography (MCT)^[10] and cone-beam computed tomography (CBCT)^[13, 14], and the observation of the pulp chamber floor by electron microscope scanning^[15], and clinical methods, including observation during endodontic treatment (with or without magnification), constitute some of these methods.^[16, 17]

CBCT is one of the new methods used to identify additional canals.^[18] Using images obtained from CBCT scans has currently received special attention in dentistry as a diagnostic technique.^[19, 20] Using CBCT is preferable over CT due to the lower radiation dose, shorter scan time, less artifact in the presence of metal restoration, and higher image accuracy.^[21] CBCT was developed to examine the hard tissue of the mouth and to aid in the diagnosis and design of implants; furthermore, this system has proved to be very useful in examining specific endodontic problems.^[22] Identifying the anatomical features and systems of the root canal by 2D imaging used in conventional and digital methods is a difficult task, but CBCT provides a 3D image of the teeth and their surrounding tissues and demonstrates the anatomical relationships of structures, such as the maxillary sinuses, submandibular nerves, root fractures and root canal anatomies, rather clearly.^[23, 24] Most studies use the clearing method to evaluate the root canal morphology and it has been demonstrated that CBCT can be just as reliable as the clearing method.^[2, 14, 25] With its excellent accuracy, this method is also non-invasive and can be used in both laboratory and clinical studies.^[26, 27]

CBCT is a type of computerized cross-section. Unlike conventional systems, this system uses cone-shaped beams rather than fan-shaped beams. Since this system uses array detectors, the resulting images provide a volume of data about the patient instead of providing sectioned images.^[28, 29]

The maxillary first premolars usually have two roots and two root canals with different anatomies^[30] and can have one, two or three roots.^[31] The successful root treatment of these teeth requires sufficient knowledge about their root canal anatomy.^[30, 32] Numerous studies around the world have investigated the number and morphology of maxillary first premolars in different races^[30, 32-36] to gain more thorough knowledge about their root canal anatomy.

Various studies have been reported to study the morphology of the root canal of the first maxillary premolars by CBCT images in different parts of Iran^[37-39], and the number of single root teeth has been reported from at least 51% to more than 95%. Also, evaluations based on Vertucci classification represented that types I, II and IV were the most common. Therefore, there is a need for further studies in a different Iranian population to determine the morphology of the maxillary first premolars.

This study was therefore conducted to determine the root canal anatomy of permanent maxillary first premolars using CBCT in an Iranian population to determine their morphology and to thereby reduce endodontic treatment errors in Iranian populations.

Materials & Methods

This descriptive cross-sectional study was conducted on 150 CBCT radiographs of patients who had presented to a private oral and maxillofacial radiology clinic in Rafsanjan, Iran, to receive treatments. A code of ethics (IR.RUMS.REC.1399.167) to conduct the study was obtained from Rafsanjan University of Medical Sciences.

The inclusion criteria were radiographs of people in Rafsanjan whose first premolars did not have large restorations or any root canal treatments, and the adjacent teeth of which did not have large fillings or implants (due to created artifacts). The exclusion criteria were the presence of a periapical lesion, root resorption, open apex, canal calcification, and crowns.

Based on the study of Alqedairi et al.^[40] in Saudi Arabia in 2018, and using the following equation, the required sample size was determined:

$$n = \frac{Z_{1-\frac{\alpha}{2}}^2 \times P \times (1-P)}{d^2} \quad \alpha = 0.05 \rightarrow Z_{1-\frac{\alpha}{2}} = 1.96$$

$P = 75.1\%$
 $d = 7\%$

Thus, 147 CBCT radiographs of patients over 15 years of age were required for this study.

CBCT images taken by Planmeca ProMax 3D Classic (Helsinki, Finland) with Fov 8*8, voxel size 150 μm , and exposure conditions as 6 mA, 64 Kvp voltage, and 12 seconds time were used for the 3D evaluation of the anatomy and morphology of the teeth.

After preparing the radiographs using Romexis 3.8.3.or software, the CBCT images were evaluated in terms of the number of roots and canals of the maxillary first premolars and types of canals in multiplanar reconstruction (MPR) sagittal (Figure-1) and axial images (Figure-2) in both males and females. The CBCT images were examined by an experienced radiologist and the information was recorded in a checklist. An endodontist was also consulted in suspicious cases.

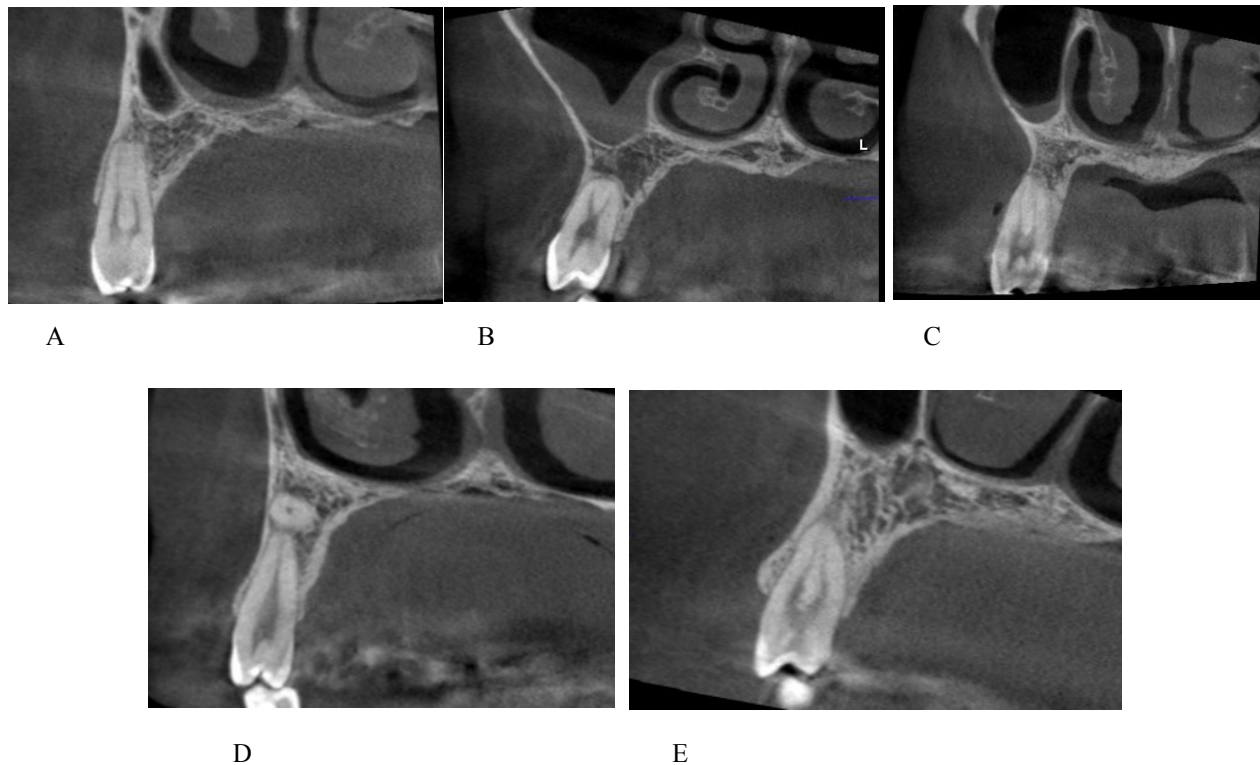


Figure 1. Images of the teeth roots in the sagittal plane (MPR)
A: Type IV, B: Type VI, C: Type IV, D: Type I, E: Type II

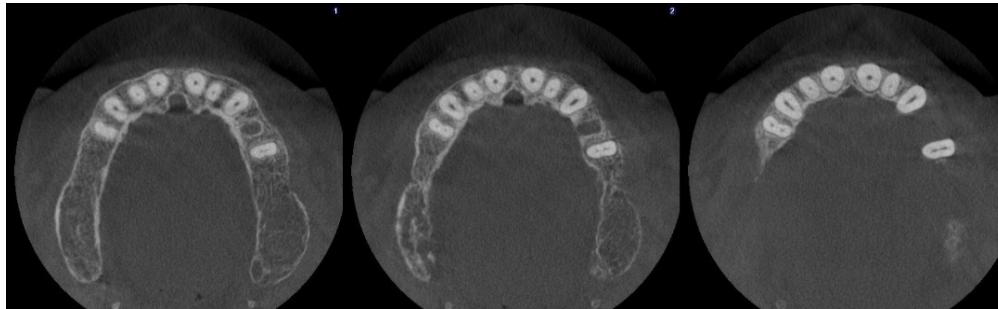

Figure 2. The axial plane to check the number and shape of the canals

To study the morphology of the roots, after obtaining the MPR images (sagittal and coronal axes were set along the longitudinal axis of the root to allow for the tooth apex to be well visible), the assessment was carried out based on Vertucci classification.^[41] The information in the checklist was entered into SPSS-21 software one by one. The quantitative data were reported as “Mean \pm SD” and qualitative data as “number (percent)”. The non-parametric Kolmogorov-Smirnov test was used to assess the normality of the frequency distribution of the quantitative variables. The independent two-sample t-test and Chi-square test or Fisher’s exact test were used to evaluate the canal anatomy of permanent maxillary first premolars by gender, number of roots, and number and type of canals. The significance level was $P < 0.05$ for all the tests.

Results

This study was conducted on 150 CBCT radiographs of patients who had presented to a private oral and maxillofacial radiology clinic in Rafsanjan, Iran. Of the 150 radiographs examined, 79 (52.7%) belonged to male and 71 (47.3%) to female patients. Also, 66 (44%) were prepared from the right side and 84 (56%) from the left side of the patients. Of these 150 radiographs, 81 (54%) had a single root and 69 (46%) had two roots.

The Chi-square test displayed that the frequency distribution of the number of roots differed significantly between the men and women ($P = 0.012$). That is, the frequency of single-root teeth was 63.4% in women and 45.6% in men. The Chi-Square test further demonstrated that the frequency distribution of the number of canals between the men and women was not significantly different ($P = 0.38$). The frequency of samples with one and two canals was 33.3% and 66.7% in women and 27.8% and 72.2% in men, respectively.

A total of 81 radiographs of teeth with one root were examined in terms of their root canal anatomy and based on Vertucci classification, 13 (16%) were type I, 36 (44.4%) type II, 6 (7.4%) type III, 17 (21%) type IV, two (2.5%) type V, four (4.9%) type VI, and three (3.7%) were type VII. It should be noted that none of the radiographs had a type-VIII canal (Table 1). Fisher’s exact test illustrated that the frequency distribution of the canal types did not differ significantly between men and women ($P = 0.053$).

Table 1. The frequency distribution of canal types by gender in the studied radiographs in Rafsanjan in 2018-2019

Type	Type I Number (percent)	Type II Number (percent)	Type III Number (percentage)	Type IV Number (percent)	Type V Number (percentage)	Type VI Number (percent)	Type VII Number (percentage)	Fisher’s exact test result
Male	6 (16.7)	15 (41.7)	2 (5.6)	8 (22.2)	1 (2.8)	4 (11.1)	0 (0)	P=0.053
Female	7 (15.6)	21 (46.7)	4 (8.9)	9 (20.0)	1 (2.2)	0 (0)	3 (6.7)	
Total	13 (16.0)	36 (44.4)	6 (7.4)	17 (21.0)	2 (2.5)	4 (4.9)	3 (3.7)	

Discussion

In the present study, of the 150 radiographs examined, 81 (54%) had a single root and 69 (46%) had two roots. In one study, Burklein reported that 62.4% of their samples had two roots, 36.4% had one root, and 1.2% had three roots.^[34] In a study by Maghfuri et al. in Saudi Arabia, 36% of the samples had one root, 61% had two roots and 3% had three roots.^[31] Li et al. reported the number of people with maxillary first premolars that had one, two and three roots in the Chinese ethnicity to be 69.7%, 29.8%, and 0.5%.^[42]

Studies on the Iranian population have shown that the prevalence of single-rooted maxillary first premolars is 57.8% , 50% and 98%, respectively.^[37,38,39] The discrepancy in the results of these studies and the present study can be attributed to racial and ethnic differences. Ethnicity influences the morphological differences of teeth.^[43, 44] Sert et al. concluded that both gender and race should be considered in pre-treatment evaluations of the root canal.^[45]

This study only examined teeth with one root for its root canal morphology assessment and proceeded based on Vertucci classification^[41], which is common and has been used in several studies.^[2] The most common canals were type II (36 radiographs; 44.4%) and type IV (17 radiographs; 21%). It should be noted that none of the radiographs had a type-VIII canal. Various similar studies have shown that type IV is very common.^[33, 35,39,46,47] Burklein et al. reported the most common types as IV (68.5%) and VI (12.3%), and no type III.^[33] In a study by OK et al., the most common types were I and II while type VII was observed.^[47] Moreover, Li et al. demonstrated that type IV was the most common maxillary first premolar canal.^[42] Other studies have also reported type IV to be the most common canal type in maxillary first premolars, followed by types I, III, and V.^[32,39,47]

In a similar study by Tofangchiha et al. on the Iranian ethnicity, type II was found to be one of the most common types of the canal.^[37] Asheghi et al. declared that type IV was the most common type among Iranians.^[38] Besides, Sobhani et al. reported that type I was the most common type in the Iranian population,^[39] which can indicate the prevalence of types I, II and IV in the Iranian ethnicity, which is consistent with the present findings. Nonetheless, those studies reported types II and IV as the most common types, but with different percentages, which can be attributed to differences in the study methods (laboratory or clinical) and the techniques used to identify the canal, or the fact that the other studies had also examined double-root teeth or perhaps differences in the race and ethnicity of the study populations and sample sizes.^[13]

The present findings manifested that 45.6% of the single-root teeth belonged to men and 53.4% to women, while 54.4% of the double-root teeth belonged to men and 36.6% to women. The present study cleared that both types II and IV were more common in both men and women. Similar to this finding, Abella et al. also reported that the maxillary first premolars of most women had one root^[35], and Burklein et al. showed that single-root teeth were more common in women and double-root teeth more common in men.^[33] These differences were not significant in any of the studies. There is still a controversy on the relationship between gender and tooth morphology; however, further studies with larger sample sizes are recommended to be conducted on the effect of gender on the morphology of maxillary first premolars.^[48]

There were some limitations to our study, only one dental CBCT system was studied, There are other dental CBCT systems too, On the other hand, the accuracy of CBCT has only been used to detect the root canal configurations of maxillary first premolars, also in the current study only one clinician Evaluate the CBCT images that increase the likelihood of an error.

Conclusion

This study indicated the Iranian population has a complex maxillary premolars root canal morphology, Most of these teeth are single root and also the number of roots is affected by sex. According to vertucci classification, types II and IV are more common, so the clinician must be very careful before the maxillary first premolar root canal treatment.

Funding

This study was a research project (Grant No. 97485), supported and funded by Rafsanjan University of Medical Sciences.

Conflicts of Interest

The authors have no conflicts of interest to disclose.

Authors' Contribution

The study was designed and data were collected by Zahra Tafakhori . Mehrad Rafiei wrote and edited the article. All authors have contributed equally.

References

1. Boutsoukis C. Internal Tooth Anatomy and Root Canal Irrigation. In: Versiani MA, Basrani B, Sousa-Neto MD, editors. *The Root Canal Anatomy in Permanent Dentition*. Cham: Springer International Publishing; 2019. p. 303-21.
2. Hosseinpour S, Kharazifard MJ, Khayat A, Naseri M. Root Canal Morphology of Permanent Mandibular Premolars in Iranian Population: A Systematic Review. *Iran Endod J* 2016;11:150-6.
3. Torabinejad M, Fouad AF, Shabahang S. *Endodontics E-Book: Principles and practice*[Online].6th ed. Philadelphia, PA: Elsevier Inc; 2020[cited 2021Mar18]. Available at: <https://www.google.com/search?tbm=bks&q=Endodontics+E-Book%3A+Principles+and+practice>
4. Dou L, Li D, Xu T, Tang Y, Yang D. Root anatomy and canal morphology of mandibular first premolars in a Chinese population. *Sci Rep* 2017;7:750.
5. Estrela C, Bueno MR, Couto GS, Rabelo LE, Alencar AH, Silva RG, et al. Study of Root Canal Anatomy in Human Permanent Teeth in A Subpopulation of Brazil's Center Region Using Cone-Beam Computed Tomography - Part 1 . *Braz Dent J* 2015;26:530-6.
6. Pan JYY, Parolia A, Chuah SR, Bhatia S, Mutalik S, Pau A. Root canal morphology of permanent teeth in a Malaysian subpopulation using cone-beam computed tomography. *BMC Oral Health*2019;19:14.
7. Datta P, Zahir S, Kundu G K, Dutta K. Different Methods of Studying Root Canal Morphology of Human Tooth: A Review. *Bangladesh J Dent Res Educ* 2015;5:59.
8. Rezaeian M, Rouhani Tonekaboni M, Iranmanesh F. Evaluating the Root Canal Morphology of Permanent Maxillary First Molars in Iranian Population. *Iran Endod J* 2018;13:78-82.
9. Khedmat S, Assadian H, Saravani AA. Root Canal Morphology of the Mandibular First Premolars in an Iranian Population Using Cross-sections and Radiography. *J Endod* 2010;36:214-7.
10. Kim Y, Perinpanayagam H, Lee JK, Yoo YJ, Oh S, Gu Y, et al. Comparison of mandibular first molar mesial root canal morphology using micro-computed tomography and clearing technique. *Acta Odontol Scand* 2015;73:427-32.
11. Omer OE, Al Shalabi RM, Jennings M, Glennon J, Claffey NM. A comparison between clearing and radiographic techniques in the study of the root-canal anatomy of maxillary first and second molars. *Int Endod J* 2004;37:291-6.
12. Moshfeghi M, Sajadi SS, Sajadi S, Shahbazian M. Conventional versus digital radiography in detecting root canal type in maxillary premolars: an in vitro study. *J Dent (Tehran)* 2013;10:74-81
13. Rouhani A, Bagherpour A, Akbari M, Azizi M, Nejat A, Naghavi N. Cone-beam computed tomography evaluation of maxillary first and second molars in Iranian population: a morphological study. *Iran Endod J* 2014;9:190-4.

14. Neelakantan P, Subbarao C, Subbarao CV. Comparative evaluation of modified canal staining and clearing technique, cone-beam computed tomography, peripheral quantitative computed tomography, spiral computed tomography, and plain and contrast medium-enhanced digital radiography in studying root canal morphology. *J Endod* 2010;36:1547-51.
15. Bernardes RA, Duarte MAH, Vivian RR, Alcalde MP, Vasconcelos BC, Bramante CM. Comparison of three retreatment techniques with ultrasonic activation in flattened canals using micro-computed tomography and scanning electron microscopy. *Int Endod J* 2016;49:890-7.
16. Wolcott J, Ishley D, Kennedy W, Johnson S, Minnich S. Clinical Investigation of Second Mesiobuccal Canals in Endodontically Treated and Retreated Maxillary Molars. *J Endod* 2002;28:477-9.
17. Das S, Warhadpande MM, Redij SA, Jibhkate NG, Sabir H. Frequency of second mesiobuccal canal in permanent maxillary first molars using the operating microscope and selective dentin removal: A clinical study. *Contemp Clin Dent* 2015;6:74-8.
18. Martins JNR, Versiani MA. CBCT and Micro-CT on the Study of Root Canal Anatomy. In: Versiani MA, Basrani B, Sousa-Neto MD, editors. *The Root Canal Anatomy in Permanent Dentition*. Cham: Springer International Publishing; 2019. p. 89-180.
19. The use of cone-beam computed tomography in dentistry: an advisory statement from the American Dental Association Council on Scientific Affairs. *J Am Dent Assoc* 2012;143:899-902.
20. Alamri HM, Sadrameli M, Alshalhoob MA, Sadrameli M, Alshehri MA. Applications of CBCT in dental practice: a review of the literature. *Gen Dent* 2012;60:390-400.
21. Alshehri MA, Alamri HM, Alshalhoob MA. CBCT applications in dental practice: A literature review. *Gen Dent* 2010;36:26-31
22. Patel S, Kanagasingam S, Mannocci F. Cone Beam Computed Tomography (CBCT) in Endodontics. *Dent update* 2010;37:373-9.
23. Kiarudi AH, Eghbal MJ, Safi Y, Aghdasi MM, Fazlyab M. The applications of cone-beam computed tomography in endodontics: a review of literature. *Iran Endod J* 2015;10:16-25.
24. Scarfe WC, Levin MD, Gane D, Farman AG. Use of Cone Beam Computer Tomography in Endodontics. *Int J Dent* 2009; 2009: 634567.
25. Reuben J, Velmurugan N, Kandaswamy D. The Evaluation of Root Canal Morphology of the Mandibular First Molar in an Indian Population Using Spiral Computed Tomography Scan: An In Vitro Study. *J Endod* 2008;34:212-5.
26. Khademi A, Zamani Naser A, Bahreinian Z, Mehdizadeh M, Najarian M, Khazaei S. Root Morphology and Canal Configuration of First and Second Maxillary Molars in a Selected Iranian Population: A Cone-Beam Computed Tomography Evaluation. *Iran Endod J* 2017;12:288-92.
27. Peeters HH, Suardita K, Setijanto D. Prevalence of a second canal in the mesiobuccal root of permanent maxillary first molars from an Indonesian population. *J Oral Sci* 2011;53:489-94.
28. Cotton TP, Geisler TM, Holden DT, Schwartz SA, Schindler WG. Endodontic Applications of Cone-Beam Volumetric Tomography. *J Endod* 2007;33:1121-32.
29. Durack C, Patel S. Cone beam computed tomography in Endodontics. *Braz Dent J* 2012;23:179-91.
30. Ahmad IA, Alenezi MA. Root and Root Canal Morphology of Maxillary First Premolars: A Literature Review and Clinical Considerations. *J Endod* 2016;42:861-72.
31. Maghfuri S, Keyhani H, Chohan H, Dakkam S, Atiah A, Mashyakhly M. Evaluation of Root Canal Morphology of Maxillary First Premolars by Cone Beam Computed Tomography in Saudi Arabian Southern Region Subpopulation: An In Vitro Study. *Int J Dent* 2019;2019:2063943.
32. Ahmed HMA, Cheung GSP. Accessory roots and root canals in maxillary premolar teeth: a review of a critical endodontic challenge. *Endod Prac Today* 2012;6:7-18.
33. Bürklein S, Heck R, Schäfer E. Evaluation of the Root Canal Anatomy of Maxillary and Mandibular Premolars in a Selected German Population Using Cone-beam Computed Tomographic Data. *J Endod* 2017;43:1448-52.
34. Saber SEDM, Ahmed MHM, Obeid M, Ahmed HMA. Root and canal morphology of maxillary premolar teeth in

- an Egyptian subpopulation using two classification systems: a cone beam computed tomography study. *Int Endod J* 2019;52:267-78.
35. Abella F, Teixidó LM, Patel S, Sosa F, Duran-Sindreu F, Roig M. Cone-beam Computed Tomography Analysis of the Root Canal Morphology of Maxillary First and Second Premolars in a Spanish Population. *J Endod* 2015;41:1241-7.
36. Dashrath K, Nisha A, Subodh S. Root Morphology and Tooth Length of Maxillary First Premolar in Nepalese Population. *Dentistry* 2015; 5: 324.
37. Tofangchiha M, Bolbolian M, Ghasemi A. Evaluation of root canal morphology of maxillary first premolars using cone beam computed tomography. *J Mash Dent Sch* 2018;42:31-40.[In Persian]
38. Asheghi B, Momtahan N, Sahebi S, Zangoie Booshehri M. Morphological Evaluation of Maxillary Premolar Canals in Iranian Population: A Cone-Beam Computed Tomography Study. *J Dent (Shiraz)* 2020;21:215-24.
39. Sobhani Mohhsen A, Razmi H, Sadegh M. Evaluation of anatomy and morphology of human mandibular premolar teeth by cone-beam computed tomography in Iranian population. *J Dent (Tehran)* 2013;26(3):203-10.[In Persian]
40. Alqedairi A, Alfawaz H, Al-Dahman Y, Alnassar F, Al-Jebaly A, Alsubait S. *Biomed Res Int* 2018;2018:8170620.
41. Vertucci FJ. Root canal anatomy of the human permanent teeth. *Oral Surg Oral Med Oral Pathol* 1984;58:589-99.
42. Li YH, Bao SJ, Yang XW, Tian XM, Wei B, Zheng YL. Symmetry of root anatomy and root canal morphology in maxillary premolars analyzed using cone-beam computed tomography. *Arch Oral Biol* 2018;94:84-92.
43. Somma F, Leoni D, Plotino G, Grande NM, Plasschaert A. Root canal morphology of the mesiobuccal root of maxillary first molars: a micro-computed tomographic analysis. *Int Endod J* 2009;42:165-74.
44. Verma GR, Bhadage C, Bhoosreddy AR, Vedpathak PR, Mehrotra GP, Nerkar AC, et al. Cone Beam Computed Tomography Study of Root Canal Morphology of Permanent Mandibular Incisors in Indian Subpopulation. *Pol J Radiol* 2017;82:371-5.
45. Sert S, Bayirli GS. Evaluation of the Root Canal Configurations of the Mandibular and Maxillary Permanent Teeth by Gender in the Turkish Population. *J Endod* 2004;30:391-8.
46. Sulaiman AO, Dosumu, OO, Amedari M. Maxillary first premolar with three roots. A case report. *Ann Ib Postgrad Med.* 2013; 11: 105–8.
47. Ok E, Altunsoy M, Nur BG, Aglarci OS, Çolak M, Güngör E. A cone-beam computed tomography study of root canal morphology of maxillary and mandibular premolars in a Turkish population. *Acta Odontol Scand* 2014;72:701-6.
- 1.48. Corbella S, Del Fabbro M, Tsesis I, Taschieri S. Computerized Tomography Technique for the Investigation of the Maxillary First Molar Mesiobuccal Root. *Int J Dent* 2013;2013:614898.