

Evaluation of neurovascular anatomical variations in maxillary anterior region in cone beam computed tomography images

Farida Abesi¹, Fatemeh Saeedi^{2✉}, Sina Haghanifar¹, Ehsan Moudi¹, Soraya Khafri³

1. Associate Professor, Dental Materials Research Center, Department of Oral & Maxillofacial Radiology, Faculty of Dentistry, Babol University of Medical Sciences, Babol, IR Iran.
2. Dental Student, Student Research Committee, Babol University of Medical Sciences, Babol, IR Iran.
3. Assistant Professor, Department of Biostatistics and Epidemiology, Faculty of Medicine, Babol University of Medical Sciences, Babol, IR Iran.

✉Corresponding Author: Fatemeh Saeedi, Faculty of Dentistry, Babol University of Medical Sciences, Babol, IR Iran.

Email: drfsaeedi@gmail.com

Tel: +989359412073

Received: 1 Jun 2017

Accepted: 25 Sept 2017

Abstract

Introduction: Incisive foramen in the maxilla is the oral terminus of the nasopalatine canal. This region is important in implantology, Therefore, the aim of this study was to investigate the neurovascular anatomical variations in the maxillary anterior region, observed on cone beam computed tomography (CBCT) images.

Materials & Methods: In this cross-sectional study, maxillary CBCT images from 200 patients (100 men, 100 women, average age 45.61 ± 11.01) were evaluated in sagittal, axial and coronal sections and the following parameters were investigated: incisive canal diameter, shapes of canal, presence of accessory canal in the anterior palate and their location, thickness of buccal bone in the sections containing canal, patient's dental and periodontal status in terms of bone loss. Data were collected and analyzed using SPSS, V20. $P \leq 0.05$ was considered significant.

Results: In sagittal view, the mean diameter of the canal was 2.36 ± 0.69 mm. Age and gender did not significantly influence the diameter. Morphological analysis of canal showed that 25% of them were hourglass-like, 23.5% conical, 22% funnel, 27.5% cylindrical, 2% tree branch. Accessory canals were observed in 58 patients (29%) specially near to the canine region. The thickness of buccal bone plate was less in complete edentulous patients than others and also there was a significant relationship between bone loss and canal size in the hourglass and cylindrical shapes.

Conclusion: In this study, the prevalence of accessory canals was relatively significant, so it seems essential to carry out cone beam computed tomography in this area for determining the canal morphology and dimensions before implant placement.

Keywords: Cone-beam computed tomography, Dental implant, Maxilla

Citation for article: Abesi F, Saeedi F, Haghanifar S, Moudi E, Khafri S. Evaluation of neurovascular anatomical variations in maxillary anterior region in cone beam computed tomography images. Caspian J Dent Res 2017; 6: 23-9.

بررسی تنوعات آناتومیک عروقی عصبی در ناحیه قدام فک بالا در تصاویر CBCT

فریدا عابسی، فاطمه سعیدی*، سینا حقانی فر، احسان موعودی، ثریا خفری

چکیده

مقدمه: فورامن اینسیزیو در ماگزایلا در انتهای دهانی کانال نازوپالاتین قرار دارد. این ناحیه در ایمپلنتولوژی اهمیت بسیار زیادی دارد به همین دلیل این پژوهش به بررسی تنوعات آناتومیک عروقی عصبی در ناحیه قدام فک بالا در تصاویر CBCT پرداخته است.

مواد و روش ها: در این مطالعه مقطعی، تصاویر CBCT ۲۰۰ بیمار (۱۰۰ مرد، ۱۰۰ زن، میانگین سنی $45/61 \pm 11/01$) در مقاطع مختلف ساژیتال، اگزیتال، کرونال ارزیابی شد. مواردی مانند قطر کانال اینسیزیو، اشکال مختلف کانال، وجود کانال های فرعی در قدام کام و محل آنها، میزان استخوان باکال در مقاطع حاوی کانال، وضعیت دندانی و پرپودنتالی بیمار از نظر میزان Bone loss مورد بررسی قرار گرفت. داده ها وارد نرم افزار SPSS, V20 شدند و $P \leq 0.05$ معنادار در نظر گرفته شد.

یافته ها: در مقطع ساجیتال میانگین قطر کانال برابر $2/36 \pm 0/69$ بود و سن و جنس روی سایز کانال اثر نداشت. بررسی مورفولوژی کانال در مقطع ساجیتال نشان داد که ۲۵٪ به شکل ساعت شنی، ۲۳٪ مخروطی، ۲۲٪ قیفی، ۲۷٪ استوانه ای و ۲٪ شاخه درخت می باشد. ۵۸ بیمار دارای کانال فرعی بودند (۲۹٪) که این کانال های فرعی بیشتر نزدیک ناحیه ی کانین دیده شدند. ضخامت پلیت باکال در افراد بی دندان کامل، کمتر از سایر افراد بود و هم چنین بین متغیر وضعیت پرپودنتال (Bone loss) و سایز کانال در شکل ساعت شنی و استوانه ای ارتباط معنی داری یافت شد.

نتیجه گیری: در مطالعه حاضر شیوع کانال های فرعی در قدام کام نسبتا قابل توجه بود، بنابراین بررسی CBCT این ناحیه برای تعیین مورفولوژی و ابعاد کانال قبل از جایگذاری ایمپلنت ضروری به نظر می رسد.

واژگان کلیدی: توموگرافی کامپیوتری با اشعه مخروطی، ایمپلنت دندان، فک بالا

Introduction

Nasopalatine canal which starts from two foramina in the nasal cavity exists in the maxillary anterior region. Their opening site on both sides of the nasal septum is close to the anteroinferior border of the nasal cavity and each branch goes down and slightly to the anterior and medial to joint the canal in the opposite side in a common place called incisive foramen (nasopalatine). This foramen is placed in the midline palate, behind the central incisors. [1] Incisive foramen is generally seen as large or small symmetrical oval, round or heart-shaped radiolucency. This canal contains nasopalatine nerves and blood vessels. It rarely has a cortical border probably indicating the presence of nasopalatine cyst (incisive cyst). Nasopalatine nerve is a branch of the sphenopalatine ganglion that innervates to the nasal roof and septum. [2] Sometimes, a large radiolucency is seen in images, which makes it difficult to detect whether this is a large incisive foramen or a nasopalatine duct cyst. Radiolucency larger than 6mm can be considered as a cyst, which requires detailed and accurate examinations. [1] Bodin et al. proposed that the

probability of cysts must be considered in lesions larger than 8 mm with bulging and thin cortical border, especially with symmetrical bulging one, and radiolucency larger than 14 mm is always considered as cysts. [3] Thus, all these studies emphasize the importance of measuring the nasopalatine canal diameter. Delay et al. [4] and Swanson et al. [5] evaluated the pathology of nasopalatine canal so that Mraiwa et al. and Mamachan found 73% of 295 cases involving nonodontogenic tumors were nasopalatine duct cysts. Thickness of buccal bone plate and location of nasopalatine canal are major in implantology because of the importance of aesthetics, phonetics and function of the implants in the maxillary anterior region [6, 7], in such way that the lack of accurate determination of the location and thickness of the buccal bone plate can cause the wrong placement of the implant in the canal. [8-10] This can damage the nasopalatine canal and cause some complications such as neurovascular lesions and non-osseointegrated implants. [11] Bornstein et al. evaluated the dimensions and characteristics of

nasopalatine canal and thickness of the buccal bone plate via CBCT images and they concluded that the thickness of buccal bone plate was less in people who lost both central teeth over a year than other people.^[12] Etoz et al. and Liang et al. also analyzed nasopalatine canal and showed that it has different anatomical variations whose investigation using CBCT images is necessary before implant placement.^[13, 14]

Due to the anatomical variations of the canal and differential diagnosis of incisive foramen from pathologic lesions, there is a need to further investigation in the anterior palatal region. Therefore, this study investigated the neurovascular anatomical variations in maxillary anterior region, observed on CBCT images.

Materials & Methods

In this cross-sectional study, 200 CBCT scans of patients referred to an oral and maxillofacial radiology center in Babol during 2014-2016 were selected and evaluated.

Inclusion criteria in this study were: 1-Patients over 18, 2-patients with anterior maxilla CBCT, 3-patients without a history of maxillary surgery. Poor quality CBCT images and those with technical problems were excluded. All CBCT images were obtained using Giano (Newtom, Verona, Italy) with a standardized exposure protocol at 2-10 mA and 60-90 kVp and images were displayed at different sagittal, axial and coronal views in a completely dark space on 19-inch screen (Samsung sync master sn, South Korean). Also, two oral and maxillofacial radiologists simultaneously reviewed the CBCT images and shared their opinion, and in the case of disagreement, the third observer expressed his/her opinion. CBCT images were investigated based on the information prepared in check list containing two parts: 1-demographic information such as age and sex, 2- data collected from CBCT images. The following parameters were studied in the present study: minimum and maximum diameter of the nasopalatine canal in the cross sectional view, shapes of the canal (hourglass, funnel, conical, cylindrical, tree branch), which was based on Etoz et al.'s classification (Fig.1)^[13], the presence of accessory canals in the anterior palate and their location, the thickness of buccal bone plate in sections containing canal, patient's dental status (full dentate patients with 6 anterior teeth), partial edentulous patients (without any of the 6 anterior teeth), complete

edentulous patients (missing 6 anterior teeth) and the periodontal status of patients in terms of bone loss (mild: loss of 1-2 mm of normal supporting bone height (or 20%), moderate: loss of 2 mm up to half of normal supporting bone height (or between 20% and 50%), severe: loss of beyond this point).^[1] The items such as canal size, different shapes of canal, thickness of buccal bone plate were investigated on sagittal view, dental status in panoramic view and accessory canal based on three axial, sagittal and coronal sections. To assess the periodontal status of patients, interdental bone level was measured up to the cemento-enamel junction (CEJ) in the Panorex view. For measuring the canal, three measurements in the cylindrical shape (upper (max), middle (mid) and lower (min) part of the canal) and two measurements for other shapes (maximum and minimum diameter of the canal) were done (Fig.2). Data were analyzed using Chi-square test and Fisher's exact test in SPSS20 in different age and gender groups and $p \leq 0.05$ was considered significant.

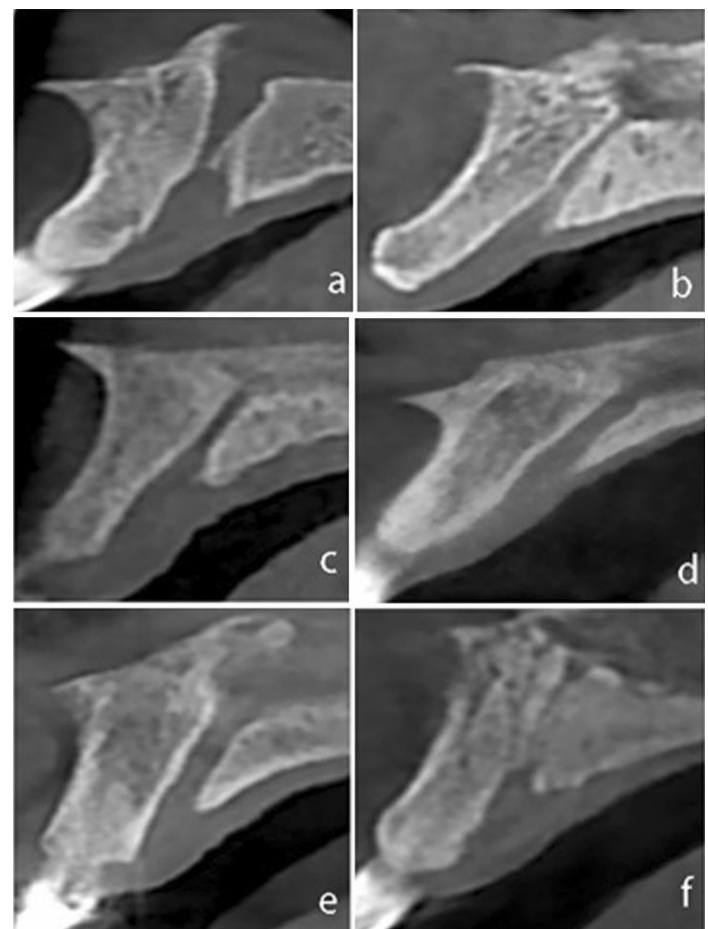


Figure1. Classification of nasopalatine canal shape in the sagittal section of CBCT images a. Hourglass, b. Conical, c. Funnel, d. Cylindrical, e. Tree branch

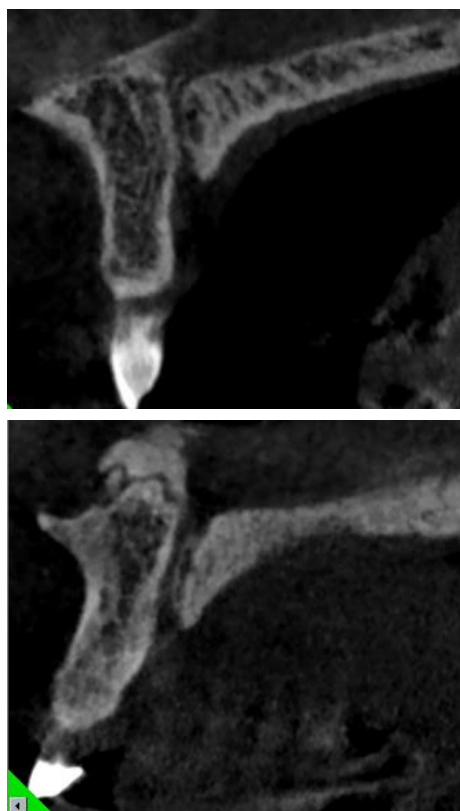


Figure 2. Method of measuring different shapes of canal a: Cylindrical shape (1: max 2: mid 3: min) b: Funnel shape (1: min 2: max)

Results

In this study, CBCT images of 200 patients (100 men and 100 women) were studied. The average age of patients was 45.61 ± 11.01 with minimum and maximum ranges of 25 and 65 years, respectively. Hourglass, conical, funnel, cylindrical and tree branch shapes were observed in 50 (25%), 47 (23.5%), 44 (22%), 55 (27.5%) and 4 cases (2%), respectively. Thus, the cylindrical shape had the highest prevalence. Out of 200 patients, 58 patients (29%) had accessory canal and totally, 61 canals were found, so three patients had two accessory canals. Accessory canals in maxillary right canine, lateral and central were respectively 7(11.47%), 14(22.95%), 15(24.59%) Also Accessory canals in maxillary left canine, lateral and central were 3(4.92%), 9(14.75%), 13(21.31%).

In the present study, 114 (57%), 71 (35.5%) and 15 (7.5%) of participants were full dentate, partial and complete edentulous patients, respectively. The mean diameter of the buccal bone plate was 6.14 ± 1.26 mm with a minimum and maximum of 3 and 9.1mm, respectively. Buccal bone plate diameter in full dentate, partial and complete edentulous patients was 6.4 ± 1.16 , 6.26 ± 1.33 and 5.1 ± 1.03 , respectively. Moreover, there was statistically a significant relationship between two above variables ($p = 0.001$). The mean diameter of the nasopalatine canal was 2.36 ± 0.69 with a minimum and maximum of 0.8 and 4.1, respectively and in the majority of cases, the results showed that the canal size was significantly increased in all shapes with a reduction in the buccal bone plate thickness (all of $p < 0.05$). Data related to the canal size have been reported for each shape in table 1.

Table 1. Canal diameter for each shape

canal shape	canal diameter	Mean and standard deviation	(Minimum, maximum)
Hourglass	*Min	1.52 ± 0.5	1,3
	**Max	3.47 ± 0.84	2,6
Conical	Min	1.12 ± 0.56	1,4
	Max	3.26 ± 0.83	1,5
Funnel	Min	1.12 ± 0.49	1,3
	Max	3.13 ± 0.74	2,5
Cylindrical	Min	2.67 ± 0.99	1,5
	Max	2.66 ± 0.92	1,4
	***Mid	2.53 ± 0.96	1,4
Tree branch	Min	0.73	
	Max	2.75	

*Min: Minimum diameter of the canal (but in cylindrical shape indicating the diameter of lower part of canal)

**Max: Maximum diameter of the canal (but in cylindrical shape indicating the diameter of upper part of canal)

***Mid: The diameter of middle part of cylindrical canal

In addition, periodontal status (bone loss) between teeth was measured and the results are represented in table 2. The results based on Pearson correlation between bone loss and the canal size indicated that, in the majority of cases, there was a correlation between two above variables in the maximum diameter of hourglass shape between central and lateral teeth, in the left and right sides and in all parts of cylindrical shape, between left and right lateral incisors, indicating the canal size was enhanced with the increase of bone loss. (Table 3)

Table 2. Periodontal status

Tooth number	3, 2 ^a	2,1 ^b	1,1 ^c	1,2 ^d	2,3 ^e
Periodontal status	n=139	n=150	n=146	n=135	n=138
Without bone loss	(66.9%)93	(60%)90	(54.8%)80	(48.1%)65	(65.2%)90
Mild	(31.7%)44	(36%)54	(39%)57	(48.9%)66	(31.9%)44
Moderate	(0/7%)1	(2.7%)4	(5.5%)8	(2.2%)3	(2.9%)4
Severe	(0/7%)1	(1.3%)2	(7%)1	(0/7%)1	—

a: Between right canine and lateral b: Between right lateral and central c: Between centrals

d : Between left central and lateral e: Between left lateral and canine

Table 3. Correlation between bone loss and canal size for each shape

Canal size	Min(mm)	Max(mm)	Mid
Bone loss			
For each shape			
hourglass	21 ^a	0.19(0.25)	0.32(0.047)
	11 ^b	0.029(0.87)	0.16(0.35)
	12 ^c	0.18(0.3)	0.38(0.032)
conical	21 ^a	0.037(0.82)	0.068(0.69)
	11 ^b	0.084(0.63)	0.033(0.85)
	12 ^c	0.23(0.22)	0.27(0.14)
funnel	21 ^a	0.093(0.59)	0.073(0.67)
	11 ^b	0.029(0.87)	0.19(0.28)
	12 ^c	0.11(0.54)	0.1(0.54)
cylindrical	21 ^a	0.3(0.063)	0.22(0.16)
	11 ^b	0.39(0.01)	0.33(0.03)
	12 ^c	0.41(0.007)	0.28(0.07)

a: Between right lateral and central b: Between centrals

c: Between left central and lateral

The following results were obtained from the effect of age and gender on the canal size in different shapes: The results showed that there was a significant relationship between the gender and maximum diameter of the canal in the hourglass shape ($p = 0.046$), but there was no significant relationship in other shapes ($P > 0.05$). The results also suggested a significant relationship between age with the maximum diameter of the conical canal ($p = 0.022$) and cylindrical shape canals (min part, $p = 0.018$), while no relationship was found in other shapes.

Discussion

The present study showed that nasopalatine canal had anatomical variations, different size and morphology. According to the results of the present study, the nasopalatine canal was mostly observed in the cylindrical shape, which agrees with the findings of Liang and Thakur et al. [14,15] However, hourglass shape was the most frequent shape in the study conducted by Etoz et al. who investigated various shapes of canal. [13]

This difference can be attributed to the difference in races. Accessory canals were significantly prevalent in the anterior palatal region (29%) specially near to the canine region, which was found in the study of de Oliveira-Santos et al. (accessory canal prevalence was 27.8% near to the canines and incisors). [16]

Thus, according to these results, the existence of these canals must be considered during placing implants in this region. In this study, the mean diameter of the nasopalatine canal was 2.36 ± 0.69 with a minimum and maximum of 0.8 and 4.1, respectively. Liang and Thakur also obtained somewhat similar result.^[14, 15] In this study, in the majority of cases, age and gender did not affect the canal size which is similar to the Panjnoush et al's study.^[17]

But Liang et al. showed that the canal size was enhanced in men and elders.^[14] This difference of results may be due to the differences in the sample size. CBCT is a new technology, whose development has created fundamental changes in the dentistry field. Conventional imaging provides two-dimensional images of the three-dimensional object, whereas CBCT can provide three-dimensional images in different planes, which is cost-effectiveness and provides the possibility of evaluation of the object in different planes.^[18] This technique can give unique information of the anterior palatal region, like diameter and morphology of nasopalatine canal, thickness of buccal and palatal bone plate. The results of this study illustrated a significant relationship between patients' dental status and buccal bone thickness that buccal bone thickness was reduced in edentulous patients.

This can compromise not only the placement of implant in this area, but also the patient's beauty. Similar results were also found in the study done by Fernández-Alonso et al.^[11] In addition, there was a significant relationship between the buccal bone thickness and the nasopalatine canal size so that, in the majority of cases, canal size was increased with a reduction in the diameter of the buccal bone plate.

In regarding to dental status, the periodontal condition of remaining anterior teeth must be evaluated when the bone level and dimension are measured.^[19, 20] The present study showed that there was a relationship between periodontal status (bone loss) and nasopalatine canal size.

Moreover, the results demonstrated that there was a relationship between two above variables in the hourglass shape between central and lateral teeth in left and right sides, and in the cylindrical shape between left and right lateral incisors so that the canal size was enhanced with the increase of the bone loss level. This result was similar to the previous result of the relationship between the reduction in buccal bone

thickness and an increase in the canal size. The justifiable explanation in this case can be due to the fact that with either aging or periodontal disease, the bone loss starts from the coronal parts of the ridge and this phenomenon causes bone resorption in this region that requires further investigation and assessment of the factors in this field.

By studying all these parameters, it is concluded that the present study examined the anatomical variation and prevalence of accessory canals in the anterior maxilla and showed that these variations were significant in terms of size and morphology. This can reflect the importance of three-dimensional images and evaluation of anatomical landmarks for implantation or the probability of presence of the pathologic lesions.

Conclusion

According to the results of the present study, the prevalence of accessory canals in the anterior maxilla was relatively significant and many different anatomical variations were observed for the nasopalatine canal. Canal shape, diameter and location of them are all important variables that should be considered during placing implants, for this reason, preoperative CBCT study of this region seems necessary.

Acknowledgements

The authors thank Research Committee of Faculty of Dentistry of Babol University of Medical Sciences for financial support of this research.

Funding: This article presented the results of a research project in Babol University of Medical Sciences (By Grant No: 9542316). Hereby, the funding and support of the Research Deputy of Babol University of Medical Sciences are highly appreciated.

Conflict of Interest: Authors deny any conflict of interest related to this study.

Author's contributions

The study was designed by Farida Abesi and Sina Fateme Saeedi. Data were collected by Fateme Saeedi. Results were evaluated by Soraya Khafri. Analysis and interpretation of data, drafting of the manuscript and critical revision of the manuscript for important intellectual content were performed by Soraya Khafri, Farida Abesi and Sina Haghaniifar. Supervision of the study was performed by Farida Abesi and Ehsan Moudi.

References

1. White, Stuart C, Pharoah, M J ,editors. Oral radiology: principles and interpretation. 7th ed. United States:St.Louis, Missouri : Elsevier; 2014.p.138,302,351.
2. Langland OE, Langlais RP, Preece JW. Principles of dental imaging. 2nd ed. Baltimore, Md.: Lippincott Williams & Wilkins; 2002.p.336.
3. Bodin I, Isacsson G, Julin P. Cysts of the nasopalatine duct. *Int J Oral Maxillofac Surg*1986;15:696–706.
4. Daley TD, Wysocki GP, Pringle GA. Relative incidence of odontogenic tumors and oral and jaw cysts in a canadian population. *Oral Surg Oral Med Oral Pathol* 1994; 77:276–80.
5. Swanson KS, Kaugars GE, Gunsolley JC. Nasopalatine duct cyst: An analysis of 334 cases. *J Oral Maxillofac Surg*1991; 49:268–71.
6. Mraiwa N, Jacobs R, Van Cleynenbreugel J, Sanderink G, Schutyser F, Suetens P, et al. The nasopalatine canal revisited using 2D and 3D CT imaging. *Dentomaxillofac Radiol*.2004 ;33:396-402.
7. Mamachan P, Dang V, Bhardwaj NS, DeSilva N, Kant P. Application of cone beam computerized tomography in implantology. *Indian J Dent Oral Health* 2017; March 25[Epub ahead of print]
8. McCrea SJ. Nasopalatine duct cyst, a delayed complication to successful dental implant placement: diagnosis and surgical management. *J Oral Implantol* 2014;40:189–95.
9. Spin-Neto R, Bedran TB, de Paula WN, de Freitas RM, de Oliveira Ramalho LT, Marcantonio E Jr. Incisive canal deflation for correct implant placement: case report. *Implant Dent* 2009;18:473–9.
10. Santos PL, Silva GH, da Silva RD, Da Silva Pereira FR, Gulinelli JL. Implant Anchorage in the Nasopalatine canal for the rehabilitation of severely atrophic maxilla. *Implant Dent* 2017; 26:324–7.
11. Fernández-Alonso A, Suárez-Quintanilla JA, Muinelo-Lorenzo J, Varela-Mallou J, Smyth-Chamosa E, Suárez-Cunqueiro MM. Critical anatomic region of nasopalatine canal based on tridimensional analysis: cone beam computed tomography. *Sci Rep* 2015; 5:1–12.
12. Bornstein MM, Balsiger R, Sendi P, von Arx T. Morphology of the nasopalatine canal and dental implant surgery: a radiographic analysis of 100 consecutive patients using limited cone-beam computed tomography. *Clin Oral Implants Res*2011; 22:295–301.
13. Etoz M, Sisman Y. Evaluation of the nasopalatine canal and variations with cone-beam computed tomography. *Surg Radiol Anat* 2014; 36 :805-12.
14. Liang X, Jacobs R, Martens W, Hu Y, Adriaenssens P, Quirynen M, et al. Macro- and micro-anatomical, histological and computed tomography scan characterization of the nasopalatine canal. *J Clin Periodontol* 2009;36:598-603.
15. Thakur AR, Burde K, Guttal K, Naikmasur VG. Anatomy and morphology of the nasopalatine canal using cone-beam computed tomography. *Imaging Sci Dent*2013; 43:273–81.
16. de Oliveira-Santos C, Rubira-Bullen IR, Monteiro SA, León JE, Jacobs R. Neurovascular anatomical variations in the anterior palate observed on CBCT images. *Clin Oral Implants Res* 2013;24:1044-8.
17. Panjnoush M, Norouzi H, Kheirandish Y, Shamshiri AR, Mofidi N Evaluation of Morphology and Anatomical Measurement of Nasopalatine Canal Using Cone Beam Computed Tomography. *J Dent (Tehran)* 2016; 13:287.
18. Suomalainen A1, Pakbaznejad Esmaeili E, Robinson S. Dentomaxillofacial imaging with panoramic views and cone beam CT. *Insights Imaging* 2015; 6: 1–16.
19. Fernández-Alonso A, Suárez-Quintanilla JA, Muinelo-Lorenzo J, Varela-Mallou J, Smyth-Chamosa E, Suárez-Cunqueiro MM. Critical anatomic region of nasopalatine canal based on tridimensional analysis: cone beam computed tomography. *Sci Rep* 2015; 5:12568.
20. Fleiner J, Hannig C, Schulze D, Stricker A, Jacobs R. Digital method for quantification of circumferential periodontal bone level using cone beam CT. *Clin Oral Investig*.2013; 17: 389-96.