

Case Report

Langerhans' cell histiocytosis with multiple radiolucent lesions in the body of the mandible, report of a case

Maryam Pazhutan (DDS)¹, Shirin Sakhdari (DDS)^{2✉}, Fatemeh Mashhadiabbas (DDS)³,
Mahsa Afghahi (DDS)⁴, Fatemeh Khodaei (DDS)⁵

1. Oral and Maxillofacial Radiologist, Tehran-Iran.
2. Assistant Professor, Department of Oral and Maxillofacial Radiology, Islamic Azad University, Dental Branch, Tehran–Iran.
3. Assistant Professor, Department of Oral & Maxillofacial Pathology, Faculty of Dentistry, Shahid Beheshti University of Medical Sciences, Tehran-Iran.
4. Assistant Professor, Department of Oral & Maxillofacial Radiology, Faculty of Dentistry, Tehran University of Medical Sciences, International Campus, Tehran-Iran.
5. Endodontist, Tehran-Iran.

✉ **Corresponding Author:** Shirin Sakhdari, Islamic Azad University, Dental Branch, Tehran–Iran.

Email: sh_sakhdari@dentaliau.ac.ir

Tel: +982122763446

Abstract

Introduction: Langerhans cell histiocytosis (LCH) refers to a group of rare reticuloendothelial system disorders and it occurs most often in young adults and children. A 57-year-old edentulous female patient who complained of dull pain in the posterior region of the mandible referred to the dental office, with a complaint of dull pain in the posterior region of the mandible. The lesion was diagnosed as LCH. Oral manifestations could be the first signs of Langerhans' cell histiocytosis. Therefore, the dentist must be aware of the oral symptoms so in order that the disease is not overlooked.

Keywords: Histiocytosis, Langerhans'-cell, Eosinophilic granuloma, Mandible

Received: 20 Dec 2013

Accepted: 9 Mar 2014

Citation for article: Pazhutan M, Sakhdari Sh, Mashhadiabbas F, Afghahi M, Khodaei F. Langerhans' cell histiocytosis with multiple radiolucent lesions in the body of the mandible; report of a case. *Caspian J Dent Res* 2014; 3:52-6.

هیستئوسیتوزیس سلول لانگرهانس به همراه رادیولوژی های

متعدد در تنه ی فک پایین: گزارش مورد

مریم پژوتن، شیرین سخدری*، فاطمه مشهدی عباس، مهسا افقهی، فاطمه خدایی

چکیده

مقدمه: هیستئوسیتوزیس سلول لانگرهانس به گروهی از اختلالات نادر سیستم رتیکیلواندوتلیال اطلاق می گردد که بیشتر در کودکان و جوانان بروز می کند. خانمی ۵۷ ساله و بی دندان با شکایت درد مبهم در خلف فک پایین به دندانپزشک مراجعه کرده است. تشخیص بیماری LCH بود. ضایعات دهانی ممکن است اولین علائم بیماری هیستئوسیتوزیس سلول لانگرهانس باشند. بنابراین دندانپزشک باید با علائم دهانی بیماری آشنایی داشته باشد تا بیماری نادیده گرفته نشود.

واژگان کلیدی: هیستئوسیتوزیس، سلول لانگرهانس، اتوزینوفیلیک گرانولوما، فک پایین

Introduction

The term "HistiocytosisX" refers to a group of rare reticuloendothelial system disorders which are characterized by proliferation of histiocyte-like cells (Langerhans' cells) (1). The disease occurs in a wide range of age, although most of the patients are children under 15years. In 1973 the term Langerhans' Cell Histiocytosis "LCH "has been announced as an alternative for "Histiocytosis X" (2). The condition is classified into 3 groups based on clinicopathologic manifestation.

Eosinophilic granuloma is the localized type of this condition and is predominantly manifested in bones including ribs, pelvis, long bones, skull and jaws (3, 4). Despite the condition is more common in children, it has been reported in older individuals people, too.

It might induce dull and continuous pain and results in edema, soft tissue mass, gingival bleeding, wounds and destruction of the alveolar bone (3). The radiographic appearance of the lesion is sometimes similar to periapical cysts, inflammatory conditions, vascular malformations, tumors and malignancies (5).

The acute diffuse type or Letterer-Siwe disease is characterized by widespread involvement of the skin, viscera and bone marrow and is mainly manifested in infants under 1 year of age. Also, the chronic diffuse type or Hand-Schüller-Christian disease, too, generally

affects children and young adolescents (6). The etiology of the condition is unknown and immunologic, infectious, environmental, genetic and neoplastic factors and hypersensitivity reactions to HHV6 and EBV antigens have been implicated (4).

The aim of the present report is this study aimed at presenting an uncommon case of LCH in a middle-aged female patient with bony lesions on panoramic radiographs similar to inflammatory lesions.

Case Report

A 57-year-old edentulous female patient who was wearing complete dentures referred to the dental office, with a complaint of continuous dull pain in the posterior region of the mandible for about 1 month.

Intraoral examination was performed by the dentist who suspected the denture of having problem and repaired the denture on the patient's request and based on the suspicion that the denture had a problem, the dentist repaired the denture on the patient's request.

The pain in she felt a sharp pain in this area persisted, therefore the dentist ordered a panoramic radiograph and referred the patient to the Faculty of Dentistry in Shahid Beheshti University of Medical Sciences and they suspected to have malignancy. Intraoral examination revealed healthy mucosa with

normal color and without any swelling or ulcers. anoramic radiography also indicated a lesion on the right lower premolar area, measuring approximately 1×1.5 cm, with relatively distinct non-cortical borders; another lesion was found in the molar area which measured approximately 2×3 cm and had indistinct borders at the alveolar crest, along with a decrease in bone density and bone loss (figure 1).

Due to persistent pain and the affected areas visible in the radiograph, a biopsy was taken with a suspicion of osteomyelitis, squamous cell carcinoma or metastatic malignant neoplasia. Pathologic evaluation of the sample was provided by the incisional biopsy of the right side of the mandible (1.5×2×4 cm) and the macroscopic view revealed a creamy-brown elastic tissue which seemed cystic in cut surface.

Microscopic evaluation of the specimen revealed connective tissue fragments which mainly consisted of diffuse infiltration of large, pale staining histiocyte with indented nuclei (figure 2, A and B).

Varying numbers of eosinophils were found between histiocyte-like cells. In addition, there were some lymphocytes and plasma cells plus hemorrhage in the tissue. Therefore, a diagnosis of LCH compatible with IHC for CD1a was reached.

In order to have thorough diagnostic data, after pathologic results were obtained, complementary examinations including scintigraphy, blood tests and additional imaging were ordered to have thorough diagnostic data including scintigraphy, blood tests and additional imaging.

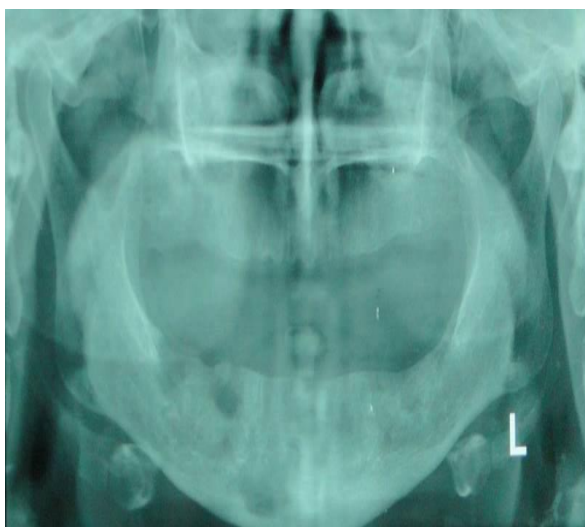


Figure 1. Two unilocular radiolucent areas are visible in the right molar and premolar regions, along with decreased bone density on the left side

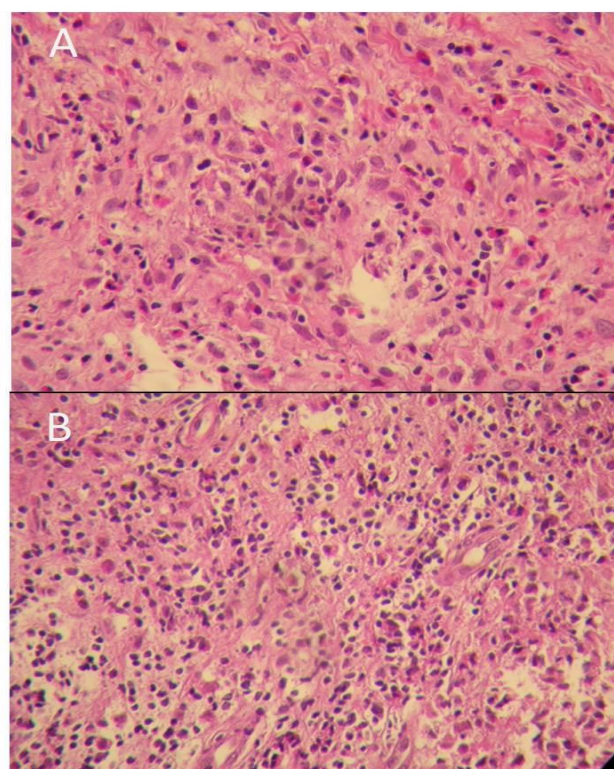


Figure 2. A and B: The histologic view of infiltration of Langerhans' cells and histiocyte along with eosinophils (arrows) (H&E, 100)

Scintigraphy was indicated to evaluate multiple tissue involvement but there are no specific laboratory tests for LCH. Blood tests were routinely performed and could reveal the extent of the disease (7, 8).

Skull radiographs and CBCT were performed because the maxilla, mandible and the skull were mostly affected bones (8). CT and MRI examinations were ordered to determine bone and soft tissue involvement in the whole body, too.

Laboratory tests: Hematologic test results only revealed an increase in RDW, therefore anisocytosis was reported. Scintigraphy with the use of ^{99m}Tc-MDP, revealed the involvement of the whole mandibular body and lesions on the maxilla specially on the right side. Also several abnormal activities on the tibia and at the distal ends of lower extremities were found (figure 3, A).

Imaging studies: Posteroanterior (PA) and lateral skull radiographs revealed no lesions. Mandibular CBCT revealed some perforated areas on the buccal and lingual aspects of the mandible, along with some sequestra (figure3, B). CT examination of the chest and abdomen did not reveal any lesions except for a nodule

measuring 5 mm in diameter around the right upper lobe of the lung. MRI examination revealed several cystic lesions in both femurs and the distal end of the tibia, without cortical destruction or osseous expansion. However, no soft tissue lesions were found.

The patient was referred to an oncologist for treatment after completion of the diagnostic steps. The patient underwent a 6-phase chemotherapy for 3 days with UP-16 methylprednisolone due to osseous metastasis and was currently being followed.

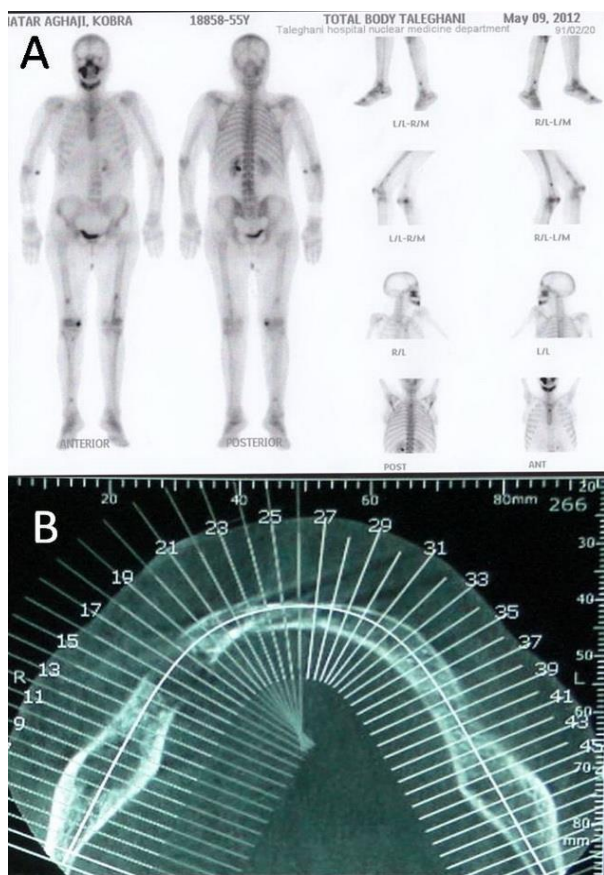


Figure 3. A: Scintigraphy shows involvement of the mandible, maxilla, tibia, lungs and pelvis. B: The axial view of CBCT of the mandible shows buccal and lingual cortices which have been perforated, along with sequestra

Discussion

Langerhans' cell histiocytosis (LCH) is rarely seen in adults, with an incidence rate of 1-2 per 1 million individuals (9, 10). Since the clinical and radiographic views are not specific, it is relatively difficult to diagnose the condition (10). Approximately 10% of all patients with LCH have oral lesions (3). The only cells

with a diagnostic value are the Langerhans' cells in the bone marrow, which are identified under the electron microscope by their rocket-shaped cytoplasm or "Birbeck granules" therefore; new diagnostic methods such as TEM (transmission electron microscopy) and IHC (immunohistochemistry) have considerably contributed to the histopathologic diagnosis (6).

Since LCH lacks any pathognomonic clinical or radiographic trait, certain diagnosis is based on the histologic and Immunohistochemical study of biopsy, and whenever CD1a, langerin (CD207) and S-100 protein are observed the diagnosis is positive (9). In this study there was no need for IHC panel.

The condition might be unifocal or multifocal. A unifocal condition is manifested in only one area and has good prognosis. The multifocal variant is less prevalent and skin lesions are seen in this variant (11).

Generally, advanced imaging techniques including skeletal scintigraphy, CT and MRI are necessary in LCH in order to determine whether the lesions are unifocal or multifocal (8). In this context, all these techniques were used for the patient reported here. The patient referred to the dental office with a chief complaint of pain under the removable mandibular denture. Panoramic radiographic and CBCT evaluations of the lytic osseous lesions increased the odds of osteomyelitis and malignant lesions such as multiple myeloma, because the radiographic views of this patient were not similar to the common form of LCH further, evaluations finally confirmed a diagnosis of systemic LCH.

Majority of the cases with mandibular involvement are under 20 years of age. Our case differs from usual distribution of the disease; however mandibular involvement was seen in the reported patient here. In the case presented here, the maxilla, vertebrae and distal bones were affected and a number of areas were also affected in the mandible.

Generally there is no significant gender difference (12); however, the case presented here was a woman aged 67.

A wide range of treatment modalities and techniques are available for this condition, from surgical curettage to radiotherapy and chemotherapy. Lesions which are accessible are best treated with surgical excision or curettage in the best way. Immunosuppressive techniques are recommended in multifocal lesions with functional deficiencies of vital organs. In general, treatment of LCH depends on the

lesion size, the extent of tissue involvement and whether the lesion is unifocal or multifocal. Chemotherapy with Methotrexate and Vinblastin, with Prednisolone, is recommended for the diffuse form of the condition (4, 8). In the case presented here, since the lesion was multifocal and there was systemic involvement, chemotherapy was administered in this case. In the present case, the prognosis was poor due to systemic involvement and the low response to treatment at 1-year follow-up.

The recurrence rate depends on the location of the lesion. Therefore, the patient should be followed for a long time. The present case has not exhibited recurrence after follow-up for 1 year. This case is a reminder that possibility of occurrence of this disease exists in the oral cavity. This report also shows the importance of oral examinations in the diagnosis of a systemic condition. Early detection of the signs of systemic disease in the oral cavity by the dentist plays a significant role in the prognosis.

Acknowledgments

Authors would like to thank Dr. Ali Mirzaiepour for sharing the patient's data.

Conflict of interest: There was no conflict of interest.

References

1. Nevile BW, Damm DD, Allen CM, Bouquot JE. Oral and Maxillofacial Pathology. 2nded. Philadelphia: WB Saunders Company; 2002. p. 513-5.
2. Guna Shekhar M, Ponnudurai A. Langerhans Cell Histiocytosis Involving Maxilla and mandible. J Dent 2009; 6:97-101.
3. White Sc, Pharoah MJ .Oral radiology: Principles and Inter Pretation. 6thed. St Louis, Mo: Mosby Elsevier; 2009. p. 448-52.
4. Krol AL. Keratodermas. In: Bologna J, Jorizzo JL, Rapini RP. Dermatology. 2nded. London: Elsevier; 2008. p. 777-90.
5. Watzke IM, Millesi W, Kermer C, Gisslinger H. Multifocal eosinophilic granuloma of the jaw: long-term follow-up of a novel intraosseous corticoid treatment for recalcitrant lesions. Oral Surg Oral Med Oral Pathol Oral Radiol Endod. 2000; 90: 317-22.
6. Stewart JCB. Benign Nonodontogenic Tumors. In: Regezi JA, Sciabba JJ, Jordan RCK. Oral Pathology: Clinical Pathologic Correlations. 4thed. St.louis, Mo: Saunders; 2003. p. 303-5.
7. Patten DK, Wani Z, Tolley N. Solitary langerhans histiocytosis of the thyroid gland: a case report and literature review. Head Neck Pathol 2012; 6: 279–89.
8. Madrigal-Martínez-Pereda C, Guerrero-Rodríguez V, Guisado-Moya B, Meniz-García C. Langerhans cell histiocytosis: literature review and descriptive analysis of oral manifestations. Med Oral Patol Oral Cir Bucal 2009; 14: E222-8.
9. Yashoda-Devi B, Rakesh N, Agarwal M. Langerhans cell histiocytosis with oral manifestations: a rare and unusual case report. J Clin Exp Dent 2012; 4: e252-5.
10. Buchmann L, Emami A, Wei JL. Primary head and neck Langerhans cell histiocytosis in children. Otolaryngol Head Neck Surg 2006; 135: 312-7.
11. Hicks J, Flaitz CM. Langerhans cell histiocytosis: current insights in a molecular age with emphasis on clinical oral and maxillofacial pathology practice. Oral Surg Oral Med Oral Pathol Oral Radiol Endod 2005; 100 (Suppl.2): S42-66.
12. Li Z, Li ZB, Zhang W, Li JR, Wang SP, Cheng Y, et al. Eosinophilic granuloma of the jaws: An analysis of Clinical and radiographic Presentation. Oral Oncol 2006; 42: 574-80.