

A histopathological study of smoking on free gingiva in patients with moderate to severe periodontitis

Maryam Seyedmajidi (DDS)^{1✉}, Parand Keshavarzi (DDS)², Ali Bijani (MD)³, Reza Faraji⁴

Neda Babaee(DDS)⁵

1. Associate Professor, Dental Materials Research Center, Department of Oral & Maxillofacial Pathology, Faculty of Dentistry, Babol University of Medical Sciences, Babol-Iran.

2. Assistant Professor, Department of Periodontics, Faculty of Dentistry, Babol University of Medical Sciences, Babol-Iran.

3. General Practitioner, Non-Communicable Pediatric Diseases Research Center, Babol University of Medical Sciences, Babol-Iran.

4. Dental Student, Dentistry Student Research Committee, Faculty of Dentistry, Babol University of Medical Sciences, Babol-Iran.

5. Assistant Professor, Department of Oral Medicine, Faculty of Dentistry, Babol University of Medical Sciences, Babol-Iran.

✉Corresponding Author: Maryam Seyedmajidi, Faculty of Dentistry, Babol University of Medical Sciences, Babol-Iran.

Email: ms_majidi79@yahoo.com

Tel: +98112291408

Abstract

Introduction Cigarette smoking has been recognized to be a risk factor for progression of periodontal disease. Due to less inflammation and bleeding in the presence of clinical signs of periodontal disease in smokers than in nonsmokers and given the conflicting results of studies on changes in the epithelium and gingival connective tissue by smoking, this study was performed to evaluate the thickness and keratosis on the epithelium of free and sulcular gingival tissue in smokers and nonsmokers patients with moderate to advanced periodontitis.

Methods: In this cross sectional study, biopsies were obtained from palatal gingival of 60 patients with moderate to advanced periodontitis (30 smokers and 30 nonsmokers). These biopsies were histologically processed, serially sectioned at 5 microns, stained with H. E. and examined by image analysis software (analysis-SL-starter), which was used to perform the morphometric evaluation of the outer and inner epithelial thickness, keratosis and vascularity in connective tissue. The data were analyzed with SPSS 17, t-test, Mann-Whitney Test, and Pearson correlation. $p < 0.05$ was considered significant.

Results: Histopathological examination showed significant association between smoking and CAL ($p = 0.048$), keratosis on outer epithelium ($p = 0.020$) and mean of thickness of outer ($p = 0.023$) and inner ($p < 0.001$) marginal gingival epithelium but gingival vascular density in nonsmokers was more than smokers ($p = 0.002$). Collagenized connective tissue was observed in smokers more than nonsmokers. ($p < 0.001$)

Conclusions: It seems that the reduction of the clinical signs of inflammation in the gingival tissue of smokers is due to changes in gingival epithelium and connective tissue from smoking.

Keywords: Cigarette, Oral epithelium, Gingiva, Keratinization

بررسی هیستوپاتولوژیکی اثر استعمال سیگار بر لثه آزاد بیماران مبتلا به

پریودنتیت متوسط تا پیشرفته

چکیده

مقدمه: استعمال سیگار به عنوان یک ریسک فاکتور برای پیشرفت بیماری پریودنتال شناخته می شود با توجه به کمتر بودن علائم بالینی التهاب و خونریزی در حضور بیماری پریودنتال در سیگاری ها نسبت به غیرسیگاری ها و با توجه به نتایج متناقض مطالعات انجام شده راجع به تغییرات ایجاد شده در اپیتلیوم و نسج همبندی لثه توسط استعمال سیگار، این مطالعه با هدف ارزیابی ضخامت اپیتلیوم آزاد و سالکولار، کراتینیزاسیون سطح آنها و بررسی عروق خونی در نسج همبندی لثه مبتلا به پریودنتیت متوسط تا پیشرفته در دو گروه سیگاری و غیر سیگاری انجام پذیرفت.

مواد و روش ها: در این مطالعه مقطعی، نمونه های بافتی از لثه پالاتال ۶۰ بیمار مبتلا به پریودنتیت متوسط تا پیشرفته (۳۰ فرد سیگاری و ۳۰ فرد غیر سیگاری) برداشته شد. سپس اسلایدهای میکروسکوپی به دست آمده از بلوکهای پارافینه نمونه های مذکور، تصویر برداری شد. تصاویر توسط نرم افزار آنالیز تصویری (Analysis-SL-Starter) از نظر ضخامت اپیتلیوم آزاد و سالکولار، کراتینیزاسیون سطح آنها و بررسی عروق خونی در نسج همبندی لثه بررسی شدند. اطلاعات توسط نرم افزار آماری SPSS 18 و تستهای آماری Mann-Whitney Test, Pearson correlation, t-test مورد تجزیه و تحلیل قرار گرفت و $p \leq 0.05$ معنی دار در نظر گرفته شد.

یافته ها: بررسی های هیستوپاتولوژیکی ارتباط معناداری بین استعمال سیگار با Clinical Attachment Loss ($p=0.048$) ضخامت کراتینیزاسیون سطح خارجی لثه ($p=0.020$)، میانگین ضخامت اپیتلیوم داخلی ($p<0.001$) و خارجی ($p=0.023$) لثه آزاد نشان دادند که در تمامی موارد در سیگاری مقادیر بیشتری از متغیرهای مذکور دیده شد. البته تراکم عروقی در لثه افراد غیر سیگاری بیشتر بود ($p=0.002$) کلاژنیزه بودن بافت همبندی نیز به طور معنی داری در افراد سیگاری نسبت به افراد غیرسیگاری بیشتر مشاهده شد ($p<0.001$)

نتیجه گیری: به نظر می رسد که کاهش علائم بالینی التهاب در بافت لثه ای افراد سیگاری در مقایسه با غیر سیگاری ناشی از تغییرات ایجاد شده در اپی تلیوم و نسج همبندی لثه ناشی از استعمال سیگار باشد.

واژگان کلیدی: سیگار، اپیتلیوم دهان، لثه، کراتینیزاسیون

Introduction

Tobacco use constitutes a risk factor for periodontal disease. Numerous epidemiologic studies using clinical and radiologic evaluations confirm that periodontitis is more frequent and more severe among smokers compared to nonsmokers (1-3). The detrimental effect of tobacco on tissues of the oral cavity results in hyperkeratinization of superficial epithelia, which may itself be considered a preneoplastic lesion and manifest as oral leukoplakia lesions, as suggested in different studies (4).

Smokers experience a greater probe depth and gingival erosion, as well as being susceptible to more advanced and severe forms of periodontitis (5). The inflammatory response of the gums is reduced in smokers, which is associated with reduced gingival bleeding, tissue erythema, edema and blood vascularity in marginal gingival tissue. This may be related to cotinine, a metabolic product of nicotine which serves as a peripheral vasoconstrictor in gingival vessels (6). Although some researchers believe that the inflammatory conditions of smokers reduce their gingival vascularity compared to nonsmokers (7), Lindeboom et al. and Kumar observed no significant difference in gingival vascularity between smokers and nonsmokers (8, 9).

The outer gingival epithelium is keratinized, parakeratinized or a combination of two (7). The sulcular epithelium, however, is thin and nonkeratinized and it may keratinize when exposed to the internal oral environment. On the other hand, the outer epithelium will lose its keratinization when in contact with teeth (7).

Inflammation in gums may reduce keratinization or manifest as parakeratinization (10). Bajagic et al. believe that smokers with periodontal disease manifest an increased thickness of basal epithelium and the keratinous layer, and epithelial thickening may reduce the clinical symptoms of inflammation in gingival tissue (6). In a study by Pejic et al (11), the samples taken from smokers indicated greater epithelial thickness. Gultekin et al. (5), on the other hand, found no significant difference between epithelial thickness of smokers and nonsmokers.

Rahman et al. observed no definite histopathologic difference between smokers and nonsmokers in their gingival tissue; however, smokers manifested higher rates of epithelial keratosis, inflammatory cells,

vascularity and collagen fibers in their connective tissue (12).

In addition, Saebi et al. observed that tobacco use increased the mean thickness of keratinous epithelia in free gingival, which might be considered as preneoplastic lesions (4).

The impact of cigarette smoke is reportedly greater in the upper jaw compared to the lower. In smokers, the palatal aspect of the maxillary teeth had a deeper pocket as they were more exposed to tobacco smoke (13). Considering the controversial findings of previous studies regarding the gingival epithelial changes caused by smoking, as well as the large number of smokers and the fact that the oral cavity is the first organ to come in contact with cigarette smoke, we undertook the present study to investigate the impact of cigarette smoke on gingival with moderate to advanced periodontitis.

Methods

This is a cross-sectional study on 60 patients with moderate to advanced periodontitis (attachment loss >3mm) referring to the Periodontology Department of Babol School of Dentistry. Half of these patients (30 individuals) were smokers and the other half (30 individuals) were nonsmokers. The patients were recruited through simple sampling. Individuals who smoked at least 20 cigarettes per day for 5 years were considered smokers. The pregnant women and individuals who used other narcotics were excluded from the study.

We used data sheets to collect the necessary information, including demographic data, smoking status, duration and degree of smoking according to the patients' self declaration, probing depth of the surgical area, clinical attachment loss of the surgical area, mean thickness of the keratinous layer, mean maximal thickness of inner and outer epithelia, mean minimal thickness of inner and outer epithelia collagenization of the connective tissue, and vessel count of each area.

Prior to periodontal surgery, the data sheet was completed for all the patients. The probing depth was measured for the area nominated for surgical excision. All patients underwent undisplaced flap surgery and the collar part of the palatal gingival in the upper gingival, which was excised and supposed to be disposed of, collected as specimen.

The specimens were fixated for at least 24 hours in 10% formalin solution and paraffin blocks were prepared according to the conventional protocol. The paraffin blocks were sectioned at appropriate intervals with 5mm thickness and stained in the ordinary fashion using hematoxylin and eosin (H-E) staining. Once mounted on a glass slide and dried, the specimens were ready for microscopy.

The slides were studied under a light microscope. Initially, at least 3 and at the most 6 images at x10 magnification were obtained from each slide using the Olympus DP12 camera mounted on Olympus BX41 microscope (Tokyo, Japan). The measurements of maximal and minimal thickness of inner and outer epithelia and the keratinous layer were made using Analysis SL Starter software.

For each section, measurements were made at three spots and a mean value was recorded for areas with maximal epithelial thickness, areas with minimal epithelial thickness, and the thickness of keratinous layer. Collagenization of the connective tissue was studied and documented. In addition, the connective tissue was investigated at x10 magnification to find the area with the greatest vascularity, and then the number of vessels in three fields at x40 magnification was counted and reported as mean. After microscopic evaluations, the findings were recorded in the patients' data sheets and analyzed on SPSS software version 17

using t-test, Pearson correlation, and Mann-Whitney Test. P values<0.05 were considered significant.

Results

The study was conducted on 60 histologic samples collected from palatal gingival of 60 patients with moderate to advanced periodontitis (30 smokers and 30 nonsmokers) including 42 men (70%) and 18 women (30%). The mean age of patients was 42.01 (± 7.74) years, ranging from 26-60 years. The smokers consisted of 30 men and the nonsmokers consisted of 18 women and 12 men.

Comparing the abovementioned variables between smokers and nonsmokers revealed no significant difference in age, probing pocket depth (PPD), minimal thickness of outer epithelium and thickness of the keratinous layer over the inner epithelium.

Nevertheless, variables of CAL, maximal thickness of outer epithelium, maximal and minimal thickness of the inner epithelium, thickness of the keratinous layer over the outer epithelium, and connective tissue vascularity were significantly different between the two groups (table 1) (figures 1, 2).

The nonparametric Mann-Whitney Test yielded similar results to t-test. Also, none of the variables were significantly different between the two sexes in the control group.

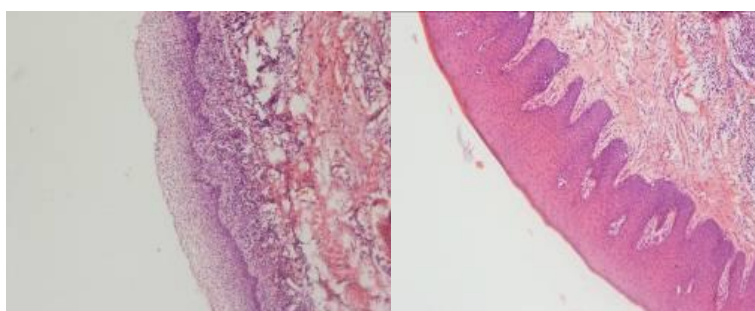


Figure 1. inner (sulcular) epithelium of gums (right)–outer epithelium of gums (left) in a nonsmoker (H-E staining, x10)

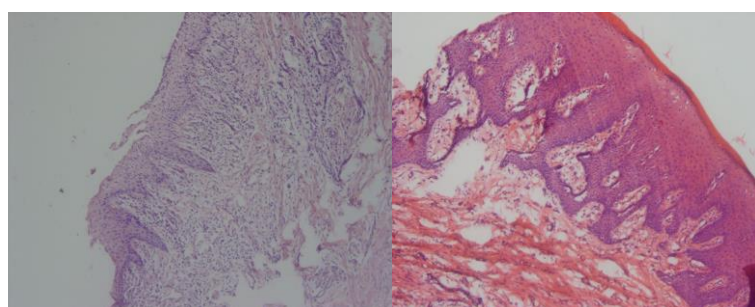


Figure 2. inner (sulcular) epithelium of gums (left)–outer epithelium of gums (right) in a smoker (H-E staining, x10)

Table 1. Comparison of study variables in smokers and nonsmokers using t-test

Variable	Group	Mean±SD	P Value
Age	Nonsmokers	41.50±8.64	0.610
	Smokers	42.53±6.85	
Pocket depth (PPD)	Nonsmokers	5.23±1.54	0.792
	Smokers	5.33±1.37	
CAL	Nonsmokers	4.9±1.63	0.048
	Smokers	5.66±1.29	
Maximal thickness of outer epithelium	Nonsmokers	114.76±26.25	0.023
	Smokers	135.16±39.70	
Minimal thickness of outer epithelium	Nonsmokers	31.67±10.71	0.189
	Smokers	35.81±13.27	
Maximal thickness of inner epithelium	Nonsmokers	30.79±12.82	0.000
	Smokers	47.14±18.53	
Minimal thickness of inner epithelium	Nonsmokers	43.52±21.49	0.12
	Smokers	57.97±20.74	
Thickness of keratinous layer over the outer epithelium	Nonsmokers	4.57±1.54	0.020
	Smokers	6.67±4.36	
Thickness of keratinous layer over the inner epithelium	Nonsmokers	0.31±0.91	0.152
	Smokers	0.74±1.37	
Mean thickness of outer epithelium	Nonsmokers	73.22±15.79	0.023
	Smokers	85.48±23.93	
Mean thickness of inner epithelium	Nonsmokers	22.65±9.71	0.000
	Smokers	33.23±11.49	
Vascularity	Nonsmokers	8.17±5.95	0.002
	Smokers	4.06±2.99	

Collagenization of the connective tissue was significantly higher in smokers compared to nonsmokers ($p<0.001$). In nonsmokers, collagenized connective tissue was found in 14 individuals (46%), whereas, only 1 case (3%) of smokers did not have collagenized connective tissue. We found a positive correlation between the number of cigarettes smoked and PPD ($p=0.010$, $r=0.463$). A similar relationship was found between CAL and pack year ($p=0.001$, $r=0.557$) and the number of cigarettes smoked ($p=0.021$, $r=0.418$).

We also observed a positive correlation between maximal thickness of the inner epithelium and CAL ($p=0.010$, $r=0.328$). Another finding was the clear difference in collagenization of connective tissue between smokers and nonsmokers ($p<0.0001$). In nonsmokers, collagenized connective tissue was found in 14 individuals (46%), whereas, only 1 case (3%) of smokers did not have collagenized connective tissue.

Discussion

In the present study, smokers showed significantly higher maximal inner and outer epithelial thickness and

minimal inner epithelial thickness compared to nonsmokers.

Although the minimal epithelial thickness was higher in smokers, the difference was not statistically significant. In general, the mean thickness of inner and outer epithelial thickness was significantly greater in smokers. Similarly, Luomanen (14) and Bajagic (6) and Pejic (11) reported increased thickness of epithelium in specimens obtained from gingival of smokers. On the other hand, Villar (15), Saebi (4) and Gultekin (5) did not find a significant difference in epithelial thickness between smokers and nonsmokers.

The discrepancy might be attributed to the larger number of samples in the present study, as well as the fact that our samples were obtained only from the palatal region which was more directly exposed to cigarette smoke, whereas, other studies collected specimens from the different regions of the oral cavity.

The thickness of the keratinous layer over the outer epithelium was greater in smokers compared to nonsmokers, whereas, no such difference was found in the case of inner epithelium, which was similar to the findings of Saebi (4).

In the present study, the vascularity was significantly higher in nonsmokers compared to smokers, while Lindeboom and Kumar reported no significant difference between vascularity of smokers and nonsmokers (8, 9). Rahman et al, on the other hand, reported greater vascularity in smokers compared to nonsmokers (12). The lower vascularity of smokers than nonsmokers might be attributed to less bleeding on probing and few clinical symptoms of periodontitis in smoker patients compared to nonsmokers.

Another finding was the higher CAL in smokers than nonsmokers. Pocket depth, on the other hand, was not significantly different between the two groups, albeit greater in smokers. Gunsolley et al reported a strong relationship between smoking and CAL (16), which was consistent with our findings. Nevertheless, Bouclin et al found that cigarette smokers had significantly greater pocket depth than nonsmokers (17).

We found greater amounts of collagen in gingival connective tissue of smokers. Similarly, Bouclin et al indicated greater collagenization in connective tissue of smokers (17) whereas, Luomanen et al reported less collagenization in smokers (14).

The difference might be due to the fact that Luomanen recruited patients using non-inhalational tobacco products, whereas, our patients smoked tobacco. On the other hand, collagenization of the connective tissue in smokers may be accounted for the reduced clinical symptoms of gingival inflammation in them.

Another result is that the lack of significant difference between the two sexes in the control group indicates that sex cannot be a confounding factor in the present study.

Conclusion

Smokers had greater mean thickness of inner and outer epithelia, greater thickness of the keratinous layer over the outer epithelium, and greater collagenization in connective tissue of their gum. On the other hand, nonsmokers showed greater vascularity.

All these findings may be accounted for the reduced manifestation of clinical symptoms of inflammation in the setting of an equal or more severe periodontal disease in smokers compared to nonsmokers.

Funding: The current study was funded by the Deputy of Research and Technology of Babol University of Medical Sciences under project registration number 8215110. This study is the result of the doctoral dissertation of Dr. Reza Faraji, dentistry student at Babol University of Medical Sciences.

Conflict of interest: There was no conflict of interest.

References

- Martinez-Canut P, Lorca A, Magan. Smoking and periodontal disease severity. *J Clin Periodontol* 1995; 22: 743-9.
- Malhotra R, Kapoor A, Grover V, Kaushal S. Nicotine and periodontal tissues. *J Indian Soc Periodontol* 2010; 14: 72-9.
- Calsina G, Ramón JM, Echeverría JJ. Effects of smoking on periodontal tissues. *J Clin Periodontol* 2002; 29: 771-6.
- Saebi KH, Eslami B, Fathieh A, Poorsepanj G. The effect of smoking on sulcular epithelial keratosis. *J Dent Sch* 2003; 21: 22-30.[In Persian]
- Gültekin SE, Sengüven B, Karaduman B. The effect of smoking on epithelial proliferation in healthy and periodontally diseased marginal gingival epithelium. *J Periodontol* 2008; 79: 1444-50.
- Bajagic V, Pejicic A, Zivkovic V, Petrovic A. Histochemical study of gingival epithelium in smokers and non-smokers. *Acta Facultatis Medicae Naissensis* 2006; 23: 151-4.
- Carranza FA, Newman MG, Takei HH, Klokkevold PR. Carranza's clinical periodontology. 10th ed. St Louis: Saunders Company; 2006. p. 46-67, 100-9, 251-9.
- Lindeboom JA, Mathura KR, Harkisoen S, Van den Akker HP, Ince C. Effect of smoking on the gingival capillary density: assessment of gingival capillary density with orthogonal polarization spectral imaging. *J Clin Periodontol*. 2005; 32: 1208-12.
- Kumar V, Faizuddin M. Effect of smoking on gingival microvasculature: A histological study. *J Indian Soc Periodontol* 2011; 15: 344-8.
- Nanci A. Ten Cate's oral histology: development, structure, and function. 7th ed. St.louis: Mosby Elsevier; 2008. p.319-33.
- Ana S, Pejicic, Vesna D, Zivkovic, Vukadin R, Bajagic, Dimitrije S, Mirkovic. Histological

- changes of gingival epithelium in smokers and non-smokers. *Cent Eur J Med* 2012; 7: 756-60.
12. Rahman BU, Rahman MM, Arslan A. The effects of cigarette smoking on human gingival tissues (a histopathological study). *J Pak Med Assoc* 1994; 44:210-2.
13. Ketabi M, Mahabadi M. Effects of smoking on dental implant procedures. *J Isfahan Dent Sch* 2007; 3: 145-52.[In Persian]
14. Luomanen M, Tiitta O, Heikinheimo K, Heinaro I, Happonen RP. Effect of snuff on cytokeratin expression in oral vestibular sulcus epithelium. *J Oral Pathol Med* 1997; 26: 110-6.
15. Villar CC, de Lima AF. Smoking influences on the thickness of marginal gingival epithelium. *Pesqui Odontol Bras* 2003; 17: 41-5.
16. Gunsolley JC, Quinn SM, Tew J, Gooss CM, Brooks CN, Schenkein HA. The effect of smoking on individuals with minimal periodontal destruction. *J Periodontol*. 1998; 69: 165-70.
17. Bouclin R, Landry RG, Noreau G. The effects of smoking on periodontal structures: a literature review. *J Can Dent Assoc* 1997; 63: 356, 360-3.