

## Original Article

## Histopathological evaluation of dental pulp of cat after using of sodium sulfonate in composite restorative treatment

Homayoun Alaghehmand (DDS)<sup>1</sup>, Maryam Seyedmajidi (DDS)<sup>2✉</sup>, Behzad Amiri-Andi(DDS)<sup>3</sup>  
Neda Babaei (DDS)<sup>4</sup>

1. Associate Professor, Dental Materials Research Center, Department of Operative Dentistry, Faculty of Dentistry, Babol University of Medical Sciences, Babol- Iran.
2. Associate Professor, Dental Materials Research Center, Department of Oral & Maxillofacial Pathology, Faculty of Dentistry, Babol University of Medical Sciences, Babol- Iran.
3. General Dentist.
4. Assistant Professor, Department of Oral Medicine, Faculty of Dentistry, Babol University of Medical Sciences, Babol-Iran.

✉Corresponding Author: Maryam Seyedmajidi, Faculty of Dentistry, Babol University of Medical Sciences, Babol-Iran.

Email: ms\_majidi79@yahoo.com

Tel: +981112291408

### Abstract

**Introduction:** Previous researches showed that neutral soaps significantly increased bond strength and decreased microleakage of dentin bonding agents. The aim of this study was histopathological evaluation of the effect of sodium sulfonate application as neutral soap on the cat's dental pulp after an ideal composite restorative treatment.

**Methods:** Ten adult cats with 40 caries-free canine teeth were selected for the study. Class V cavities were prepared in the buccal surfaces of all the teeth. The teeth of the right quadrants were treated with composite, whereas the teeth of the left quadrants were primarily etched, after using of sodium sulfonate solution, they treated with composite.

The first five cats were killed after one week and the other five cats after one month. The teeth were fixed, decalcified and after being sliced, paraffined blocks were made and microscopic slides were prepared and histologically evaluated.

**Results:** The results of the histological evaluation showed that there were no statistically significant differences between the intensity of inflammation in the pulp of the teeth in the right and left quadrants after one week ( $p=1.000$ ) and one month ( $p=0.773$ ).

However, there was significant difference after one week regarding predentin formation ( $p=0.017$ ) and in the teeth of the left quadrants, the formation of predentin was more than the right quadrants, but no meaningful difference was observed after one month ( $p=0.203$ ).

**Conclusions:** It seems that the sodium sulfonate in composite restorative treatments without fear of damage to the pulp can be used.

**Keywords:** Composite, Dentin bonding agents, Sodium sulfonate, Microleakage, Dental pulp

## بررسی هیستوپاتولوژیکی پالپ دندان گربه به دنبال استفاده از

### سولفونات سدیم در درمانهای ترمیمی با کامپوزیت

#### چکیده

**مقدمه:** تحقیقات گذشته نشان داد صابون خنثی به طور مشخصی باعث افزایش استحکام باند و کاهش ریزش مواد چسبنده عاجی می شود. هدف از این مطالعه بررسی هیستوپاتولوژیک تأثیر استفاده از سولفونات سدیم به عنوان صابون خنثی بر پالپ دندان گربه پس از یک درمان ترمیمی با کامپوزیت بود.

**مواد و روش ها:** ۱۰ گربه بالغ دارای ۴۰ دندان نیش عاری از پوسیدگی جهت مطالعه انتخاب شدند و حفرات کلاس V در باکال آنها ایجاد شد. دندانهای سمت راست با کامپازیت و دندانهای سمت چپ، پس از اچ شدن و استعمال محلول سولفونات سدیم، ترمیم شدند. پنج گربه بعد از یک هفته و پنج گربه پس از یکماه کشته شدند. دندانها فیکس و دکلسیفیه شدند و پس از برش و تهیه بلوکهای پارافینه، اسلایدهای میکروسکوپی تهیه و از نظر هیستوپاتولوژیکی بررسی شدند.

**یافته ها:** نتایج آماری نشان داد که در بررسی هیستوپاتولوژیک پالپ میان دندانهای سمت چپ و راست پس از یک هفته ( $p=1.000$ ) و یک ماه ( $p=0.773$ ) اختلاف معنی داری وجود نداشت ولی از نظر تشکیل پره دنتین، پس از یک هفته آزمایش ( $p=0.017$ ) اختلاف معنی داری دیده شد. بدین صورت که در دندانهای سمت چپ، ایجاد پره دنتین بیشتر از سمت راست بود ولی پس از یک ماه اختلاف معنی داری وجود نداشت. ( $p=0.203$ )

**نتیجه گیری:** به نظر می رسد بتوان از سولفونات سدیم در درمانهای ترمیمی بدون ترس از آسیب رساندن به پالپ دندان استفاده نمود.

**واژگان کلیدی:** کامپازیت، مواد چسبنده عاجی، سولفونات سدیم، ریزش، پالپ دندان

## Introduction

With the daily and heavily use of light-cured composite resins in restorative treatments of posterior teeth, researches have concentrated on the techniques that lead to the achievement of maximum physico-mechanical properties of composites and the increase in durability of composite restorations (1).

There are still a huge number of sophisticated and baffling problems that negatively affect the success of light-cured composites used in posterior teeth (2). Shrinkage as a result of polymerization characteristic of composite resins is one of these problems. This phenomenon in light-cured composites causes shrinkage forces and tensile stresses, which are capable of separating composite from the tooth surface and reducing the bond strength between them (3, 4). Various methods had been suggested to reduce the polymerization shrinkage, but none of them could defeat the detachment of composite from the tooth until now.

One of the best methods suggested for reducing the detachment of composite from the tooth was the application of dentin bonding agents to create strong bond strength between composite and the tooth (5). With the increasing amount of dentin bonding agents in the market, the detachment of composite from the tooth has greatly decreased, but has not yet been removed completely. Bonding restorations have more benefits than traditional and nonbonding agents (5, 6).

Studies on human and animals have shown that the use of dentin bonding agents causes little damage on pulp. The inflammatory responses from the pulp can be related to the stimulation and burning ability of the diffusive components of dentin bonding agents that are released after the treatment with light. This usually happens when there is a thin layer of remaining dentin or when pulp is exposed during access cavity preparation (7).

Transient inflammatory changes in the formation of disorganized dentin of pulp are histologically observed. Since the attachment of dentin bonding agents and resin components to dentin is not complete, diffusive materials penetrate the dentinal tubules and damage the pulp cells (8). The vitality of the pulp after the treatment is dependent on the severity of the inflammatory response caused by dentin bonding agents. This is the main concern in clinical trials since an irreversible pulpal response caused by dentin bonding agents had to be treated with root canal

therapy (7). El-Housseiny, et al. (9) evaluated the effect of caries detector dyes and cavity-cleansing agent on composite resin bonding to enamel and dentin and concluded that using the caries detector dyes and/or chlorhexidine cavity cleanser before acid etching does not significantly affect composite bonding to enamel and dentin. Owens (10) stated that in the groups in which anti-microbial agents were used after the etching, microleakage was less in the groups that did not use these agents in them.

Say et al. (11) evaluated the effect of cavity-disinfectant agents on the bond strength of dentin bonding agents. The results showed that the application of chlorhexidine and benzalkonium chloride solution 1% as cavity-disinfectant agents after etching, did not affect the shear bond strength and tensile bond strength of applied dentin bonding agents.

Previous researches (12-14). have studied the effect of acidic, basic, and inert soaps on bond strength and microleakage of dentin bonding agents. They concluded that inert soaps (sodium sulfonate) significantly increased bond strength and decreased microleakage. The aim of this study was to evaluate the histopathological effect of using sodium sulfonate as neutral soap on pulp in class V composite restorations.

## Methods

Approval was obtained from the Research Ethics Committee of Babol University of Medical Sciences and the present study was conducted in the Research Center of Babol University of Medical Sciences on 40 caries-free canine teeth of 10 domestic cats with approximately similar weights (2-2.5 kg) and ages (1.5-2 years old). The cats had been kept in animal house center of Babol University of Medical Sciences. Each selected cat was examined by a veterinary physician. Then, to destroy the ticks, anti-tick collars and anti-parasite medications (Mebendazole and Droncit) were used.

Each cat was separately put in a cage and was cleaned daily. Each cat was fed with standard dry food regimen and water and milk under the supervision of a veterinarian. The cats were routinely examined and if necessary treated by a veterinary physician. After the confirmation of cats' health status by a veterinary physician, they were ready for the study.

Before general anesthesia, 1 cc diazepam was injected intra muscularly to relax the cat, and after 15

minutes, the combination of 1.5 mg/kg ketamine hydrochloride 10 mg and acepromazine were injected into the gluteus maximus for the purpose of general anesthesia. To avoid the dryness of cornea, sterile ophthalmic ointment of vitamin A was used and the eyes of the cat were kept closed using bands. The veterinarian checked the vital signs of the animal throughout the process.

With the use of a small fissure bur, the cavities with the dimensions of 1.5\*2.5 mm and the depth of 0.5 mm in the buccal surface of the teeth were prepared so that the distance of gingival margin from gingiva was 1 mm. The cavities were treated using two methods: canines of the left lower or upper quadrants were primarily etched with phosphoric acid 37%, rinsed for 30 seconds, and dried.

Then sodium sulfonate solution (with inert PH made in Dental Materials Research Center of Babol) was applied on the cavities for 30 seconds. After the irrigation and half-dryness of the cavities, Exite dentin bonding agent (Liechtenstein, Ivoclar vivadent) was used and cured with Astralis 7 light curing instrument (Liechtenstein, Ivoclar vivadent) for 20 seconds. Then, A3 Teric Ceram composite material (Liechtenstein, Ivoclar vivadent) was used for the dental restorations. The two canines of the right quadrants of each cat were treated with the mentioned treatment, but sodium sulfonate was not applied in them.

Therefore, they were used as control group. After the restorative treatment, finishing and polishing were performed. A 2 ml vial of vitamin B complex and half of the vial of penicillin 6.3.3 solution (to prevent the post-treatment infection) were injected intramuscularly to each cat. One week after the treatment, five of the cats were killed, and after one month, the other five ones were killed as well using this method:

The combination of ketamine hydrochloride and acepromazine was used for the general anesthesia of the animal. Immediately after the anesthesia, IV line was prepared and formalin 10% was injected intravenously and the cat was killed and fixed. Then, the mouth of the animal was kept open and around the gingiva of each canine, a surgical flap was prepared. A special disc was used to separate the tooth and its surrounding bone. The teeth were kept in a special coded container containing formalin 10% for 14 days for complete fixation and then were put in nitric acid 10% solution for decalcification and they were evaluated daily. Then, each tooth was divided into two

parts. After the mentioned steps, paraffin blocks were made and 6 micrometer thick microscopic slides were prepared with proper intervals and dyed with hematoxylin and eosin. Microscopic slides were observed by a pathologist using light microscope BX41 Olympus (Tokyo, Japan). Scoring for inflammation was as follows:

Score 0: Absence of inflammatory cells, score 1: a few sporadic inflammatory cells, score 2: diffuse and severe inflammatory cells, score 3: presence of pulpal abscess or necrosis In evaluation of predentin, the grading was as follows:

Score 0: absence of predentin

Score 1: a very thin layer of predentin

Score 2: a thin layer of predentin

Score 3: a medium layer of predentin

Score 4: a thick layer of predentin

Score 5: a very thick layer of predentin

Data were analyzed by SPSS software version 17 and Mann-Whitney test. The level of significance was established at  $p < 0.05$ .

## Results

The results of the analysis regarding the diffusion of inflammatory cells in the right canines (control group) and left canines (case group) are presented in table 1 (figure 1). The data regarding the formation of predentin in case and control groups are shown in table 2 (figure 2).

According to table 1, the results of the comparative analysis using Mann-Whitney software between the control and case group revealed that the two groups did not show significant differences in inducing pulpal inflammation ( $p = 1.000$ ). In addition, the cats that were examined after one month showed similar results ( $p = 0.773$ ).

According to table 2, the results of the comparative analysis using Mann-Whitney software between the control and case groups, were evaluated after one week that showed statistically significant differences between the two groups regarding predentin formation in pulp. This formation was more in the case group than control group ( $p = 0.017$ ). However, the results were not similar after one month examination and no significant difference was observed between the two groups ( $p = 0.203$ ). Therefore, the results showed that the application of sodium sulfonate in restorative treatments along with composite is safe for pulp.

**Table 1. The comparison of pulpal inflammation between case group and control group after one week and one month**

Inflammation		Absence of inflammatory cells	a few sporadic inflammatory cells	Severe and diffused inflammatory cells	presence of pulpal abscess or necrosis
Time/Group (Number of cases)					
After one week*	Control	7	2	1	0
	Case	6	4	0	0
	Total	13	6	1	0
After one month**	control	4	1	5	0
	Case	3	4	3	0
	Total	7	5	8	0

\*p=1.000

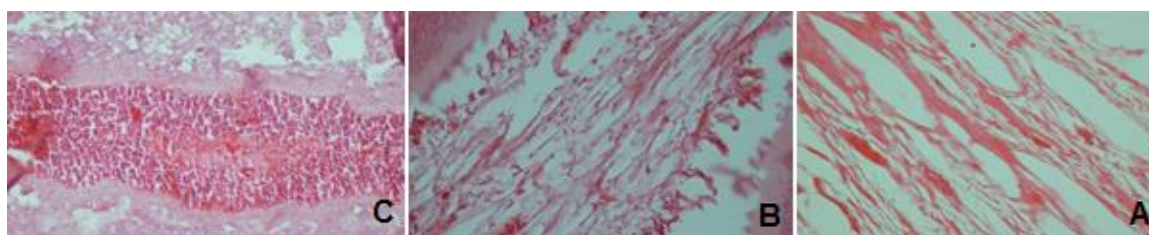
\*p=0.773

**Table 2. The comparison of predentin thickness between case and control groups after one week and one month**

Inflammation		Absence of predentin	a very thin layer of predentin	a thin layer of predentin	a medium layer of predentin	a thick layer of predentin	a very thick layer of predentin
Time/Group (Number of cases)							
After one week*	Control	5	3	0	2	0	0
	Case	1	2	2	1	4	0
	Total	6	5	2	3	4	0
After one month**	Control	1	1	1	4	2	1
	Case	1	2	4	2	1	0
	Total	2	3	5	6	3	1

\*p=0.017

\*\*p=0.203



**Figure 1. Absence of inflammation in pulp (A) mild and sporadic inflammation in pulp (B) severe inflammation in pulp (C) (H&E staining×40)**



**Figure 2. Absence of predentin (A) thin layer of predentin (B) thick layer of predentin (C) (H&E staining×40)**



## Discussion

In the present study, the effect of sodium sulfonate on the dental pulp of the cat was evaluated and it was concluded that there was no statistical difference regarding the severity of inflammation and predentin thickness between the teeth that were treated with sodium sulfonate after acid etching in the control group. Additionally, the results showed that the application of sodium sulfonate in restorative treatments is safe for pulp. Considering the fact that no *in vivo* study was done on dental pulp, the results of this study are not comparable to other studies.

Dentin bonding agents have been improved and the applicability of these agents has been recently increased. Up to date, these bonding agents are applied to increase the retention of composite restorations and to improve the marginal fit of gingival margins of dentinal cavities. The use of these agents can be effective in the loss of microleakage and increase in the restoration's retention to the tooth, but it cannot completely remove the microleakage (15).

In other words, microleakage is the most important factor that decreases the longevity of composite restorations. Many studies have been performed to decrease or eliminate the microleakage using different dentin agents, flowable and packable composites, light curing composites in layers, different smear layer treatments, and even the removal of hybrid layer with sodium hypochlorite.

It seems that one of the methods for the elimination of microleakage is the preparation of dentin surface with the application of cleaning-cavity agents and wetting agents to increase the absorption of dentin bonding agents. Perdigao et al. (16) showed that the application of HEMA 35% aquatic solution (Aquaprep, Bisco) for re-wetting the prepared dentin with phosphoric acid and use of wetting agents after the application of acid can improve the attachment of some of the dentin bonding agents.

However, Meiers et al. (17) stated that the effect of cleaning the cavity with chlorhexidine was related to the components and type of dentin bonding agent. In the present study, a common hybrid composite (Tetric ceram), which has undergone many studies, was used. Therefore, the results can be applied to a vast majority of composites with similar formulations. In addition, a single bottle 5th generation dentin bonding agent (Excite) was used in the study which contains 25% alcohol as its solvable agent and 70% monomer resin.

The larger proportion of resin leads to a shiny surface after the evaporation of ethanol. The presence of alcohol instead of acetone results in less sensitiveness to the moisture of dentin surface.

All the monomers in Exite possess OH group. Moreover, this bonding agent is hydrophilic and can properly penetrate into dentinal tubules and collagen network. This agent has finite fillers (12 nanometers) that not only enable the agent to penetrate into demineralized dentin and improve marginal fit, but they also do not increase the layer thickness which is crucially important in the cementation of indirect restorations (18). Due to the fact that microleakage is affected with chemical attraction of dentin bonding agents and composite resins, it is better to use any dentin bonding agent with the composite resin from the same manufacturer (19).

In 2004, the influence of application of acidic soaps in shear bond strength between the dentin bonding agent (Excite) and dentin experimentally was evaluated (13). The results showed significant differences in the strength of shear bond of composite to dentin between the two case groups. Furthermore, in another study, shear bond strength of dentin bonding agent (Excite) to dentin was stronger in the group treated with inert soap comparing to the group treated with basic soap and both of them had stronger bond strength in comparison with control group (no soap was used) (14).

In another study, the application of acidic, basic, and inert soaps on the microleakage of dentin bonding agent was evaluated. The results showed that the mean microleakage in the group treated with inert soap was significantly less than the groups treated with basic and acidic soaps and control group (12).

Other researchers (20) showed that using microscopic evaluation, the application of sodium sulfonate did not significantly affect the increase in hybrid layer thickness and resin tags.

According to the previous studies regarding the effect of acidic, basic, and inert soaps on the bond strength and microleakage of dentin bonding agents, it is concluded that inert soap (sodium sulfonate) was the most effective soap in increasing the bond strength and decreasing the microleakage. Therefore, in the present study, the application of sodium sulfonate in the restorative treatment of class V pulp cavities of the cat (biocompatibility with pulp) was studied. The results showed that sodium sulfonate did not only have a

negative effect on pulp throughout the restorative treatment with composite, but it also helped in the increase of predentin formation in the first week, which was statistically significant. According to these findings, there was no association between the use of sodium sulfonate and predentin thickness after one month.

## Acknowledgments

This project was a result of Dr. Behzad Amiri Andi's doctoral thesis and was funded by a (Grant No.184524589) from the Dental School of Babol University of Medical Sciences. The authors express their special thanks to the personnel of Dental Materials Research Center of Babol Dental Faculty for their generous support throughout this study.

**Conflict of interest:** There was no conflict of interest.

## References

1. Kanca J 3rd. The effect of heat on the surface hardness of light-activated composite resin. *Quintessence Int* 1989; 20: 899-901.
2. Maitland R. Successful class II posterior composite restorative using on internal fiber-optic wedge technique. *Esthetic Dent* 1991; 2:2-7.
3. Donly KJ, Wild TW, Bowen RL, Jensen ME. An invitro investigation of the effects of glass inserts on the effective composite resin polymerization shrinkage. *J Dent Res* 1989; 68:1234-7.
4. Serra MC, Cury JA. The invitro effect of glass-Ionomer cement Restoration on enamel subjected to a demineralization and remineralization model. *Quintessence Int* 1992; 23:143-7.
5. Summit JB, Robbins JW, Hihon TJ, Schwartz RS, editor. *Fundamentals of operative dentistry: A contemporary Approach*. 3<sup>rd</sup> ed. Chicago: Quintessence Publishing Co, Inc; 2006. p.178-239.
6. Power JM, Sakaguchi RL. *Craigs Restorative dental materials*. 12<sup>th</sup> ed. St.louis: Mosby Elsevier; 2006. p.214-340.
7. Robertson TM, Heymann HO, Swiff EJ, editor. *Sturdevan's Art and science of operative dentistry*. 4<sup>th</sup> ed. St Louis: Mosby Elsevier; 2006. p.237-58.
8. Huang FM, Tsai CH, Ding SJ, Chang YC. Induction of cyclooxygenase-2 expression in human pulp cells stimulated by dentin bonding agents. *Oral Surg Oral Med Oral Pathol Oral Radiol Endod* 2005; 100:501-6.
9. El-Housseiny AA, Jamjoum H. The effect of caries detector dyes and acavity cleansing agent on composite resin bonding to enamel and dentin. *J Clin Pediatr Dent* 2000; 25: 57-63.
10. Owens BM, Lim DY, Arheart KL. The effect of antimicrobial pre-treatments on the performance of resin composite restorations. *Oper Dent* 2003; 28:716-22.
11. Say EC, Koray F, Tarim B, Soyman M. Invitro effect of cavity disinfections on the bond strength of dentin bonding systems. *Quintessence Int* 2004; 35: 56-60.
12. Safarcharati H, Alaghehmand H, Hatami S. Effect of acidic, basic and neutral soaps on microleakage of dentin bonding agent. *J Babol Univ Med Sci* 2008; 10:50-5.
13. Naderi M: The laboratory examination of influence of acidic soap on the shear bond strength of a dentin bonding agents to dentin. Dental School of Babol University of Medical Sciences DDS Thesis. Babol Iran 2004 [In Persian]
14. Asghary N: The laboratory examination of influence of basic and neutral soaps on the shear bond strength of a dentin bonding agents to dentin. Dental School of Babol University of Medical Sciences DDS Thesis. Babol Iran 2004 [In Persian]
15. Hilton TH, Schwartz RS, Ferracane JL. Microleakage of four class II resin composite insertion techniques at intraoral temperature. *Quintessence Int* 1997; 28: 135-44.
16. Perdigao J, Van Meerbeek B, Lopes MM, Ambrose WW. The effect of a rewetting agent on dentin bonding. *Dent Mater* 1999; 15:282-95.
17. Meiers JC, Kresin JC. Cavity disinfectants and dentin bonding. *Oper Dent* 1996; 21: 153-9.
18. International Organization for Standardization. Dental materials-guidance on testing of adhesion to tooth structure. International standard, Volume 11405 of Technical report (International Organization for Standardization). The University of Michigan: International Organization for Standardization, 1994. p. 12-15.
19. Pradelle PN, Nechad S, Tavanier B, Colon P. Effect of dentin adhesive on the enamel- dentin/ composite interfacial Microleakage. *Am J Dent* 2001; 14: 344-8 (Abs).
20. Alaghehmand H, Safarcherati H, Farhadi M. Electronic microscopic evaluation of sodium sulfonate effect on hybrid layer and resin tags thickness. *J Babol Univ Med Sci* 2012;14:31-5.[In Persian]