Caspian Journal of Dental Research
e-ISSN: 2322-2395 p-ISSN: 2251-9890
Babol University Of Medical Sciences

Clinical and Radiographic Evaluation of the Efficacy of Chitosan-Containing Gel in the Treatment of Periodontal Intrabony Defects

Mariyeh Talebi [1], Sina Haghanifar [2], Sohrab Kazemi [3], Seyed Ali Seyedmajidi [4], Mohsen Shalalvand [1], Niloofar Janabian [5]*

1. Student Research Committee, Babol University of Medical Sciences, Babol, Iran.
2. Professor, Oral Health Research Center, Health Research Institute, Babol University of Medical Sciences, Babol, Iran.
3.Associate Professor, Department of Pharmacology, Health Research Institute, Babol University of Medical Sciences, Babol,Iran.
4. Dental Materials Research Center, Health Research Institute, Babol University of Medical Sciences, Iran.
5.Professor, Dental Materials Research Center, Health Research Institute, Babol University of Medical Sciences, Iran.

Article type
Research Paper

Received: 24 Sep 2025
Revised: 29 Oct 2025
Accepted: 11 Nov 2025
Pub. online: 22 Nov 2025

ABSTRACT

Introduction: Intrabony defects are a key indicator of periodontal disease progression, and complete tissue regeneration is the primary goal of periodontal treatments. The aim of this study was to assess the clinical and radiographic efficacy of chitosan-containing gel in treating periodontal intrabony defects.

Materials and Methods: This double-blind randomized clinical trial was conducted on 26 proximal sites with combined three-walled or two-walled intrabony defects in maxillary and mandibular molars of adult patients, referred to the periodontology patients were randomly divided into two groups. The first group received a chitosan-containing gel, while the control group received a chitosan-free gel during surgery. Clinical parameters -Probing Pocket Depth (PPD), Clinical Attachment Level (CAL), Gingival Recession (GR), and Gingival Index (GI) - were measured before and six months after surgery. Radiographic images were also analyzed before and after surgery using digital subtraction.

Results: In the group that receiving chitosan gel, there was a significantly greater reduction in PPD and CAL indices six months after surgery (P=0.001). The radiographic findings showed a statistically significant reduction in PPD and a significant improvement in CAL in the group receiving chitosan gel (P<0.001).

Conclusion: Based on the results, it is recommended to use chitosan gel as a supplementary material in bone defect surgeries.

Keywords: Bone regeneration, Guided tissue regeneration, periodontal diseases, Chitosan, Periodontal attachment loss, periodontal pocket

Cite this article: Talebi M, Haghanifar S, Kazemi S, Seyedmajidi S, Shalalvand M, Janabian N. Clinical and Radiographic Evaluation of the Efficacy of Chitosan-Containing Gel in the Treatment of Periodontal Intrabony Defects. Caspian J Dent Res 2025; 14: 1-11.

© The Author(s).
Publisher: Babol University of Medical Sciences

Introduction

Periodontitis is a prevalent, chronic inflammatory condition affecting the supporting structures of the teeth, primarily the gingiva, periodontal ligament, cementum, and alveolar

* **Corresponding Author:** Niloofar Janabian, Dental Materials Research Center, Health Research Institute, Babol University of Medical Sciences, Iran.
Tel: 01132291408
E-mail: niloofarjenabian@yahoo.com

[Downloaded from cjdr.ir on 2026-11-23]

bone arising from complex host–pathogen interactions that lead to progressive tissue and bone destruction.[1, 2]

A key clinical feature of advanced periodontitis is the formation of periodontal pockets and intrabony defects, defined by the vertical loss of supporting bone. The morphology and number of residual bony walls determine the regenerative potential**;** three-wall defects provide a better prognosis than one-wall defects. [3, 4]

The primary goal of periodontal therapy is to arrest disease progression, eliminate inflammation, and, when possible, restore lost periodontal tissues. While conventional periodontal treatment, including Scaling and Root Planing (SRP), aims to remove etiologic factors, surgical interventions are often necessary to provide access for thorough debridement and to address intrabony defects.[5, 6, 7] Various regenerative modalities have been explored to enhance the repair of periodontal tissues, including bone grafts, guided tissue regeneration (GTR) membranes, and bioactive molecules, which attempt to restore the lost attachment apparatus. [8] Despite advancements, achieving predictable and complete regeneration of periodontal tissues remains a challenge, necessitating the development of new biomaterials and therapeutic strategies.

The ideal regenerative material should possess several key characteristics: biocompatibility, biodegradability, osteoconductivity (promoting bone formation) osteogenesis (ability to form bone directly), osteoinductivity (ability to induce undifferentiated cells to differentiate into osteoblasts), and favorable handling, properties. Each currently used grafting option- autograft, allograft, xenograft, or synthetic alloplast- presents inherent drawbacks, including limited osteogenic potential, donor-site morbidity, and possible immunogenic or infectious risks. Among natural biomaterials, chitosan has gained increasing attention. [9]

Chitosan is a linear polysaccharide derived from the deacetylation of chitin, the second most abundant, natural biopolymer after cellulose, found in the exoskeletons of crustaceans and insects. Moreover, the cell walls of fungi have a molecular structure, characterized by a backbone of β-(1→4)-linked D-glucosamine and N-acetyl-D-glucosamine residues, which imparts a unique set of physicochemical properties that make it attractive for biomedical applications. Chitosan's biocompatibility and biodegradability are well-established. It is metabolized by lysozyme in vivo into non-toxic, readily excretable components. [10-15]

Its cationic amino groups enable electrostatic interactions with negatively charged surfaces, guiding cell adhesion, proliferation, and differentiation**.** It also exhibits natural antimicrobial activity, particularly against Gram-positive species relevant to periodontal pathogens.[16] In addition, its hemostatic properties help control bleeding during surgical procedures, and its ability to form gels and films makes it amenable to various delivery systems.[12, 13, 17] The biodegradability and biocompatibility of chitosan make it an ideal biomaterial and scaffold for hard tissue regeneration. Through its chemically hydrogen-bonded chains, cross-linking capability, and positively charged amino groups (NH_2^+) that interact with negatively charged tissues in the human body, chitosan provides structural stability that facilitates the initiation of new bone cell formation during the early stages of bone repair. [18]

Preclinical data confirm its osteoconductive and osteopromotive roles, supporting bone cell attachment, proliferation, and osteoblast differentiation.[6] Chitosan-based systems- developed as powders, membranes, sponges, and gels- have shown consistent benefits in periodontal

[Downloaded from cjdr.ir on 2026-11-23]

regeneration studies. The gel form is particularly advantageous for its adaptability to irregular defects, direct surgical application, and ability to release active components gradually.[1, 19]

Accordingly, the present study evaluates the clinical and radiographic efficacy of a chitosan-containing gel as an adjunct to surgical treatment of intrabony periodontal defects. Outcomes are compared with a placebo gel to isolate the specific regenerative contribution of chitosan. Therefore, the research hypothesis is that chitosan gel enhances probing pocket depth (PPD) reduction, clinical attachment level (CAL) gain, gingival recession (GR) stability, GI improvement, and radiographic bone density (DSR) outcomes**,** providing an evidence-based rationale for integrating chitosan hydrogels into periodontal regenerative therapy.

Materials & Methods

This research was a double-blind, randomized, controlled clinical trial study was approved by Babol University of Medical Sciences, Iran with the code of IR.MUBABOL.HRI.REC.1403.080 and registered in the Iranian Registry of Clinical Trials (IRCT) (code: IRCT20250524065870N1). All participants provided informed consent after receiving a thorough explanation of the study procedures, potential risks, and benefits.

The minimum sample size for each group was determined based on the results of similar studies (chitosan effect on CAL and bone), (20) with a study precision of 95% (α=0.05) and a statistical power of 80% (β=0.2). Based on the following formula, 13 periodontal intrabony defects were determined for each group.

$$n \geq \frac{\left(\left(z_1 - \frac{\alpha}{2}\right) + (z_1 - \beta)\right)^2 (\sigma_1{}^2 + \sigma_2{}^2)}{(\mu_{1-} \mu_2)^2} = \frac{(2.58 + 1.65)^2 (0.92^2 + 1.45^2)}{(9.64 - 7.13)^2} = 8.38 \sim 9$$

A total of 8 patients (26 sites) (mean age 46.23 ± 8.86 years) with at least one periodontal intrabony defect were recruited.

Inclusion criteria:

- Age 20–65 years.
- Interdental intrabony defect with PD ≥ 5 mm and radiographic bone loss ≥ 3 mm
- Plaque index < 20%.
- Radiographic confirmation of two-wall or three-wall intrabony defects.
- Good systemic health and adherence to follow-up visits.

Exclusion criteria:

- Periodontal surgery in the past 6 months or antibiotic use < 3 months
- Smoking, pregnancy, or lactation
- Systemic disease affecting bone metabolism
- Tooth mobility > Grade II, endodontic involvement, or root caries
- Missing adjacent teeth

[Downloaded from cjdr.ir on 2026-11-23]

Randomization and Blinding:

Periodontal intrabony defect samples were randomized using the Kitset.ir random number generator, assigning defects equally to:

- Group A: Chitosan-containing gel
- Group B: Placebo gel

Allocation concealment was maintained using sealed opaque envelopes. Both clinicians and patients were blinded to treatment assignment throughout the study.

Preparation of Chitosan Gel

Chitosan gel was prepared using a 1% (w/v) chitosan solution. High-purity chitosan with a deacetylation degree of approximately 80% and a molecular weight of about 100,000-300,000 Da was used. The chitosan was dissolved in a 0.5% acetic acid solution to obtain a homogeneous 1% (w/v) solution. The solution was sterilized by autoclaving. Because preservatives are present in the gel, its expiration period is approximately two years, and it should preferably be stored in a refrigerator. For the control group, a placebo gel was prepared using the same base without chitosan. [21]

Surgical Procedure

All surgical procedures were performed by the same experienced periodontist under local anesthesia (2% lidocaine with 1:100,000 epinephrine). A standard mucoperiosteal flap was elevated to provide full access to the intrabony defect. Thorough debridement of the defect was performed, including removal of all granulation tissue and meticulous SRP to create a smooth root surface. The root surfaces within the defect were treated with an EDTA solution (Pref Gel, Straumann, Basel, Switzerland) for 2 minutes to demineralize the root surface and promote cell adhesion, followed by copious irrigation with sterile saline (Figure 1).

In Group A, 1% chitosan gel was applied to fill the defect. In Group B, placebo gel (chitosan-free gel) was used. After gel application, the mucoperiosteal flap was repositioned to cover the defect and stabilized with sutures (e.g., 5-0 silk sutures) in a coronal position to achieve primary closure. Postoperative instructions, patients were instructed to avoid brushing the surgical site for the first 24 hours and to use a 0.12% chlorhexidine mouthwash. Sutures were removed 7-10 days postoperatively.

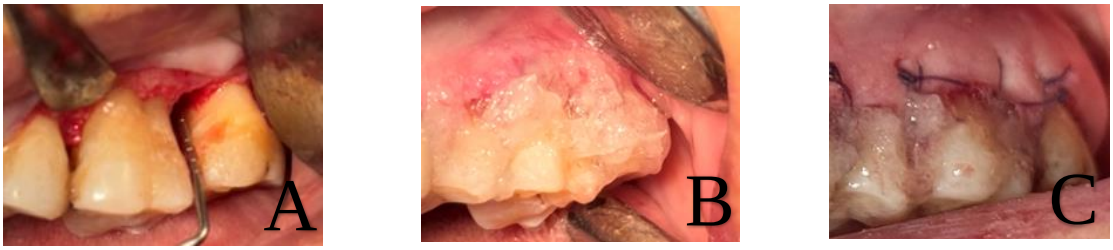

Figure 1. Photographs of surgical procedures: A) Intrasulcular incision, reflection of a mucoperiosteal flap, removal of granulation tissue, thorough scaling and root planing (SRP), and irrigation, B) Injection of the gel in an overfill manner, and C) Suturing using the sling technique.

[Downloaded from cjdr.ir on 2026-11-23]

Study Parameters:

Clinical Parameters

The following clinical parameters were assessed at baseline and at 6 months post-operatively by a calibrated independent examiner who was blinded to the treatment allocation:

- Probing Pocket Depth (PPD): The distance from the gingival margin to the deepest point of the gingival sulcus or periodontal pocket, measured with a calibrated periodontal probe (e.g., UNC-15 or William's probe) to the nearest millimeter.
- Clinical Attachment Level (CAL): The distance from a fixed reference point on the tooth (e.g., the Cemento Enamel Junction, CEJ) to the base of the pocket. In cases where the CEJ was exposed due to gingival recession, the CAL was measured from the CEJ to the bottom of the pocket.
- Gingival Recession (GR): The distance from the CEJ to the gingival margin. Recession was measured only when the gingival margin was apical to the CEJ.
- Gingival Index (GI): Assessed using the criteria described by Löe and Silness (1963), scoring gingival inflammation on a scale of 0 to 3.
- Subtraction Radiography (RDD): Assessment of pre- and post-operative radiographic density differences.

Radiographic Assessment

Baseline periapical radiographs (pre-operative) were obtained using a film holder (Rinn XCP, Kavo Kerr, China) and a size-2 digital PSP sensor (Soredex, Helsinki, Finland). To record the patient's occlusion for reproducible positioning, impression material (Duralay, Reliance, Illinois, USA) was applied to the bite block area of the film holder. Images were scanned and processed using Cliniview software version 10.2.6 (Soredex, Tuusula, Finland) and stored for future comparison.

At the follow-up, identical exposure parameters and the same bite block were used. Digital subtraction of the baseline and post-treatment images was performed using Photoshop CS6 software (Adobe Systems, California, USA). Areas showing reduced radiographic density (radiolucency) were considered negative changes; areas showing increased density (radiopacity) were considered positive changes; and areas with no observable difference in density were classified as unchanged (Figure2).

The blinded examiner performed all radiographic assessment.



Figure 2. Radiographic evaluation before and after the procedure. A) Pre-operative, B) Post-operative, C) Subtraction radiography

[Downloaded from cjdr.ir on 2026-11-23]

Statistical Analysis

Prior to the main analysis, the normality of the data distribution was assessed using the Shapiro-Wilk test. Non-parametric tests were used for all subsequent comparisons since the data followed no normal distribution. The data were statically analyzed using SPSS 26 (IBM, New York, USA)**.** Descriptive statistics were presented in tables and charts. To compare quantitative variables within each group before surgery and 6 months after surgery, the Wilcoxon signed-rank test was used. The Mann-Whitney U test was applied to compare the magnitude of changes over the 6-month period between the two groups. Changes in qualitative variables over time and between the two groups were assessed using the McNemar test, Chi-square test, and Fisher's exact test. A Value of P<0.05 was statistically considered significant.

Results

A total of 26 periodontal intrabony defects were treated (n=13 per group).

Chitosan-free gel group

The results indicated that both PPD and CAL demonstrated statistically significant reductions following surgery (p= 0.001). For both variables, substantial improvement was confirmed in periodontal health. The Gingival Index (GI) decreased from a preoperative mean of 1.69 ± 0.48 to a postoperative mean of 0.92 ± 0.28 ($P = 0.002$), demonstrating reduced gingival inflammation. Gingival recession (GR) exhibited no change between baseline and the 6-month follow-up.

Chitosan-containing gel group comparisons:

At six months, the chitosan-containing gel group demonstrated marked improvements across all parameters. Mean reduction in PPD was $= 2.15 \pm 0.69$ mm and CAL $= 2.31 \pm 0.75$ mm, both significant ($P = 0.001$). GI decreased from 1.69 ± 0.52 to 0.92 ± 0.48 ($P = 0.001$), indicating enhanced gingival health (Table 1). Intergroup analysis demonstrated statistically significant differences in mean reduction of PPD ($P = 0.006$) and CAL ($P = 0.009$).

Table 1. Intra-group Changes in Clinical Parameters (Baseline vs. 6 Months)

Group	Parameter	Baseline (Mean ± SD)	6 Months (Mean ± SD)	Mean Change ± SD	P-value	95% CI for Change	Effect Size (r)
Non-Chitosan Gel Group	PPD (mm)	5.08 ± 0.64	4.08 ± 0.95	1.00 ± 1.08	0.012	0.347 to 1.652	0.696
	CAL (mm)	5.00 ± 0.82	4.00 ± 1.35	1.00 ± 1.29	0.022	0.219 to 1.780	0.635
	GI	1.69 ± 0.48	0.92 ± 0.28	0.77 ± 0.44	0.002	0.504 to 1.03	0.877
Chitosan Gel Group	PPD (mm)	4.92 ± 0.76	2.77 ± 0.93	2.15 ± 0.69	0.001	1.74 to 2.57	0.901
	CAL (mm)	4.77 ± 1.01	2.46 ± 1.27	2.31 ± 0.75	0.001	1.85 to 2.76	0.898
	GI	1.46 ± 0.52	0.31 ± 0.48	1.15 ± 0.55	0.002	0.81 to 1.48	0.892

[Downloaded from cjdr.ir on 2026-11-23]

Comparison of pre- and post-operative gingival recession distribution in two groups showed no statistically significant difference in gingival recession changes after surgery (McNemar test, p = 1.000). One improvement case (positive to negative) was observed in the chitosan gel group, but it was not statistically significant. The results indicate that chitosan gel did not increase the occurrence of gingival recession, confirming its safety for marginal soft tissue stability (Table 2).

Table 2. Comparison of Gingival Recession immediately before and 6 months after surgery in the studied groups

		6 Months After Surgery					
		Non-Chitosan Gel Group			Chitosan Gel Group		
		Negative	Positive	P-value*	Negative	Positive	P-value*
Immediately Before Surgery	Negative	10	0		9	0	
	Positive	0	3	1.000	1	3	1.000
	Total	10	3		10	3	

Figure 3, illustrates the changes in gingival recession between the two treatment groups. Analysis using Fisher's exact test found no new cases of gingival recession postoperatively in either group, and only one instance of recession improvement in the chitosan-containing gel group. The overall P-value for this comparison was 1.000, indicating no statistically significant difference in gingival recession changes between the groups.

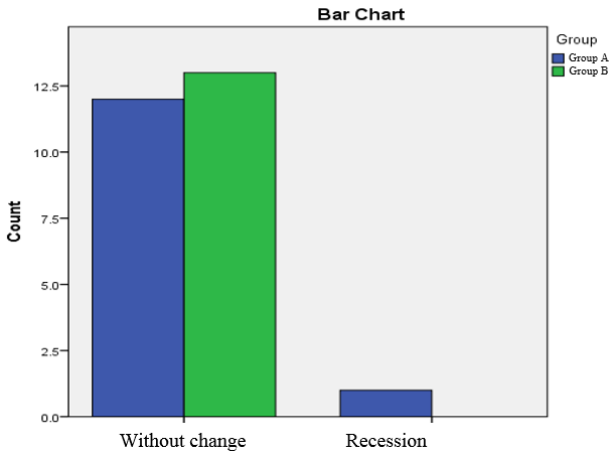

Figure 3: Comparison of changes in Gingival Recession status after 6 months of surgery between two groups

Radiographic evaluation using subtraction analysis to assess changes in bone levels between the two groups at the 6-month follow-up yielded significant findings. The chitosan-containing gel group exhibited a markedly higher rate of bone fill (positive change) and a substantially lower rate of bone loss (negative change) compared to the chitosan-free gel group. Specifically, 84.6% of sites in the chitosan group showed no significant change, indicating stability or improvement, while only 30.8% of sites in the chitosan-free group demonstrated no change,

[Downloaded from cjdr.ir on 2026-11-23]

with 69.2% exhibiting bone loss (negative change). The chi-square test confirmed that these differences in radiographic outcomes were statistically significant (P = 0.005). This suggests that the chitosan-containing gel significantly promoted bone regeneration or at least preserved existing bone more effectively than the chitosan-free gel.

Discussion

The findings of the present study indicated that adjunctive use of chitosan gel led to statistically significant improvements in PPD reduction and CAL gain compared to control procedures alone, consistent with results from similar regenerative studies, such as the following:

In the trial by Al-Agooz et al., a chitosan–melatonin nanoparticle formulation achieved a mean PPD reduction of 3.12 ± 0.66 mm and CAL gain of 2.94 ± 0.58 mm after 6 months, outperforming a placebo gel. These results were statistically significant and align closely with the present study. [22] Similarly, Eshwar et al. found that a fucoidan–chitosan composite hydrogel achieved significantly greater CAL gain and defect fill compared to **concentrated** growth factor, highlighting that chitosan combined with bioactive polysaccharides can surpass growth factor–based regenerative materials previously considered the gold standard. [20]

Previous studies have evaluated natural-origin chitosan gel as a carrier for drugs or as an osteogenic agent. Tissue regeneration is only possible when viable cells are present around the lesion to respond to signaling molecules such as growth factors. Some reports have used chitosan combined with autografts or other grafting materials to transfer viable osteogenic cells to defect sites. In this study, since the surrounding viable tissues already contained the growth factors needed to induce bone formation, no grafting material was used with chitosan. However, the limited concentration of these factors may explain the absence of extensive radiographic bone regeneration. Its scaffold structure, though, might have prevented further bone loss. [8, 17, 18, 23]

In another study by Madieh on mandibular molar furcation involvement, significant reductions in vertical probing depth, vertical CAL, horizontal probing depth, and GI, as well as decreased GR and evidence of bone formation in subtraction radiography, were reported for the chitosan gel group. [24] These findings were similar to the clinical results of the present study though they differ radiographically, possibly due to site-specific surgical differences. Sankari and Meenakshi showed that chitosan nanohydrogel significantly reduced CAL and PPD compared to controls [1], consistent with our data. Harikumar et al. represented enhanced PD reduction using GTR with collagen–chitosan film. [5] In contrast, Faghani et al. found no significant CAL difference between chitosan particle and control groups, likely due to differences in delivery form- gel in the current study versus high- or low-molecular-weight particles in theirs. [6] Ardakani et al. indicated that chitosan application in post-extraction sockets significantly increased bone density compared to controls, possibly due to higher local levels of growth factors. [25]

For GI, both groups showed reduced gingival inflammation, with greater improvement in the chitosan group, potentially due to chitosan's anti-inflammatory and antibacterial properties. [13, 14]

[Downloaded from cjdr.ir on 2026-11-23]

A key strength of this study was its double-blind design, with both groups receiving gels that differed only in chitosan content, minimizing bias. Clinically, chitosan gel shows promise as a periodontal therapeutic, particularly in hydrogel form, to reduce inflammation, promote tissue healing, and prevent bone loss.

Nevertheless, certain limitations of this trial must be acknowledged. The small sample size, relatively short 6-month follow-up and reliance on radiographic measures may restrict the generalizability of the results. Radiographic assessment was limited to linear measurements; incorporating cone-beam computed tomography (CBCT) or histological evaluation in future studies would provide greater mechanistic insight.

Despite these limitations, consistent improvements in both clinical and radiographic parameters suggest that chitosan gel has potential as a safe and biocompatible regenerative adjunct. The observed safety profile, marked by minimal postoperative sensitivity or adverse reactions, further supports its clinical viability.

Conclusion

Within the limitations of this randomized clinical trial, adjunctive use of chitosan-containing gel in the surgical management of intrabony periodontal defects resulted in significantly greater improvements in PPD, CAL, and gingival health compared with the control group. Radiographic assessments demonstrated reduced bone loss and signs of regeneration at sites treated with chitosan. Collectively, these findings support the potential of chitosan gel as a valuable adjunctive biomaterial in periodontal regenerative surgery. Further, multicenter clinical trials with larger populations and long-term evaluations are recommended to substantiate these results.

However, the current study was limited by a small sample size, a relatively short six-month follow-up period, and the absence of histological confirmation of bone regeneration.

Acknowledgments

The authors would like to thank all the dental students, faculty members and staff of Babol Dental School who helped us in conducting this study.

Conflict of Interest

There is no conflict of interest to declare.

Author's Contribution

Marieh Talebi performed all surgical procedures on the patients and injected gel into the area according to the invention protocol. Sina Haghanifar and Mohsen Shalalvand implemented the complete radiographic imaging protocol. Sohrab Kazemi designed and prepared the chitosan gel used in the study. Seyed Ali Seyedmajid performed statistical analysis of the data. Niloofar Jenabian served as principal supervisor and corresponding author.

[Downloaded from cjdr.ir on 2026-11-23]

References

1. Meenakshi SS, Sankari M. Effectiveness of chitosan nanohydrogel as a bone regenerative material in intrabony defects in patients with chronic periodontitis: a randomized clinical trial. Journal of advanced oral research. 2021;12(2):222-8.
2. Kwon T, Lamster IB, Levin L. Current concepts in the management of periodontitis. International dental journal. 2021;71(6):462-76.
3. Carranza FA, Newman MG, Takei HH, Klokkevold PR. Newman and carranza's clinical periodontology. (No Title). 2019.
4. Goldman HM, Cohen DW. The infrabony pocket: classification and treatment. The Journal of Periodontology. 1958;29(4):272-91.
5. Harikumar K, Nandakumar K, Devadas C, Mathew S. Collagen-chitosan barrier membrane, a novel indigenous and economic material for management of periodontal infrabony defects-a case-control studyl. 2015.
6. Faghani M, Jenabian N, Haghanifar S, Khafri S. Clinical and Radiographic Evaluation of Chitosan Particles in Treatment of Intrabony Periodontal Defects: A Clinical Trial. Frontiers in Dentistry. 2021;18:23.
7. Thrombelli L. Which reconstructive procedures are effective for treating the periodontal intraosseous defects. Periodontol 2000. 2005;37:88-105.
8. Zhang K, Zhao M, Cai L, Wang Z-k, Sun Y-f, Hu Q-l. Preparation of chitosan/hydroxyapatite guided membrane used for periodontal tissue regeneration. Chinese Journal of Polymer Science. 2010;28(4):555-61.
9. Giannoudis PV, Dinopoulos H, Tsiridis E. Bone substitutes: an update. Injury. 2005;36(3):S20-S7.
10. Norowski Jr PA, Bumgardner JD. Biomaterial and antibiotic strategies for peri-implantitis: A review. Journal of Biomedical Materials Research Part B: Applied Biomaterials: An Official Journal of The Society for Biomaterials, The Japanese Society for Biomaterials, and The Australian Society for Biomaterials and the Korean Society for Biomaterials. 2009;88(2):530-43.
11. Ji QX, Lü R, Zhang WQ, Deng J, Chen XG. In vitro evaluation of the biomedical properties of chitosan and quaternized chitosan for dental applications. Carbohydrate research. 2009;344(11):1297-302.
12. Aranaz I, Mengíbar M, Harris R, Paños I, Miralles B, Acosta N, et al. Functional characterization of chitin and chitosan. Current chemical biology. 2009;3(2):203-30.
13. Narvaez-Flores JJ, Vilar-Pineda G, Acosta-Torres LS, Garcia-Contreras R. Cytotoxic and anti-inflammatory effects of chitosan and hemostatic gelatin in oral cell culture. Acta Odontoloógica Latinoamericana. 2021;34(2):98.
14. Mhaske SP, Ambiti R, Jagga U, Paul U, Shanmukappa SM, Iska D. Clinicomicrobiological Evaluation of 2% Chitosan Mouthwashes on Dental Plaque. J Contemp Dent Pract. 2018;19(1):94-7.
15. Islam S, Bhuiyan MR, Islam M. Chitin and chitosan: structure, properties and applications in biomedical engineering. Journal of Polymers and the Environment. 2017;25(3):854-66.
16. De Carvalho M, Stamford TCM, Dos Santos E, Tenorio P, Sampaio F. Chitosan as an oral antimicrobial agent. Formatex. 2011;2012(1):13.
17. Okamoto Y, Yano R, Miyatake K, Tomohiro I, Shigemasa Y, Minami S. Effects of chitin and chitosan on blood coagulation. Carbohydrate Polymers. 2003;53(3):337-42.
18. Thangavelu A, Stelin KS, Vannala V, Mahabob N, Hayyan FMB, Sundaram R. An overview of chitosan and its role in periodontics. Journal of Pharmacy and Bioallied Sciences. 2021;13(Suppl 1):S15-S8.
19. Tanikonda R, Ravi RK, Kantheti S, Divella S. Chitosan: Applications in Dentistry. Trends in Biomaterials & Artificial Organs. 2014;28(2).
20. Eshwar S, Konuganti K, Manvi S, Bharadwaj AN, Sajjan S, Boregowda SS, et al. Evaluation of osteogenic potential of fucoidan containing chitosan hydrogel in the treatment of periodontal intra-bony defects—a randomized clinical trial. Gels (Basel, Switzerland). 2023;9(7):573.
21. Boynueğri D, Özcan G, Şenel S, Uç D, Uraz A, Öğüş E, et al. Clinical and radiographic evaluations of chitosan gel in periodontal intraosseous defects: a pilot study. Journal of biomedical materials research Part B: Applied Biomaterials. 2009;90(1):461-6.

[Downloaded from cjdr.ir on 2026-11-23]

22. Al-Agooz A, Ata F, Saleh W, Elmeadawy S. Clinical and radiographic evaluation of melatonin and chitosan loaded nanoparticles in the treatment of periodontal intra-bony defects: A Randomized controlled clinical trial. Clinical oral investigations. 2025;29(5):280.
23. Rabea EI, Badawy ME-T, Stevens CV, Smagghe G, Steurbaut W. Chitosan as antimicrobial agent: applications and mode of action. Biomacromolecules. 2003;4(6):1457-65.
24. Madieh P. Clinical and Radiographic Outcomes of Chitosan Gel in the Management of Grade II Furcation Defects A Clinical Trial. MSc thesis [in Persian], School of Dentistry, (2024); Babol University of Medical Sciences.
25. Ezoddini-Ardakani F, Azam AN, Yassaei S, Fatehi F, Rouhi G. Effects of chitosan on dental bone repair. Health. 2011;3(4):200-5.

[Downloaded from cjdr.ir on 2026-11-23]