

## Peripheral calcifying odontogenic cyst presenting clinically as an eruption cyst: A case report

Maryam Seyedmajidi <sup>1✉</sup>, Tahereh Momeni <sup>2✉</sup>, Fatima Bijani <sup>3\*</sup>

1. Professor, Dental Materials Research Center, Health Research Institute, Babol University of Medical Sciences, Babol, Iran.
2. Postgraduate Student, Student Research Committee, Department of Oral Medicine, Babol University of Medical Sciences, Babol, Iran.
3. Assistant Professor, Oral Health Research Center, Health Research Institute, Babol University of Medical Sciences, Babol, Iran.

### Article type

Case Report

### ABSTRACT

Calcifying odontogenic cyst (COC) is an odontogenic cyst with accumulation of ghost cells that has central and peripheral subsets. Here, we present an 11-year-old male patient with an intraoral swelling on the left posterior mandibular ridge interfering with eruption of the second molar. Histopathologic examination revealed a cystic lesion lined by ameloblast-like epithelium in the basal layer and accumulating ghost cells in the upper layers. The final diagnosis was peripheral COC, and there was no recurrence after 6 months. This case has shown that histologic examination is required for every simple case.

Received: 20 Jan 2023

Revised: 4 Mar 2023

Accepted: 5 Apr 2023

Pub. online: 14 Jun 2023

**Keywords:** Odontogenic Cyst, Cysts, Mandible

**Cite this article:** Seyedmajidi M, Momeni T, Bijani F. Peripheral calcifying odontogenic cyst presenting clinically as an eruption cyst: A case report. *Caspian J Dent Res* 2023; 12:95-8.



© The Author(s).

Publisher: Babol University of Medical Sciences

### Introduction

Ghost cell tumors are a group of lesions that present variously from a cyst to solid neoplasms and show a variety of clinical behavior from benign to locally aggressive or metastatic.<sup>[1]</sup> Calcifying odontogenic cyst (COC) is an odontogenic cyst lined by an ameloblast-like epithelium and containing a focal collection of ghost cells.<sup>[2]</sup> In addition, calcification is present in all ghost cell lesion.<sup>[1]</sup> In the most recent WHO classification, COC is also referred to as calcifying odontogenic ghost cell cyst and Gorlin cyst.<sup>[2]</sup>

COC is a rare developmental lesion affecting mainly the anterior maxillary segments.<sup>[3]</sup> It accounts for less than 1% of all odontogenic cysts and tumors.<sup>[4]</sup> Most of them are intraosseous with well-defined unilocular radiolucency, and foci of calcification in the periphery.<sup>[3]</sup> Extrasosseous COCs are also common in the anterior region<sup>[2]</sup> and occur almost exclusively in tooth-bearing areas.<sup>[5]</sup> Peripheral

\* **Corresponding Author:** Fatima Bijani, Department of Oral & Maxillofacial Pathology, Faculty of Dentistry, Babol University of Medical Sciences, Babol, Iran.

**Tel:** +981132291408

**E-mail:** fatimahb56@gmail.com

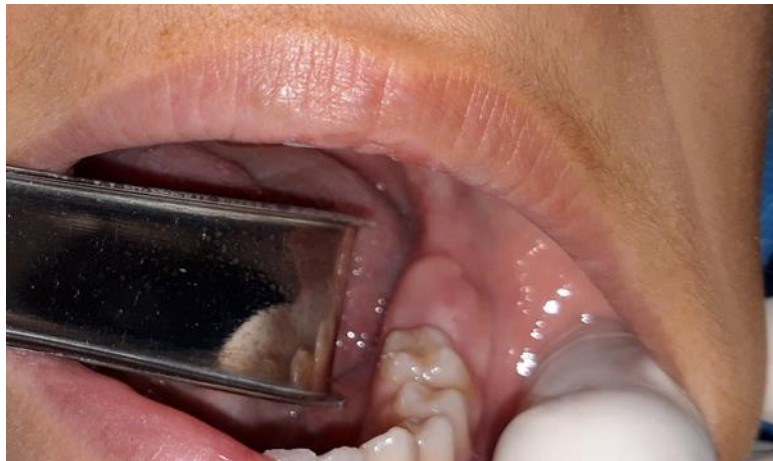lesions are less common, accounting for less than 3% of all cases.<sup>[5]</sup> These cysts are also less aggressive.<sup>[1]</sup>

The clinical finding is gingival swelling often with erosion of the underlying bone <sup>[1]</sup> and sometimes pain and tenderness.<sup>[2]</sup> Peripheral COC has the same histopathologic features as its central counterpart.<sup>[5]</sup>

This case report describes a case of peripheral calcifying odontogenic cyst in an 11-year-old male patient, which was discovered in the posterior part of his mandible. This project was approved by the Ethics Committee of Babol University of Medical Sciences (ethical code: IR.MUBABOL.REC.1402.002).

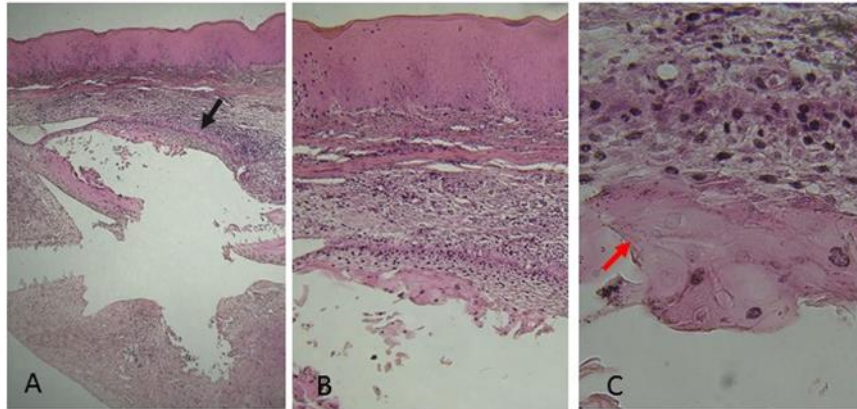
## Case Report

An 11-year-old male patient was referred to the dental clinic at Babol University of Medical Sciences in December 2018. The chief complaint was a swelling on his left posterior mandibular ridge for 6 months that interfered with his chewing. There was no history of pain or paresthesias. Intraoral examination revealed a swelling in the region of the unerupted left mandibular second molar that interfered with its eruption. The lesion had a smooth surface with normal color, and there was no erythema or ulceration (fig.1).



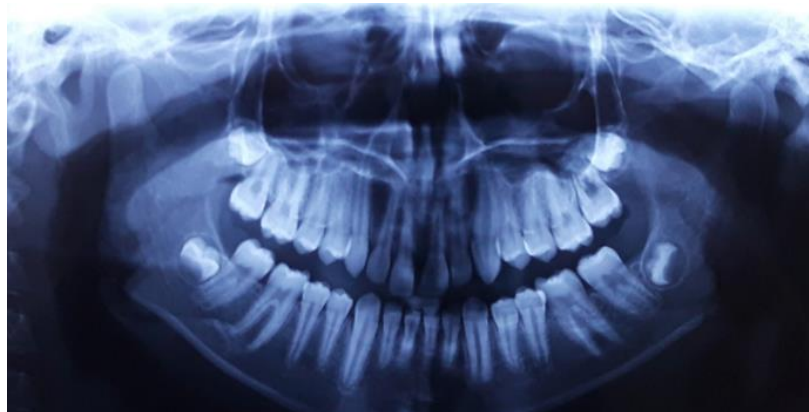
**Figure 1. Intraoral view indicating a cystic lesion located on the region of the left second mandibular molar**

No radiographic change was detected in the periapical view. The primary diagnosis was an eruption cyst, and after the patient's parents consented, a cyst excision was performed to accelerate tooth eruption. The cyst was completely enucleated and the total size of the lesion was approximately 1x0.7x0.5 cm. The removed tissue was placed in formalin and sent to the laboratory for histopathologic examination. After processing and preparation of microscopic slides, histopathological examination revealed a cystic lesion lined by odontogenic epithelium with a cuboidal basal layer arranged in a palisade pattern. The upper epithelial layers were loosely connected and acted like a stellate reticulum. Many eosinophilic ghost cells were noted in the epithelial layers. Calcification was also present in some areas of the cyst lining. Long strands of inactive odontogenic epithelium in addition to sheets of ghost cells, chronic inflammatory infiltration and foreign body giant cells were present in fibrous cyst wall. The lesion was lined with parakeratotic stratified squamous epithelium on the surface (fig.2).

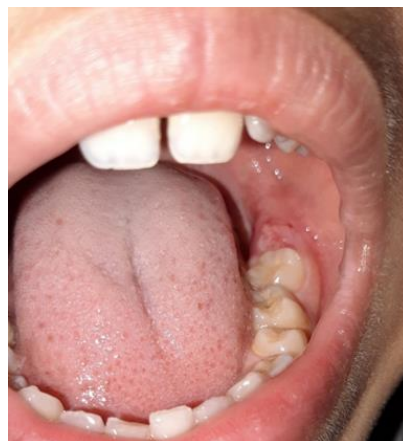

**Figure 2. (A) Histopathologic examination indicating a cystic lesion lined by cuboidal odontogenic epithelium with reversed polarity (black arrow) and eosinophilic ghost cells in the upper epithelial layers. Calcification was also present in some areas of the cyst lining (H&E stain x40), (B) At higher magnification representing a cuboidal basal layer and stellate reticulum-like pattern in the upper layers (H&E stain x100), (C) Eosinophilic ghost cells (red arrow) (H&E stain x400).**

Based on all these findings, the final diagnosis was confirmed as a “peripheral calcifying odontogenic cyst”. After six months of follow-up, no complications or recurrences were detected, and the second permanent molar erupted without problems (fig. 3-4).



**Figure 3. Panoramic view after 6 months**



**Figure 4. Intraoral view after 6 months indicating full eruption of the second molar**

## Discussion

Extrasosseous COC is a rare odontogenic cyst and few related studies are found in the literature. The mean age of involvement was reported as 41.8 years.<sup>[5]</sup> In the study by Resende et al., the most common location was the gingiva, but 18.2% of all cases involved the posterior part of the mandible, as in our patient. They also reported in their study that 29% of peripheral COCs had no radiographic changes, similar to this patient. However, some other cases had calcifications or erosions in the adjacent bone.<sup>[6]</sup> As in the present case, about 30% of the cases complained of painless swelling and 4.5% had tooth eruption disorder.

The histopathological feature of the current case was unicystic, as in most of the other cases discussed, and giant cell formation occurred, similar to the previously reported case<sup>[4]</sup>, except that no recurrence occurred, as in 25% of the other patients.<sup>[6]</sup> As mentioned earlier, peripheral COC has the same microscopic features as the intraosseous cases, but some authors believe that despite the same histologic findings, the causes may be different. It seems that extrasosseous COCs arise from epithelial remnants of Serrez.<sup>[4]</sup>

Enucleation is the treatment of choice for most COCs, especially for cases with small size, and the recurrence rate has been reported to be less than 5%.<sup>[2, 3]</sup> Although recurrence after surgical excision is rare,<sup>[4]</sup> patient follow-up is required. In this case, there were no signs of recurrence after 6 months, and the corresponding tooth erupted normally.

As it is mentioned in most texts, all biopsy tissues must be evaluated histologically.<sup>[7]</sup> Some lesions may appear clinically nonspecific, but on microscopic examination there are some important findings that can help the clinician treat the patient more accurately.

## Author's Contribution

Bijani F. performed the data collection, microscopic examination, literature search, drafting and editing of the manuscript, Seyedmajidi M. performed the data collection, drafting and editing of the manuscript and supervised the study. Momeni T. performed the data collection, examination and surgery of the patients, writing the manuscript and editing.

## References

1. Sheikh J, Cohen MD, Ramer N, Payami A. Ghost Cell Tumors. *J Oral Maxillofac Surg* 2017; 75:750-8.
2. El-Nagar AK, Chan JKC, Granadis JR, Takaya T, Slootweg PJ, editors. WHO classification of head and neck tumors. 4<sup>th</sup> ed. International agency for research on cancer, Lyon; 2017. p.239-41.
3. Oliveira EM, Santana LADM, Silva ER, Souza LN. A Calcifying Odontogenic Cyst Associated with Compound Odontoma Mimicking a Tooth Germ. *Case Rep Dent* 2021; 2021:9991772.
4. Hsu HJ, Chen YK, Wang WC, Tseng CH. Peripheral calcifying odontogenic cyst with multinucleated giant cell formation. *J Dent Sci* 2019; 14:211-2.
5. Costa LC, Neto JB, de-Assis EM, Gomes HE, Leitão TJ, Vasconcelos RR, et al. Peripheral Calcifying Odontogenic Cyst: A rare case report. *J Clin Exp Dent* 2018; 10:e1140-e4.
6. Resende RG, Brito JA, Souza LN, Gomez RS, Mesquita RA. Peripheral calcifying odontogenic cyst: a case report and review of the literature. *Head Neck Pathol* 2011; 5:76-80.
7. de Lima AP, Kitakawa D, Almeida JD, Brandão AA, Anbinder AL. Peripheral calcifying cystic odontogenic tumour of the maxillary gingiva. *BMC Res Notes*. 2012;5:455.