

Peripheral ameloblastoma: a case report and literature review

Pegah Mosannen Mozafari^{1✉}, Nooshin Mohtasham^{2✉}, Mehrzad Khorshid^{3*},
Mostafa Alizadeh Abkooh^{4✉}, Shohreh Taherimoghadam^{5✉}

1. Associate Professor, Oral & Maxillofacial Diseases Research Center, Faculty of Dentistry, Mashhad University of Medical Sciences, Mashhad, Iran.
2. Professor, Oral & Maxillofacial Diseases Research Center, Faculty of Dentistry, Mashhad University of Medical Sciences, Mashhad, Iran.
3. Dentist, Mashhad, Iran.
4. Postgraduate Student, Department of Oral & Maxillofacial Surgery, Faculty of Dentistry, Mashhad University of Medical Sciences, Mashhad, Iran.
5. Orthodontist Specialist, Mashhad, Iran.

Article Type

ABSTRACT

Case Report

Peripheral ameloblastoma (PA) is a rare subtype of ameloblastoma that occurs in soft tissue. It most commonly affects the mandible and is more common in males. It most commonly occurs in the sixth decade of life. This case report represented a 19-year-old girl with a 10-mm lesion on the lingual gingiva of the mandible. The surface was papillary and no pain or bleeding was noted. Histopathologic examination revealed neoplastic proliferation of odontogenic epithelial cells nested in a connective tissue context. Unlike many other PA cases, these nests appeared to originate from the basal cell layer of the epithelium. Cone-beam computed tomography and orthopantomogram did not reveal severe bone involvement and aggression. The patient is planned to be followed-up for 10 years. The prognosis of patients with PA is generally good, but cases of lesion recurrence have been reported. Due to the rarity of PA, further studies are needed on its development and treatment outcome.

Received: 21 Mar 2022

Revised: 4 May 2022

Accepted: 16 May 2022

Pub. online: 28 Jun 2022

Keywords: Odontogenic Tumors, Ameloblastoma, Mouth

Cite this article: Mosannen Mozafari P, Mohtasham N, Khorshid M, Alizadeh Abkooh M, Taherimoghadam S. Peripheral ameloblastoma: a case report and literature review. Caspian J Dent Res 2022; 11:130-5.



© The Author(s).

Publisher: Babol University of Medical Sciences

*Corresponding Author: Mehrzad Khorshid, Mashhad, Iran.

Tel: +98 915 692 5718

E-mail: Mehrzad.khorshid@gmail.com

Introduction

Ameloblastoma is the most common benign, locally destructive, epithelial odontogenic neoplasm, accounting for 1 % of all oral tumors and cysts and 11 to 59 % of odontogenic tumors.^[1] Ameloblastomas are tumors of odontogenic epithelial origin. They are slow-growing and locally infiltrating neoplasms. According to the latest 2017 World Health Organization classification of odontogenic tumors, ameloblastoma is divided into four categories: (a) conventional ameloblastoma, which may present as multicystic lesions; (b) unicystic ameloblastoma, which presents as a cystic intraosseous growth pattern; (c) peripheral ameloblastoma which is identical to intraosseous ameloblastoma but occurs primarily in the oral squamous epithelium covering the alveolus (extraosseous); and (d) metastatic ameloblastoma, an infiltrative intraosseous tumor characterized by extensive stromal collagenization or desmoplasia.^[2, 3] Peripheral ameloblastoma (PA) is a rare subtype of ameloblastoma that is less invasive.^[4] Basically, PA arises from remnants of dental lamina (glands of Serres) in the gingiva, although others have suggested that these lesions arise from the basal cell layer of the epithelium of the mucosal surface and pluripotent cells from minor salivary glands.

The average age of affected patients is 52.1 years, and most cases are in the fifth, sixth and seventh decades of life. In terms of gender, they are more common in males with a male-to-female ratio of 1.9:1. The mandible is a site where ameloblastomas are much more common than the maxilla.^[5] Based on investigations in Iran, only 4 cases have been reported. Another reason for the peculiarity of this case is that this lesion is more common in males, whereas this case was observed in a 19-year-old girl. In this report, a rare PA in the gingiva of the mandible of a 19-year-old girl is described and discussed.

Case Report

The present study was performed on CBCT images obtained from patients referred to a private oral and A 19-year-old girl was referred to a private dental clinic with a painless exophytic mass on the lingual gingiva of the right mandible that was discovered incidentally by an orthodontist in October 2020. She was otherwise healthy and not taking any herbal or chemical medications. A pinkish solid lesion with a papillary surface and a diameter of 10 mm was noted in the lingual gingiva of teeth numbers 28 and 29. No bleeding was observed (Figure 1).

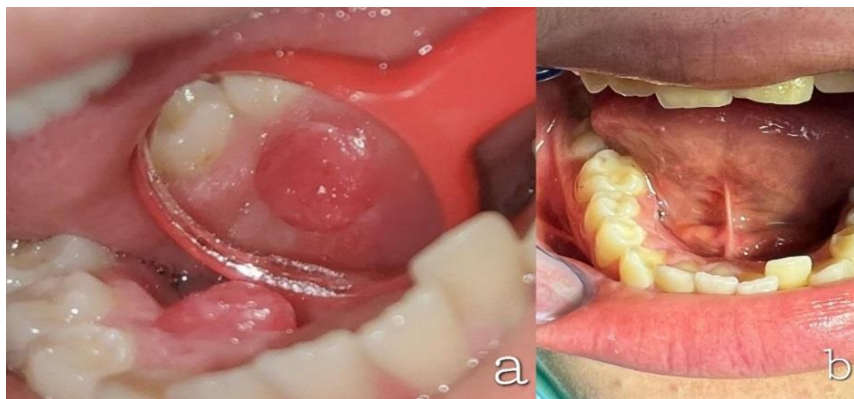


Figure 1. Intraoral images of peripheral ameloblastoma (a) showing the initial state of the lesion and (b) the follow-up in February 2022 indicating no traces of the lesion

No obvious irritation was observed because the orthodontist had not yet started treatment. The initial differential diagnosis consisted of a giant cell fibroma, a benign mesenchymal tumor, a papilloma, and an amelanotic melanoma. There were no other abnormalities in the oral cavity, oropharynx, or head and neck region. Orthopantomogram showed no abnormalities. An excisional biopsy was performed under local anesthesia.

Histopathologic examination revealed neoplastic proliferation of nests of odontogenic epithelial cells composed of ameloblastic columnar cells in the periphery and stellate reticular cells in the center, surrounded by connective tissue. It appeared that these nests originated from the basal cells of the mucosal epithelium. Continuity between the basal cell layer and tumor nests is evident as shown in Figure 2. In 400x magnification, some nests showed hyperchromatic basaloid cells with less cytoplasm than normal cells. Moreover, acanthomatous changes were evident in some nests (Figure 3).

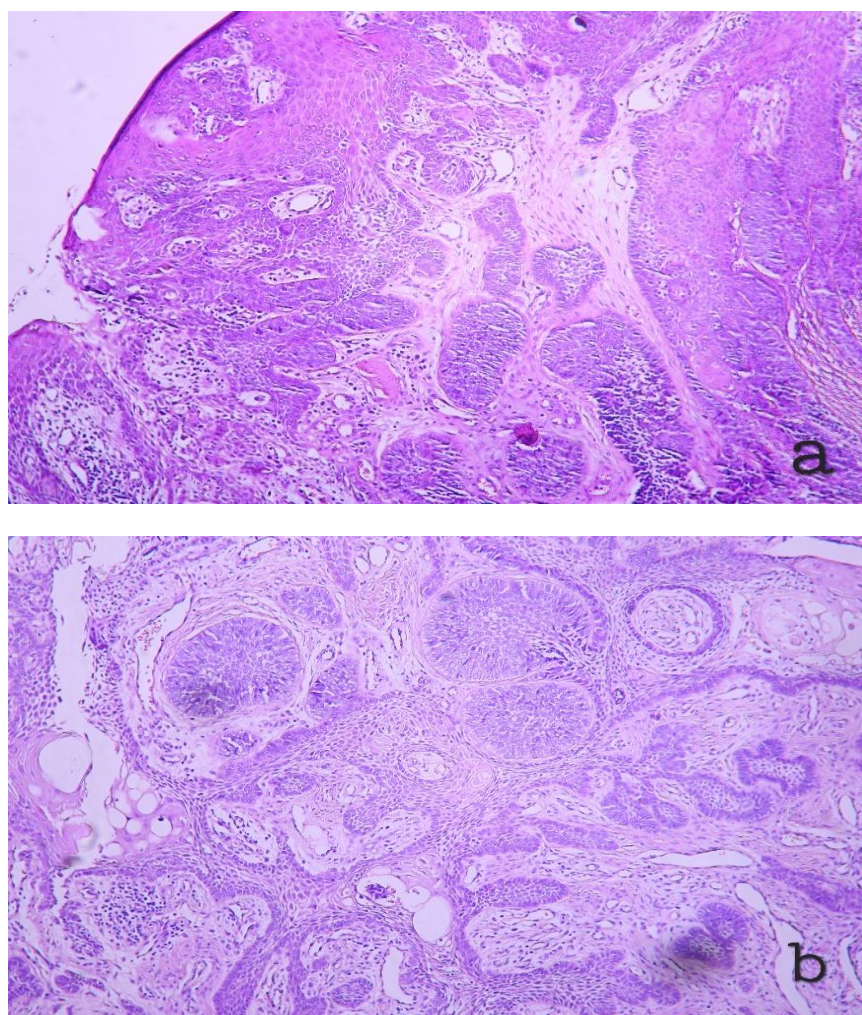


Figure 2. Histologic views of peripheral ameloblastoma (100x). Figure (a) shows the odontogenic epithelial cell nests, and continuity between the basal cell layer of the mucosal epithelium and the tumor is also obvious. Figure (b) illustrates nests with stellate reticular cells in the center and ameloblastic cells in the periphery

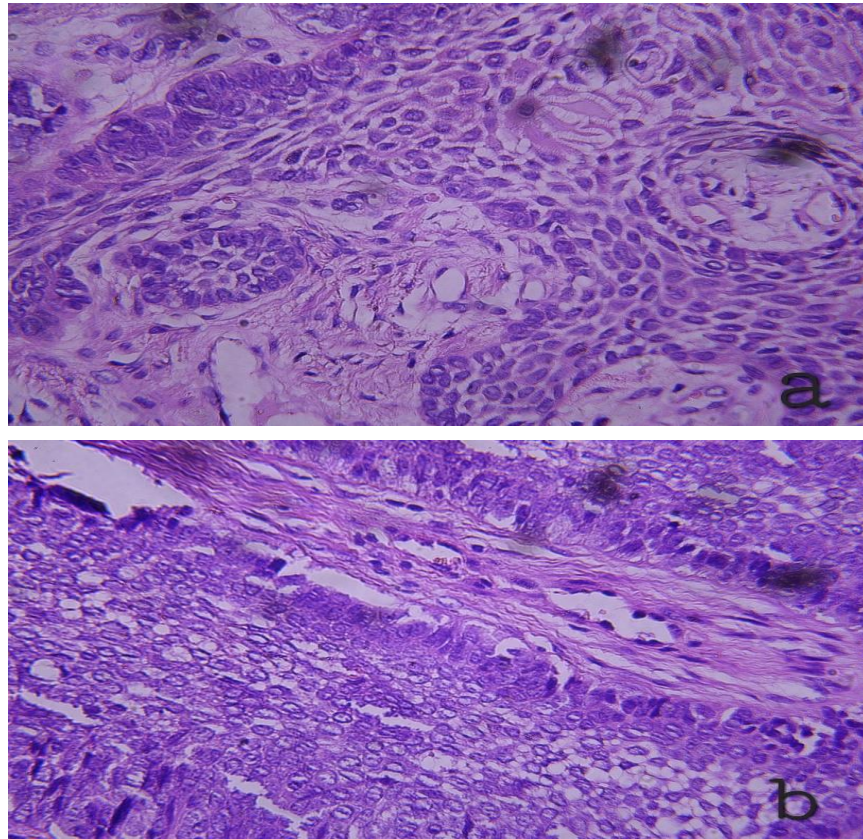


Figure 3. Histologic views of peripheral ameloblastoma (400x). Both images (a) and (b) show nests of hyperchromatic basaloid cells with less cytoplasm than normal cells. In addition, just as in Fig. 2, nests with stellate reticular cells in the center and ameloblastic cells in the periphery can be seen

Based on these findings, a diagnosis of PA was made and a cone-beam computed tomography (CBCT) was ordered for further evaluation. No major bone involvement was noted except for minor cortical resorption in the lingual portion of the mandible in the right around the roots of teeth 27 and 28, possibly due to recent surgical excision of the lesion. Because of the rare associated syndromes (Gorlin syndrome, epidermal nevus syndrome, Simpson-Golabi-Behmel syndrome and Williams syndrome), a clinical examination was performed that revealed no evidence of systemic disease. Due to the tumorous entity of the lesion, the patient was referred to an oral surgeon for removal of the lesion with safe margins down to the periosteum. She should be followed-up for 10 years. The patient would be followed-up every two months for the first year and once a year from the second year. The most recent images, taken in February 2022, are attached (Figure. 1). The patient has given written consent to publish the case study and all images for dissemination.

Discussion

PA consists of a proliferating odontogenic epithelium that has the same histomorphologic cell patterns as intraosseous ameloblastoma.^[5] It seems that PA is a rare subtype of ameloblastoma in Iran. Based on two studies by Saghravani et al., only 4 cases of PA have been reported in Iran.^[6, 7] Another article mentioned a case of PA that was the first female PA case reported in Iran. Unlike our case, it was in the buccal gingiva of the maxilla.^[8]

Most cases of PA were described as smooth, and only three cases were reported to have a papillary surface similar to that in our case.^[9] The median ages reported in the reviews ranged from 31.5 to 48.3 years old, indicating that PA is more common in older people than in younger ones. A predilection for males is also reported.^[10-12]

Histopathologic examination is crucial for diagnosis. The histogenesis of PA remains controversial. Some believe that PA arises from basal cell layer of mucosal epithelium while others believe it arises from remnants of the odontogenic epithelium in soft tissue.^[9, 13] Although in most cases there is no bone involvement, cupping or saucer formation of the underlying bone is visible in some cases in the literature. A 2019 study by Kelppe et al., presented an invasive case of PA in which it had penetrated the alveolar bone and some intraosseous ameloblastic nests were seen far from the main tumor.^[12]

Clinical differential diagnosis consists of epulis fissuratum, fibroma and amelanotic melanoma.^[14] Histopathologic differential diagnosis includes peripheral odontogenic fibroma (due to extensive epithelial odontogenic nests), odontogenic squamous cell tumor, and odontogenic gingival epithelial hamartoma.^[5] The traditional surgical technique, which involves extensive resection, is avoided in favor of a more conservative approach. In a recent study by Anpalagan et al., the following treatment is recommended: first, surgical excision of the tumor or any recurrent lesions. This should include the lesion and its entity, including a cuff of normal tissue. Generally, it is not necessary to remove surrounding teeth or bone, and second, long-term follow-up for at least 10 years for primary or recurrent lesions.^[1]

Another obscure fact about PA is the correlation of this lesion with some syndromes including Gorlin syndrome, epidermal nevus syndrome, Gardner syndrome, Simpson-Golabi-Behmel syndrome and Williams syndrome.^[15] Our patient did not meet the criteria of the mentioned syndromes. The probability of recurrence is between 9% and 20% at PA. The time recurrence ranged from 2 months to 7 years. Recurrent PA often occurs near the main lesion. It is thought that the main reason for recurrence is probably incomplete excision of the original lesion rather than the aggressiveness of the tumor. We should go one step further in choosing a treatment plan for a recurrent PA. Usually, it is a surgical conservative supraperiosteal excision with adequate free margins. Although rare, there are cases of malignant transformation of PA, so the risk should not be underestimated.^[1, 14]

Acknowledgments

I would like to express my sincere gratitude to the Shahab Clinic for providing patients' information. Completion of this report would not have been possible without its support. The authors would like to thank professor S.M.M. Hosseini Zarch for his radiographic report.

Authors' Contribution

Mosannen Mozafari P. accomplished collecting data, manuscript preparation and editing, patient examination and study supervision, and Mohtasham N. accomplished collecting data, literature search, manuscript preparation, and editing. Khorshid M. accomplished collecting data, literature search, manuscript preparation, and editing. Alizadeh Abkooh M and Taherimoghadam S. performed the patient examination and collected data.

References

1. Anpalagan A, Tzortzis A, Twigg J, Wotherspoon R, Chengot P, Kanatas A. Current practice in the management of peripheral ameloblastoma: A structured review. *Br J Oral Maxillofac Surg* 2020; 59: e1-8.
2. Milman T, Ying G-S, Pan W, LiVolsi V. Ameloblastoma: 25 year experience at a single institution. *Head Neck Pathol* 2016;10: 513-20.
3. Soluk-Tekkeşin M, Wright JM. The World Health Organization classification of odontogenic lesions: A summary of the changes of the 2017 (4th) edition. *Turk Patoloji Derg* 2018;34: 1-18.
4. Isomura ET, Okura M, Ishimoto S, Yamada T, Ono Y, Kishino M, et al. Case report of extragingival peripheral ameloblastoma in buccal mucosa. *Oral Surg Oral Med Oral Pathol Oral Radiol Endod* 2009; 108: 577-9.
5. Philipsen HP, Reichart PA, Nikai H, Takata T, Kudo Y. Peripheral ameloblastoma: Biological profile based on 160 cases from the literature. *Oral Oncol* 2001;37: 17-27
6. Saghravanian N, Jafarzadeh H, Bashardoost N, Pahlavan N, Shirinbak I. Odontogenic tumors in an Iranian population: A 30-year evaluation. *J Oral Sci* 2010;52: 391-6.
7. Saghravanian N, Salehinejad J, Ghazi N, Shirdel M, Razi M. A 40-year retrospective clinicopathological study of ameloblastoma in Iran. *Asian Pac J Cancer Prev* 2016;17: 619-23.
8. Hosseinkazemi H, Molania T, Abbaszadeh H, Seifi S, Zahedpasha S. Peripheral Ameloblastoma in the maxillary gingiva: A case report. *J North Khorasan Univ Med Sci* 2016;8: 191-7. [In Persian]
9. Zhu EX, Okada N, Takagi M. Peripheral ameloblastoma: Case report and review of literature. *J Oral Maxillofac Surg* 1995;53: 590-4.
10. Zhang X, Tian X, Hu Y, Zhang C, Wei C, Yang X. Oral peripheral ameloblastoma: a retrospective series study of 25 cases. *Med Oral Patol Oral Cir Bucal* 2018;23:e277.
11. Siar CH, Lau SH, Ng KH. Ameloblastoma of the jaws: a retrospective analysis of 340 cases in a Malaysian population. *J Oral Maxillofac Surg* 2012;70:608-15.
12. Kelppe J, Hagström J, Sorsa T, Suominen AL, Apajalahti S, Haglund C, et al. Ameloblastoma: a retrospective single institute study of 34 subjects. *Acta Odontol Scand* 2019;77:82-7.
13. Kishino M, Murakami S, Yuki M, Iida S, Ogawa Y, Kogo M, et al. A immunohistochemical study of the peripheral ameloblastoma. *Oral Dis* 2007;13: 575-80.
14. Yamanaka S, Nakao K, Nishikawa Y, Kashiwagi M, Mishima S, Kataoka T, et al. A case of peripheral ameloblastoma that developed in the maxillary gingiva of child. *J Oral Maxillofac Surg Med Pathol* 2020; 32: 257-60.
15. Atarbashi-Moghadam S, Atarbashi-Moghadam F, Sijanivandi S, Mokhtari S. Ameloblastoma associated with syndromes: A systematic review. *J Stomatol Oral Maxillofac Surg* 2020;121: 146-9.