

## Analysis of morphological and anthropometric variations of clivus using cone beam computed tomography in adults

Maryam Abdolmaleki<sup>1</sup>, Roshanak Ghafari<sup>2✉</sup>, Reza Pourkhalili<sup>3</sup>

1. Postgraduate student, Department of Oral and Maxillofacial Radiology, Isfahan (Khorasgan) Branch, Islamic Azad University, Isfahan, IR Iran.

2. Associate Professor, Department of Oral and Maxillofacial Radiology, Isfahan (Khorasgan) Branch, Islamic Azad University, Isfahan, IR Iran.

3. Assistant Professor, Department of Neurosurgery, Isfahan University of Medical Sciences, Isfahan, IR Iran.

✉ **Corresponding Author:** Roshanak Ghafari, Faculty of Dentistry, Isfahan (Khorasgan) Branch, Islamic Azad University, Isfahan, IR Iran.

**Email:** roshanakghaffari@yahoo.com

**Tel:** +989132034770

**ORCID** (0000-0002-8723-5640)

Received: 5 Sept 2020

Accepted: 12 Dec 2020

### Abstract

**Introduction:** Clivus forms the middle part of the skull base, and different anatomical and pathologies variations can be created in this structure. The aim of this study was to determine the morphological variations and anthropometric analysis of clivus in CBCT images.

**Material & Methods:** In this descriptive analytical study, CBCT images of 130 men and women over the age of 18 were evaluated using On-Demand 3D software. The width, length as well as skull base and clivus angle were measured. Clivus was also examined for anatomical variations such as pneumatization, canalis basilaris medianus, basilar invagination, fossa navicularis magna. Data were analyzed through one-way ANOVA and T-test using SPSS 22 ( $\alpha < 0.05$ ).

**Results:** The mean length of clivus was significantly higher in men (45.72mm) than in women (41.56mm) ( $P < 0.001$ ). The mean skull base angle was significantly higher in males (118.39 degrees) than in females (113.4 degrees) ( $P < 0.001$ ). The mean width and angle of clivus had no significant difference between two genders, and none of the study variables was significantly different in various age groups. The mean skull base angle was significantly higher (120.06 degrees) in patients who had basilar invagination (BI) ( $P < 0.001$ ). In the study of variations, 3 (2.3%) cases of incomplete pneumatization, 7 (5.4%) cases canalis basilar medianus of which 6 (4.6%) cases had fossa navicularis magna with mean length of 7.07 mm and 19 cases of BI (14.6%) with mean length of 3.55 mm were observed.

**Conclusion:** Familiarity of the maxillofacial radiologist with the anatomical variations of clivus, which were also rare, is important to differentiate from lesions. In anthropometric analysis, the length and angle of the skull base may be used to determine gender.

**Keywords:** Cone-beam computed tomography, Clivus, Anthropometry

**Citation for article:** Abdolmaleki M, Ghafari R, Pourkhalili R. Analysis of morphological and anthropometric variations of clivus using cone beam computed tomography in adults. Caspian J Dent Res 2021; 10:19-26.

## بررسی تنوعات مورفولوژی و آنالیز آنتروپومتری کلیوس با استفاده از CBCT در بزرگسالان

مریم عبدالملکی<sup>۱</sup>، روشنک غفاری<sup>۲\*</sup>، رضا پورخلیلی<sup>۳</sup>

۱. دانشجوی دستبازی، گروه رادیولوژی دهان، فک و صورت، دانشگاه آزاد اسلامی، واحد اصفهان (خوراسگان)، اصفهان، ایران.

۲. دانشیار، گروه رادیولوژی دهان، فک و صورت، دانشگاه آزاد اسلامی، واحد اصفهان (خوراسگان)، اصفهان، ایران.

۳. استادیار، گروه جراحی مغز و اعصاب، دانشگاه علوم پزشکی اصفهان، اصفهان، ایران.

\*نویسنده مسئول: روشنک غفاری، دانشکده دندانپزشکی، دانشگاه آزاد اسلامی، واحد اصفهان (خوراسگان)، اصفهان، ایران.

پست الکترونیکی: roshanakhaffari@yahoo.com تلفن: +۹۸۹۱۳۲۰۳۴۷۷۰

### چکیده

**مقدمه:** کلیوس قسمت میانی بیس اسکال را تشکیل می‌دهد و تنوعات آناتومیک و پاتولوژی‌های مختلفی می‌تواند در این ساختار ایجاد شود. هدف از این مطالعه تعیین تنوعات مورفولوژی و آنالیز آنتروپومتری کلیوس در تصاویر CBCT بود.

**مواد و روش‌ها:** در این مطالعه توصیفی تحلیلی تصاویر CBCT از ۱۳۰ زن و مرد بالای ۱۸ سال، با استفاده از نرم افزار demand 3D مورد ارزیابی قرار گرفت. عرض کلیوس، طول کلیوس و زوایای بیس اسکال و کلیوس اندازه گیری شد، همچنین کلیوس از نظر وجود تنوعات آناتومیک نظیر پنوماتیزاسیون، کانالیس بازیلر مدیانوس، بازیلر اینواژیناسیون، فوسانویکولاریس ماگنا و طول آن مورد بررسی قرار گرفت. داده‌ها با استفاده از نرم افزار SPSS 22 از طریق آزمون تی مستقل، آنالیز واریانس یکطرفه آنالیز شد ( $\alpha < 0.05$ ).

**یافته‌ها:** میانگین طول کلیوس در مردان (45.72 mm) به طور معناداری بیشتر از زنان (41.56mm) ( $P < 0.001$ ) بود. میانگین زاویه بیس اسکال در مردان (۱۱۸/۳۹ درجه) به طور معناداری بیشتر از زنان (۱۱۳/۴ درجه) بود ( $P < 0.001$ ) میانگین عرض و زاویه کلیوس در دو جنس تفاوت معناداری نداشت و هیچ یک از متغیرهای مطالعه تفاوت معناداری در رده‌های سنی مختلف نداشتند و میانگین زاویه بیس اسکال در افرادی که بازیلر اینواژیناسیون داشتند (۱۲۰/۰۶ درجه) بطور معناداری بیشتر بود ( $P < 0.001$ ). در بررسی تنوعات ۳ مورد (۲/۳٪) پنوماتیزاسیون ناقص ۷ مورد (۵/۴٪) کانالیس بازیلر مدیانوس که ۶ مورد (۴/۶٪) آن از نوع فوسانویکولاریس ماگنا با متوسط طول (7.07 mm) بود و ۱۹ مورد (۱۴/۶٪) بازیلر اینواژیناسیون با متوسط طول (3.55 mm) یافت شد.

**نتیجه گیری:** آشنایی رادیولوژیست فک و صورت با تنوعات آناتومیک کلیوس که شیوع کمی هم داشتند برای تمایز از ضایعات حائز اهمیت است، در بررسی آنتروپومتری کلیوس شاید بتوان از طول و زاویه بیس اسکال در تعیین جنسیت استفاده کرد.

**واژگان کلیدی:** توموگرافی کامپیوتری با اشعه مخروطی، کلیوس، آنتروپومتری

### Introduction

The skull base is a very complex structure and its middle part is composed of clivus.<sup>[1]</sup> The importance of this structure is due to the possibility of important pathologies such as chondroma, tumor metastasis, inflammation, fibrosis dysplasia and fractures in traumas. In addition, studies on estimating age and sex based on clivus dimensions have been performed for forensic science examinations.<sup>[2,3]</sup> In the study of numerical values related to clivus, in addition to the length and width, two angles (clivus canal angle and Welcher basal angle) related to clivus have been studied

Moreover, anatomical variations have been reported in clivus bone, which may be due to the degeneration, congenital/developmental or pathological abnormalities, and age in addition to gender are also influential.<sup>[3]</sup> Anatomical variations include clivus cavitation so that the sphenoid sinus can pneumatize this bone (incompletely or completely).<sup>[6,7]</sup> Canalis basilaris medianus (CBM) is an uncommon variation of the base occiput, which is a congenital defect with no clinical signs, is seen in 2% of dry scales and is divided into two types including complete and incomplete.<sup>[8,9]</sup> Fossa

navicularis magna as a round depression often occurs in the lower part of the clivus in anterior pharyngeal tuberosity, which can be a subset of the basilar canal or associated with the nasopharyngeal mucosal cyst.<sup>[1]</sup> Clivus hypoplasia as a shortened clivus is a common finding in all patients with achondroplasia and chiari anomalies. However, cases of clivus hypoplasia have been reported in individuals without any other specific disease or abnormality, which can be attributed to premature fusion or reduced growth of spheno-occipital synchondrosis and is usually associated with platybasia and increased Welcher angle.<sup>[10-12]</sup> Basilar invagination (BI) is an evolutionary abnormality of the occipital bone and cervical spine, leading to severe prolapse of the spine into the skull. Recognition of this as a radiological finding is confirmed when the odontoid tip at least 2 mm crosses the chamberlain line.<sup>[4]</sup> Bayrak et al. investigated the relationship between anthropometric analysis of foramen magnum and clivus with age and gender. Clivus length and width were also measured and the results were obtained as follows: there was no significant relationship between age and dimensions of the foramen magnum and there was a significant relationship between age and length of clivus in different age groups. Clivus was longer and wider in men than women.<sup>[13]</sup>

Edward et al. studied CBCT images of the cervical vertebrae and clivus and concluded that the prevalence of clivus hypoplasia, BI and fossa magna was 0.02, 0.06 and 0.01%, respectively, and the clivus cavitation was observed in 1 complete case and 4 partial cases (0.05%).<sup>[6]</sup> Caurasia et al. conducted a study on the evaluation and morphology of clivus in Indians using CBCT and showed that the estimation of clivus dimensions was directly dependent on age and gender.<sup>[2]</sup> Due to the anatomical variations, possibility of involvement of this structure in fractures and pathologies as well as development of the use of CBCT in dentistry, the diagnosis, differentiation and management of the findings are necessary for maxillofacial radiologists who should have sufficient information in this regard. To our best knowledge, no study was done on the CBCT in this field.

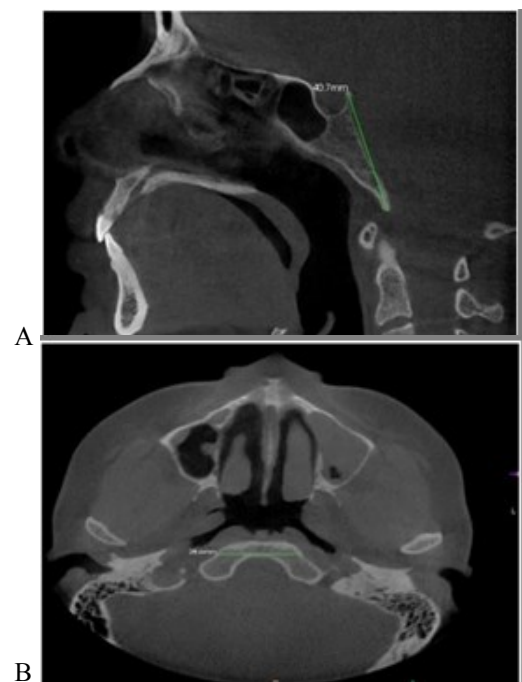
## Materials & Methods

This study was approved by the Ethics Committee of Isfahan Azad University (Khorasgan), Isfahan, Iran (with the code of IR.IAU.KHUISF.REC.1398.123).

This descriptive-analytical study was performed on 130 patients over 18 years of age, referred to a private radiology center in Isfahan in 2019-2020 by convenience sampling method. Patients were divided into three groups in terms of age: 18-39 years, 40-59 years and >60 years.

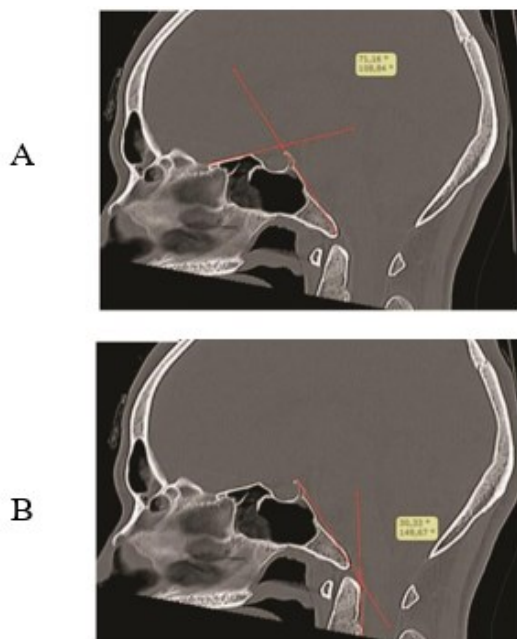
Exclusion criteria included samples whose clivus bone was not clear in the resulting image, or patients with a history of surgery or trauma in the head and face, or patients with syndromes. In this study, evaluation was performed on CBCT images taken with the Soredex Nahkelatie, Tuusula, Finland (Flat panel CMOS).

Images in large field (130 \* 145 mm), covering the clivus and skull base areas were used. The reconstructed multiplanar images (axial, sagittal, coronal sections) were examined using On-demand 3D-Version 1 software. First, the position of the head was adjusted so that the sagittal plane was vertical, and the anterior nasal spine and hard palate was parallel to the ground, and then the dimensions of the clivus were measured as shown in figure 1.<sup>[2]</sup> Clivus length: In the reconstructed sagittal view, it was the longest upper and lower distance from the upper point of the dorsum sella to the lower point of the anterior margin of the foramen magnum. (Figure 1-a). Clivus width: In reconstructed axial radiographs, it was the longest distance from the left and right of front of the anterior margin of the foramen magnum (Figure 1-b).



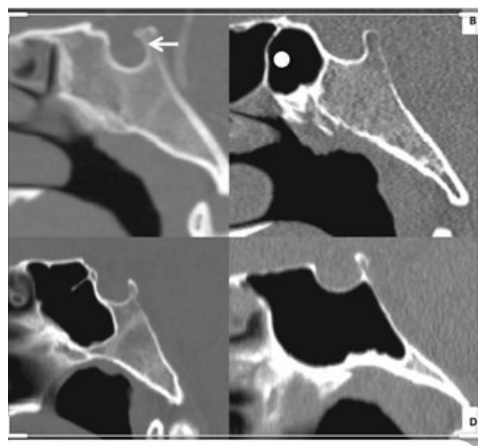
**Figure 1. A: The length of clivus B: The width of clivus**

Welcher angle: it was measured from the linear intersection of the sphenoid plenum and the clivus (Figure 2-a). Clivus angle: In the reconstructed sagittal view, it set from a linear intersection along the posterior surface of the clivus with a line passing through the posterior surface of the cervical vertebrae. (Figure 2-b).

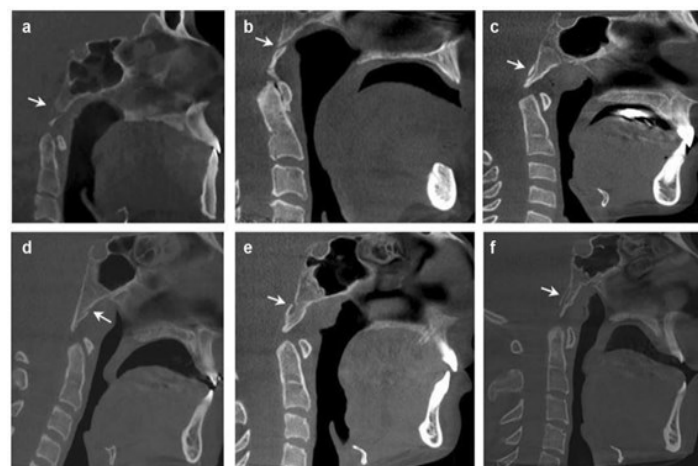


**Figure 2. A: Angle of the skull base, B: Angle of clivus**

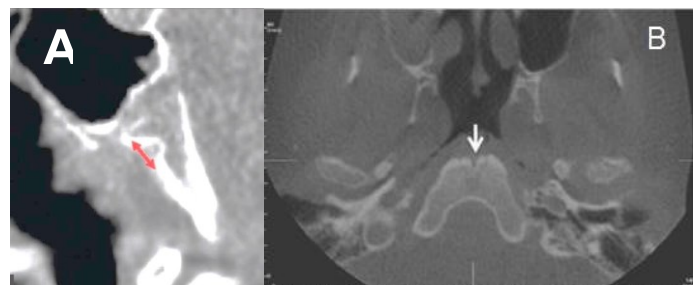
In the present study, according to the similar studies based on available images, the anatomical variations of clivus were measured in terms of pneumatization (Figure 3), CBM (Figure 4), fossa navicularis magna (Figure 5) as subsets of canalis basilaris medianus, and its length was measured if found (Figure 5). Clivus hypoplasia (Figure 6) and its relationship with BI were also investigated. Like other study <sup>[4]</sup>, the current study considered the presence of an odontoid appendage at least 2 mm above its chamberlain's line to BI.



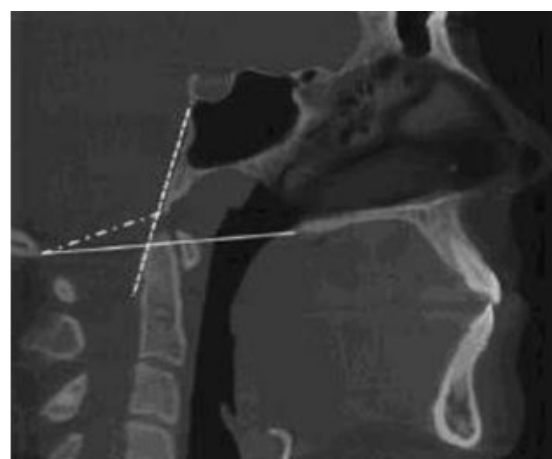
**Figure 3. Clivus pneumatization**



**Figure 4. Canalis basilar median**



**Figure 5. Fossa navicularis magna in sagittal view: its length (A) and its axial (B)**



**Figure 6. Clivus hypoplasia and drawing the chamber lain line**

BI: The radiographic view illustrated that the odontoid appendage intersected the chamber lain line (the line that runs from the end of the hard palate to the posterior border of the foramen magnum). Analysis was performed at both descriptive and analytical levels. At the descriptive level, the mean and standard deviations, frequency distribution tables and statistical graphs were used. At the analytical level, the independent t-test and one-way analysis of variance were applied. The tests were performed at a level of 0.05 error ( $\alpha < 0.05$ ) using



SPSS 22. All measurements were performed under the supervision of a maxillofacial radiologist in collaboration with a neurosurgeon, and then the data were analyzed to determine the mean.

## Results

In the ongoing study, according to the tables 1 and 2, the mean length of clivus was significantly longer in males (45.7 mm) than females (41.56 mm) ( $P < 0.001$ ). The mean skull base angle was significantly higher in men (118.39 degrees) than women (113.4 degrees) ( $P < 0.001$ ), the mean width of clivus was not significantly different between two genders ( $p = 0.68$ ). The mean clivus angle had no significant difference between two genders and different age groups ( $p = 0.368$ ). Clivus length was not significantly different in various age groups ( $p = 0.203$ ). Skull base angle had no

significant difference in different age groups ( $p = 0.334$ ). As illustrated in table 3, 3 (2.3%) cases of incomplete pneumatization, 7 (5.4%) cases canalis basilar medianus of which 6(4.6%) cases had fossa navicularis magna with an average length of 7.07 mm (minimum=5.90mm and maximum=8.40mm), 19 (14.6%) cases of BI with average length of 3.55 mm are observed in the study of variations (minimum=2mm and maximum=10.56). According to tables 4, there is no significant difference in the mean length of clivus between those with BI and without BI ( $p = 0.599$ ). There was a significant difference in the mean clivus angle between those with BI (158.06) and without BI (160.06) so that it was significantly less in those who had ( $p = 0.043$ ). Moreover, there was a significant difference in the skull base angle between two groups ( $p < 0.001$ ), and it was significantly higher in those with BI.

**Table 1. Mean length, width and angle of clivus and skull base in both genders**

	Pvalue	Women(n=62)	Men(n=68)
Clivus Length (mm)	< 0.001	41.56 ± 2.88	45.72 ± 3.56
Clivus width (mm)	0.680	31.49 ± 2.14	31.32 ± 2.61
Clivus angle (degree)	0.368	159.83 ± 5.59	160.63 ± 4.30
Skull base (degree)	< 0.001	113.4 ± 4.31	118.39 ± 4.65

**Table 2. Mean length, width and angle of clivus and skull base in different age groups**

	Pvalue	60 years and older (n=31)	40-59 (n=44)	18-39 (n=55)
Clivus Length (mm)	0.203	43.38 ± 4.47	44.58 ± 3.72	43.27 ± 3.53
width Clivus (mm)	0.152	31.22 ± 2.32	30.98 ± 2.71	31.86 ± 2.10
angle Clivus (degree)	0.498	160.65 ± 6.17	159.52 ± 5.09	160.59 ± 4.02
Skull base angle (degree)	0.334	116.38 ± 6.05	116.71 ± 5.78	115.24 ± 3.83

**Table 3. Frequency distribution of clivus anatomical variations and presence of BI based on CBCT images**

diversity				NUM	%	
pneumatization				Have (Incomplete)	3	2.3
				Does not have	127	97.7
Canalis medianus	basilar	Have	7	5.4		
		Does not have	123	94.6		
Basilar invagination		Have	19	14.6		
		Does not have	111	85.4		
Total			130	100		

**Table 4. Comparison of mean clivus and skull base angle based on the presence as absence of BI**

Variable	Basilar invagination	Num	average	P value
Clivus Length (mm)	Dose not have	111	43.66 ± 3.81	0.599
	have	19	44.17 ± 4.18	
angle Clivus (degree)	Dose not have	111	160.06 ± 4.94	0.043
	have	19	158.06 ± 4.61	
angle skull base (degree)	Dose not have	111	115.32 ± 4.87	< 0.001
	have	19	120.06 ± 4.77	

## Discussion

Clivus is the middle part of the skull base and has a high clinical significance and can be examined from different aspects so that this structure may be associated with normal anatomical variations and various pathologies.<sup>[6,8,9]</sup>

Another aspect is clivus anthropometry since the clivus is a denser part of the bony skull that usually survives injuries, and may be used as an appropriate anthropometric criterion to delineate age and gender in forensic medicine.<sup>[2]</sup> Given that the signs and symptoms of clivus problems are often nonspecific or even non-existent, imaging is one of the main ways to diagnose the disease.<sup>[3]</sup> Among these, the CBCT has many advantages over CT such as spatial resolution, fast scan time, and most importantly, lower doses of radiation.<sup>[1]</sup>

In the current study, the mean length of clivus was significantly higher in men than women. In the studies of Bayrak et al.<sup>[13]</sup> and Caurasia et al.<sup>[2]</sup> the mean length of clivus was significantly higher in men than women.

In the ongoing study, there was no significant difference in the mean length of clivus in different age groups, and in contrast, Syed et al.<sup>[8]</sup> and Caurasia et al.<sup>[2]</sup> studied on different age groups and concluded that there was a significant difference between the lengths of clivus. Note that the age group of the present was >18 years to complete the growth of clivus, and the differences between the present study and the mentioned studies could be due to this. Besides, in the present study, no significant difference was found in clivus width between two genders in different age groups. However, in the study of Bayrak et al.<sup>[13]</sup> the mean width of clivus was significantly higher in men than women, and there was no significant difference in different age groups. In the study of Caurasia et al.<sup>[2]</sup> the mean width of clivus was not significantly different between two genders, but there was a significant difference between different age groups. Clivus change in length can be attributed to an idiopathic finding,

premature fusion and reduced bone growth of Spheno-occipital synchondrosis.<sup>[13]</sup> There is a study that emphasizes clivus length change in some congenital or acquired abnormalities.<sup>[2]</sup> It seems that a vital growth time for clivus is from the birth to 11 years old.<sup>[2]</sup> Clivus remains isolated by Spheno-occipital synchondrosis until the age of 16-20.<sup>[1]</sup>

The angle of the skull base is very important in human genetic development. The average of this angle varies in different races and occurs with increasing skull base angle to more than the normal amount of skull base or Platybasia. Some researchers have reported >143-degree increase in angle as a Platybasia and others have stated >150-degree increase.<sup>[14]</sup> Most anomalies are associated with a reduction in clivus angle.<sup>[3]</sup>

Platybasia and BI usually occur together and happen in some congenital anomalies including osteogenesis imperfecta, cleidocranial dysostosis and Chiari malformations. Furthermore, it may be found in some acquired abnormalities such as paget's, osteomalacia, rickets hyperparathyroidism and trauma. When platybasia occurs alone and without any other abnormality, it is not clinically significant, and patients are asymptomatic and do not require treatment.<sup>[14]</sup>

In the present study, the mean skull base angle was significantly higher in men than women, but there was no significant difference between different age groups. However, in the study of Hirunpat et al.<sup>[14]</sup> no significant differences were found between men and women, and in their study like our study, there was no significant difference between different age groups. There was no significant difference between men and women and different age groups in clivus angle. In the present study, in 19 patients (14.6%), the odontoid tip was higher than the chamberlain line, and the mean length of the clivus had no significant difference between those with BI and without BI. Nevertheless, the mean clivus angle was significantly lower in patients with BI and the skull base angle was significantly

higher in ones with BI. The BI leads to severe prolapse in vertebral column into the skull. The main causes of BI are clivus hypoplasia, occipital condyle hypoplasia, atlas hypoplasia and congenital atlanto-axial instability. UP to now, a robust and standard criterion for has been proposed to diagnose BI due to the higher degree of odontoid tip than Chamberlain line and odontoid tip, many patients who are normal and do not have any clinical signs or abnormalities are higher than Chamberlain line.

In BI, because of the pressure on the nervous system of the brain and upper part of the spine, the patients may have clinical and neurological symptoms and difficulty in neck movements, and patients with this condition should avoid stretching and contact exercises.<sup>[6]</sup>

In the present study, 3 cases of incomplete clivus pneumatization were observed. In the study of Edward et al.<sup>[6]</sup> one complete case and four incomplete pneumatization were reported. Clivus pneumatization has a low prevalence but it should be diagnosed owing to differential diagnosis with lesions.<sup>[6]</sup>

In rare cases, the sphenoid sinus can pneumatize the entire clivus and terminate in the anterior margin of the occipital foramen, and the neurosurgeon or ENT surgeon must be aware that the wall is very thin or even cracked. Iatrogenic perforation can easily occur, and perforation of this lamella is very dangerous for the basilar artery or brainstem, located directly above the clivus.<sup>[3]</sup> The CBM as a rare variant is divided into a bilateral or unilateral, complete or incomplete cleft or groove in the clivus surface. It should be differentiated from fractures and spheno-occipital synchondrosis which is normal in children and adolescents.<sup>[3]</sup> This canal usually consists of a venous vessel that forms an anastomosis between the venous system inside and outside the skull, and therefore, can be a weakness at the base of the skull.<sup>[3]</sup> Because of its potential association with meningitis, its possible side effects should be reported.<sup>[8]</sup> In the current study, 7 cases (5.4%) of CBM were observed, among them 1 was incomplete and 6 cases were fossa navicularis magna (FNM).

In our study, the mean length of 6 cases (4.6%) of fossa navicularis magna was 7.07 mm. Some researchers believe that the FMN can be a defective type of CBM and in rare cases acts as a route of infection from the oropharynx to the base of the skull.<sup>[1]</sup> Therefore, this finding should be diagnosed and reported by a maxillofacial radiologist.

One of the problems of the ongoing study was to find radiographs that met the requirements of our study and included the clivus area and foramen magnum. Additionally, the number of patients referred to the clinic for CBCT imaging was very low from 18 to 30 years old and  $\geq 60$  years old. It is suggested that further studies should be performed to predict age and gender from clivus dimensions on CBCT in the Iranian population. Besides, more studies should be conducted on CBCT in the larger statistical population to investigate the prevalence of FNM, its dimensions and relationship with age and gender in Iran.

## Conclusion

In this study, the mean of clivus length and skull base angle was significantly higher in men than women, which may be used to determine gender. In addition, the CBM was the most common among the studied variations. The familiarity of the maxillofacial radiologist with the anatomical variations of clivus despite the low prevalence is important for distinguishing between lesions. The CBCT imaging can be helpful because of its ability to regenerate multi-planar lower radiation dose.

**Funding:** This study was research project (Grant no: 30193), supported and funded by Isfahan (Khorasgan) Branch, Islamic Azad University, Isfahan, Iran.

**Conflict of interest:** We declare no conflict of interest

## Authors' Contribution

The study was designed by Roshanak Ghafari. The study data were collected by Maryam Abdolmaleki. Analysis of data was performed by Maryam Abdolmaleki. Study supervision was conducted by Roshank Ghafari and Reza Pourkhalili.

## References

1. Syed AZ, Mupparapu M. Fossa navicularis magna detection on cone-beam computed tomography. *Imaging Sci Dent* 2016;46:47-51.
2. Chaurasia A, Katheriya G, Patil R. Radiomorphometric evaluation of Clivus in Indian ethnicity-A cone beam computed tomography study. *J Oral Med Oral Surg Oral Pathol Oral Radiol* 2017;3:35-41.

3. Hofmann E, Prescher A. The clivus: anatomy, normal variants and imaging pathology. *Clin Neuroradiol* 2012;22:123-39.
4. Joaquim AF, Fernandes YB, Mathias RN, Batista UC, Ghizoni E, Tedeschi H, et al. Incidence of basilar invagination in patients with tonsillar herniation? A case control craniometrical study. *Arq Neuropsiquiatr* 2014;72:706-11.
5. Ferreira JA, Botelho RV. Determination of normal values of the basal angle in the era of magnetic resonance imaging. *World Neurosurg* 2019;132:363-67.
6. Edwards R, Alsufyani N, Heo G, Flores-Mir C. The frequency and nature of incidental findings in large-field cone beam computed tomography scans of an orthodontic sample. *Prog Orthod* 2014;15:37.
7. Jalali E, Tadinada A. Arrested pneumatization of the sphenoid sinus mimicking intraosseous lesions of the skull base. *Imaging Sci Dent* 2015;45:67-72.
8. Syed AZ, Zahedpasha S, Rathore SA, Mupparapu M. Evaluation of canalis basilaris medianus using cone-beam computed tomography. *Imaging Sci Dent* 2016;46:141-4.
9. Bayrak S, Göller Bulut D, Orhan K. Prevalence of anatomical variants in the clivus: fossa navicularis magna, canalis basilaris medianus, and craniopharyngeal canal. *Surg Radiol Anat* 2019;41:477-83.
10. Rai R, Iwanaga J, Shokouhi G, Loukas M, Mortazavi MM, Oskouian RJ, et al. A comprehensive review of the clivus: anatomy, embryology, variants, pathology, and surgical approaches. *Childs Nerv Syst* 2018;34:1451-8.
11. Kaplan FA, Yesilova E, Bayrakdar IS, Ugurlu M. Evaluation of the relationship between age and gender of fossa navicularis magna with cone-beam computed tomography in orthodontic subpopulation. *J Anat Soc India* 2019 ;68:201.
12. Magat, G. "Evaluation of morphometric features of fossa navicularis using cone-beam computed tomography in a Turkish subpopulation." *Imaging Sci Dent* 2019; 49: 209-12.
13. Bayrak S, Göller Bulut D. Assessment of foramen magnum and clivus for estimation of age and gender using Cone-beam CT. *J Dent Fac Atatürk Uni* 2019; 29:244-.51.[In Turkish]
14. Hirunpat S, Wimolsiri N, Sanghan N. Normal value of skull base angle using the modified magnetic resonance imaging technique in Thai population. *J Oral Health Craniofac Sci* 2017;2:017-21.