

Changes of occlusal plane inclination after orthodontic treatment with and without extraction in Class II patients

Masumeh Darabi¹, Samaneh Sadeghi^{2✉}

1. Postgraduate Student, Department of Orthodontics, School of Dentistry, Kerman University of Medical Sciences, Kerman, IR Iran.

ORCID (0000-0001-7329-8037)

2. Assistant Professor, Oral and Dental Diseases Research Center, Kerman University of Medical Sciences, Kerman, IR Iran.

✉Corresponding Author: Samaneh Sadeghi, Department of Orthodontics Dentistry, School of Dentistry, Kerman University of Medical Sciences, Kerman, IR Iran.

Email: samaneh_sa82@yahoo.com

Tel: +983432118074

ORCID (0000-0003-4099-3425)

Received: 14 Jul 2019

Accepted: 9 Feb 2020

Abstract

Introduction: The inclination of the occlusal plane (OP) is related to type of dental occlusion. The aim of this study was to evaluate and compare the inclination of occlusal plane in Class II patients treated with the upper first premolars extraction or non-extraction modalities.

Materials & Methods: Totally, forty 16-25-year-old patients (15 males and 25 females) with class II malocclusion, whose active phase of orthodontic treatment was completed using MBT with 0.022-inch slot size, were selected. Twenty patients were treated with extraction of upper first premolars and the rest were treated without any extraction. Pre- and post-treatment cephalograms were traced and several cephalometric variables were measured. The pre- and post-treatment changes of angles within each group and between two groups were compared via paired t-test and independent t-test, respectively. The statistically significant level was set at $p < 0.05$.

Results: After treatment, functional occlusal plane (FOP) angle to sella-nasion (SN) plane angle increased in both groups (0.5 degree in extraction group and 0.6 degree in non-extraction group), which was not statistically significant in both groups. Bisecting occlusal plane (BOP) angle to SN plane one in the extraction group enhanced by 0.8 degree, which was not statistically significant, but it decreased by 0.8 degree in the non-extraction group, which was not statistically significant.

Conclusion: Although the use of extraction and non-extraction protocols for the treatment of Class II patients did not cause significant changes in the BOP-SN and FOP-SN angles, small changes in these angles can have marked clinical changes in facial harmony and occlusal relationships. Extraction decision depending on factors such as amount of crowding, incisors protrusion, etc.

Keywords: Occlusal plane, Orthodontics, Treatment, Tooth extraction

Citation for article: Darabi M, Sadeghi S. Changes of occlusal plane inclination after orthodontic treatment with and without extraction in Class II patients. Caspian J Dent Res 2020; 9:8-16.

تغییرات شیب پلان اکلوزال بعد از درمان ارتودنسی با و بدون کشیدن دندان در بیماران کلاس II

معصومه دارابی^۱، سمانه صادقی^{۲*}

۱. دانشجوی دستیار، گروه ارتودنتیکس، دانشکده دندانپزشکی، دانشگاه علوم پزشکی کرمان، کرمان، ایران.

۲. استادیار، مرکز تحقیقات بیماری های دهان و دندان، دانشگاه علوم پزشکی کرمان، کرمان، ایران.

*نویسنده مسئول: سمانه صادقی، گروه ارتودنتیکس، دانشکده دندانپزشکی، دانشگاه علوم پزشکی کرمان، کرمان، ایران.

تلفن: +۹۸۳۴۳۲۱۱۸۰۷۴

پست الکترونیکی: samaneh_sa82@yahoo.com

چکیده

مقدمه: شیب پلان اکلوزال به نوع اکلوزن دندان مربوط می شود. هدف از این مطالعه بررسی و مقایسه تغییرات شیب پلان اکلوزال در بیماران کلاس II تحت درمان با کشیدن پره مولر اول بالا و بدون کشیدن می باشد.

مواد و روش ها: در مجموع، ۴۵-۱۶ ساله (۱۵ مرد و ۲۵ زن) مبتلا به مال اکلوزن کلاس II، که مرحله فعال درمان ارتودنسی آنها با استفاده از MBT با اندازه اسلات ۰/۰۲۲ اینچ به اتمام رسیده بود، انتخاب شدند. ۲۰ نفر از بیماران به روش کشیدن و ۲۰ نفر به روش بدون کشیدن درمان شده بودند. سفالوگرامها قبل و بعد از درمان ترس و چندین شاخص سفالومتریکی اندازه گیری شدند. تغییرات زوایا قبل و بعد از درمان در هر گروه و بین دو گروه به ترتیب از طریق آزمون تی زوجی و تی مستقل مقایسه گردید. از نظر آماری، سطح معناداری $P < 0.05$ در نظر گرفته شد.

یافته ها: زاویه پلان اکلوزال فانشکنال به پلان سلا-نازیون (FOP-SN) بعد از درمان در هر دو گروه افزایش یافته بود که در گروه کشیدن ۵/۵ درجه و در گروه بدون کشیدن ۶/۰ درجه افزایش را نشان داد که در هر دو گروه از لحاظ آماری معنی دار نبود. زاویه پلان اکلوزال بای سکت به پلان سلا-نازیون (BOP-SN) در گروه کشیدن ۸/۰ درجه افزایش نشان داد و از لحاظ آماری معنی دار نبود. این زاویه در گروه بدون کشیدن ۸/۰ درجه کاهش را نشان داد که از لحاظ آماری معنی دار نبود.

نتیجه گیری: اگرچه استفاده از پروتکل کشیدن یا بدون کشیدن برای درمان بیماران کلاس دو تغییر معناداری در زاویه های FOP-SN و BOP-SN ایجاد نمی کند، اما تغییرات کوچک در این زوایا می تواند تغییرات کلینیکی مشخصی بر هارمونی صورت و روابط اکلوزالی داشته باشد. تصمیم به کشیدن دندان به عواملی از قبیل میزان شلوغی، بیرون زدگی انسیزورها و... بستگی دارد.

واژگان کلیدی: پلان اکلوزال، ارتودنسی، درمان، کشیدن دندان

Introduction

Factors influencing on the success rate in class II malocclusion treatment are treatment protocol, severity of malocclusion, age of patient and degree of patient compliance. [1] Treatment of Class II malocclusion is performed with or without extraction. The extraction protocol includes the extraction of upper premolar whereas non-extraction treatment is performed using appliances which distalize the upper teeth such as headgear and temporary anchorage devices (TAD), and/or protruding lower teeth devices including orthopedic functional appliances. [1,2] Different features such as facial appearance, occlusal stability, dental arch characteristics and their effects on dentofacial complex should be considered as an appropriate treatment option for cases. [3] Upper and lower anterior crowding and

protrusion as well as profile convexity play an important role to make the extraction decisions. [4, 5] It has been shown that Class II malocclusion can be caused by 1) anterior position of the maxilla or maxillary alveolar process, 2) small mandible or posterior position of the mandibular teeth, 3) posterior position of temporomandibular joint or a combination of them. [6] One factor, which determines treatment strategy, is the cause of malocclusion. The inclination of occlusal plane (OP) plays a pivotal role in the establishment of different dental/skeletal patterns. [7, 8] The change in the inclination of OP can shift the position of mandible in relation to maxilla. The cant of the posterior OP has an effect on the vertical height of occlusion. During the orthodontic treatment, the position and angulation of

teeth are altered, affecting the balance of masticatory system and leading to relapse.^[9]

The commonly used OP(s) are the bisected occlusal plane (BOP) and functional occlusal plane (FOP). The BOP is a line connecting the point bisecting the incisal overbite and the point bisecting the upper first molar cusp height. The FOP as a plane is formed by bisecting the intercuspation of the first molars and intercuspation of the first premolars.^[9] The aim of the current study was to cephalometrically evaluate and compare the OP and some skeletal/dental variables before and after orthodontic treatment of Class II patients treated with or without upper premolar protocol.

Materials & Methods

This retrospective study was performed at the Oral and Dental Diseases Research Center of Kerman University of Medical Sciences in Iran. The lateral cephalograms of 40 patients (25 females, 15 males) aged 16-25 years were selected after taking ethical approval from Kerman University of Medical Sciences (IR.KMU.REC.1396.1172). The two upper first premolars of 20 patients were extracted and 20 cases were treated without extraction. The inclusion criteria were patients with: pre-treatment Class II Division 1 malocclusion, indicating a molar relationship of at least "end-on", a minimum overjet of 5mm, ANB angle greater than 4 degrees, eruption in all permanent teeth except the third molar, orthodontic treatment completion, no history of maxillofacial surgery and growth modification treatment as well as subjects receiving comprehensive orthodontic treatment with fixed labial 0.022- inch slot size MBT appliances in both arches and having successful orthodontic treatment completion including an overbite between 10% and 25%, having a Class I canine relationship in addition to the interdigitated and well-aligned arches.

The cephalograms taken from the pre- and post-treatment examination were imported into Dolphin Imaging software (Version 11.5; Dolphin Imaging & Management Solutions, Chatsworth, CA, USA). All landmarks were digitally traced using landmark identification. Before comparison, the magnification factors were corrected. Dolphin Imaging software was used for all measurements. Tracing and digitizing all cephalograms were performed by one operator. In non-extraction group, once all teeth were aligned, ideal

0.019×0.025-inch archwires were inserted. Class II elastics were applied to reach a Class I dental relationship and no patient treated with either functional appliances or orthognathic surgery. Patients with Class II deep bite were treated using stainless steel with accentuated and reversed curve of Spee.

The variables measured from the lateral cephalograms are shown in table 1. To test intra-examiner repeatability, 30 cephalograms were randomly chosen and traced by the same examiner 2 weeks after the first evaluation. Dahlberg formula was used to estimate measurement errors. The average measurement errors were 0.4 and 0.3 for angular and linear measurements, respectively, which were within acceptable limits.

The pre- and post-treatment changes of angles within each group and between two groups were compared through paired t-test and independent t-test, respectively. Data were statistically analyzed with SPSS 22 (IBM Corp., Armonk, NY, USA). Null hypothesis was that there was no difference between pre- and post-treatment within two groups. The statistically significant level was set at $p < 0.05$.

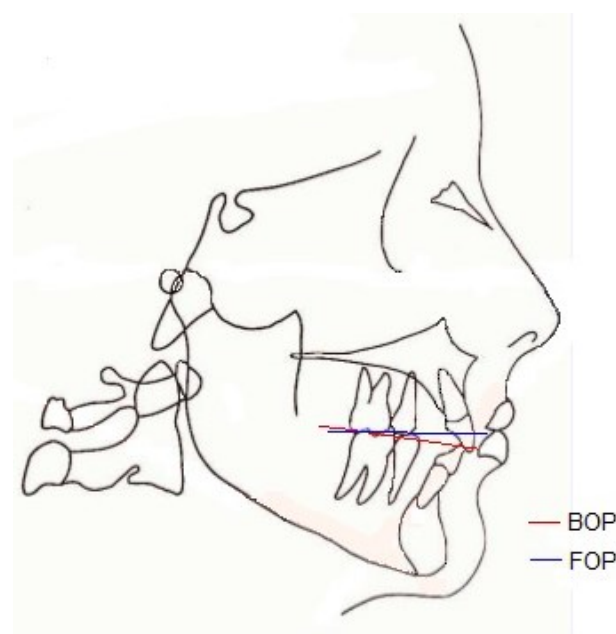


Figure 1. Reference and occlusal planes used for cephalometric measurements (refer to Table 1 for more detailed information)

Table 1. Variables measured from lateral cephalograms

<i>Variable</i>	<i>Description</i>
SNA	Angle formed by the SN plane and the Nasion-A point plane
SNB	Angle formed by the SN plane and the Nasion-B point plane
ANB	Angle between Nasion-A point plane and the Nasion-B point plane
Wits appraisal	The distance between the lines perpendicular from points A and B on to the line drawn through the overlap of the mesiobuccal cusps of the first molars and the buccal cusps of the first premolars.
PP (Palatal plane)	A line from tip of the anterior nasal spine to tip of the posterior nasal spine
MP (Mandibular plane)	A line from Go point to Me point
MP- SN (mandibular plane to SN plane angle)	Angle between Go-Me plane to SN plane
MP- OP (Mandibular plane to occlusal plane angle)	Angle between GoMe plane to OP plane
PP- OP (palatal plane to occlusal plane angle)	Angle formed by the ANS-PNS plane and the OP plane
BOP (Bisected occlusal plane)	A line drawn from bisecting the overlap of the distobuccal cusps of the first permanent molars and incisor overlap
FOP (Functional occlusal plane)	A line following the molars and premolars cusp tip
MxOP (Maxillary occlusal plane)	A line drawn from upper central incisors to the midpoint of the upper first molar on the occlusal surface
MnOP (Mandibular occlusal plane)	A line drawn from lower central incisors to the midpoint of the upper first molar on the occlusal surface
U1- SN	The posterior-inferior angle formed by the long axis of the U1 and the SN plane
L1- SN	The angle formed by the long axis of the lower central incisor and the mandibular plane
Mn- Mx	Angle between MxOP and MnOP

Results

The pre- and post-treatment angular and linear measurements of extraction and non-extraction groups are listed in tables 2 and 3. The mean differences between extraction and non-extraction groups before

and after treatment are presented in tables 4 and 5. Data analysis was performed in the total sample, and no classification was made according to gender, because there were no significant differences in variables between genders.

Within groups

Table 2. Descriptive statics of variables pre- and post-treatment in extraction group

Measurement	Pre- mean± SD	Post- mean± SD	Differences mean± SD	P-value
SNA ^a	83.3(1.7)	80.9(1)	-2.3(1.3)	.00*
SNB [°]	78(1.9)	78.1(1.1)	0.1(1.8)	.71
ANB [°]	5.2(.8)	2.7(1.1)	-2.5(1.1)	.00*
Wits	4.2(.7)	2.5(.8)	-1.7(0.5)	.00*
Mn- OP [°]	19.2(3.9)	19.2(3.4)	0.0(2.8)	.93
PP- OP [°]	12.5(1.5)	13(2.1)	0.5(1.2)	.06
MP- SN [°]	34.2(4.2)	36.5(4.1)	2.2(1.4)	.00*
FOP- SN [°]	19.5(3)	20(3.1)	0.5(1.6)	.15
BOP- SN [°]	17.1(4.4)	17.9(3.9)	0.8(1.9)	.08
U1- SN [°]	108.3(3.6)	103(2.6)	-5.3(4.5)	.00*
L1- SN [°]	45.2(2.4)	45(3)	-0.2(3.8)	.86
Mx- Mn [°]	4.9(.7)	4.4(1.5)	-0.5(1.5)	.12

^a“°” Represents the unit of angle measurement “degree” * By paired t-test

Table 3. Descriptive statics of variables pre- and post-treatment in non-extraction group

Measurement	Pre- mean± SD	Post- mean± SD	Differences mean± SD	P-value
SNA ^a	81.3(2.8)	80.6(2)	-0.7(1.3)	.02*
SNB ^o	76.6(2.6)	78.1(1.8)	1.4(1.6)	.00*
ANB ^o	4.8(.7)	2.5(1)	-2.3(0.92)	.00*
Wits	3.4(1.3)	2.1(1.3)	-1.3(0.92)	.00*
Mn- OP ^o	18.8(3.2)	18.7(3)	-0.1(1.4)	.65
PP- OP ^o	11(3)	11.9(2.6)	0.9(1.8)	.04*
MP- SN ^o	31.5(5.1)	32.3(5.1)	0.7(1.9)	.10
FOP- SN ^o	16.9(1.6)	17.5(2.5)	0.5(1.9)	.22
BOP- SN ^o	16.1(1.3)	15.3(2.4)	-0.8(1.8)	.06
U1- SN ^o	105.4(3.5)	105.4(2.3)	-0.0(3.2)	.83
L1- SN ^o	46.4(3.9)	48.1(3.5)	1.7(2.2)	.00*
Mx- Mn ^o	6.6(2.3)	5.1(1.3)	-1.5(2.3)	.01*

^a°” Represents the unit of angle measurement “degree” * By paired t-test

After treatment, the SNA angle decreased 2.3° with increasing the SNB angle 0.1°. The ANB angle decreased 2.5° and Wits appraisal was decreased 1.7 degrees. The changes of SNA, ANB angles and Wits appraisal value were statistically significant ($p < 0.05$). After treatment, the angle between mandibular and occlusal planes remained approximately the same. There was no statistically significant difference in PP-OP angle before and after treatment. The MP-SN angle statistically significantly elevated 2.2°. The angle between mandibular and SN planes enhanced statistically significantly ($p < 0.05$). The inclination of FOP and BOP increased 0.5° and 0.8°, respectively. The inclination of U1 and L1 (U1- SN and L1- SN angles) reduced 5.3° and 0.2°, respectively. The results were not statistically significant ($p > 0.05$). The angle between mandibular and maxillary planes declined 0.5° ($p > 0.05$)

B) Non-extraction group: The SNA angle decreased 0.7°, the SNB angle increased 1.4°, the ANB angle reduced 2.3° and Wits appraisal value decreased 1.3 mm. The changes of all angles were statistically significant ($p < 0.05$). After treatment, the Mn- OP had stability. The PP-OP angle elevated 0.9°, which was statistically significant ($p < 0.05$). The Mn- SN angle increased by a mean of 0.7°, and this change was not statistically significant ($p > 0.05$). The inclination of FOP increased by a mean of 0.5 with BOP decrease of 0.8°. The changes of both angles were not statistically significant ($p > 0.05$). The angle between U1 and SN planes indicated stability. The L1-SN angle increased 1.7°, which was statistically significant ($p < 0.05$). There was a statistically significant decrease in Mx-Mn angle of 1.5° ($p < 0.05$).

Between groups

Table 4. Comparison of variables between extraction and non- extraction group before treatment

Measurement	Non-extraction mean± SD	extraction mean± SD	Differences mean± SD	p-value
SNA ^a	81.3(2.8)	83.3(1.7)	2	.01*
SNB ^o	76.6(2.6)	78(1.9)	2	.07
ANB ^o	4.8(.7)	5.2(.8)	0.4	.13
Wits	3.4(1.3)	4.2(.7)	0.9	.02*
Mn- OP ^o	18.8(3.2)	19.2(3.9)	0.4	.72
PP- OP ^o	11(3)	12.4(1.5)	1.4	.07
MP- SN ^o	31.5(5.1)	34.2(4.2)	2.7	.07
FOP- SN ^o	16.9(1.6)	19.5(3)	-0.4	.00*
BOP- SN ^o	16.1(1.3)	17.1(4.4)	1	.34
U1- SN ^o	105.6(3.5)	108(3.6)	2.4	.02*
L1- SN ^o	46.4(3.9)	45.2(2.4)	-1.2	.25
Mx- Mn ^o	6.6(2.3)	4.9(.7)	-1.7	.00*

^a°” Represents the unit of angle measurement “degree” * By independent t-test

Table 5. Comparison of variables between extraction and non-extraction group after treatment

Measurement	Non-extraction mean± SD	Extraction mean± SD	Differences mean± SD	p-value
SNA ^a	80.6(2)	80.9(1)	0.3	.50
SNB°	78.1(1.8)	78.1(1.1)	0	.92
ANB°	2.5(1)	2.7(1.1)	0.2	.46
Wits	2.1(1.3)	2.5(.8)	0.4	.33
Mn- OP°	18.7(3)	19.2(3.4)	0.5	.62
PP- OP°	11.9(2.6)	13(2.1)	1.1	.15
MP- SN°	32.3(5.1)	36.5(4.1)	4.2	.00*
FOP- SN°	17.5(2.5)	20(3.1)	2.5	.00*
BOP- SN°	15.3(2.4)	17.9(3.9)	2.6	.01*
U1- SN°	105.4(2.3)	103(2.6)	-2.4	.00*
L1- SN°	48.1(3.5)	45(3)	2.9	.00*
Mx- Mn°	5.1(1.3)	4.4(1.5)	0.7	.11

^a“°” Represents the unit of angle measurement “degree” * By independent t-test

A) Before treatment: Comparison of the pre-treatment measurements of extraction and non-extraction groups suggested that the SNA angle in non-extraction group was approximately normal, while it was exceeded in extraction group. The mean difference was statistically significant ($p < 0.05$). The SNB and ANB angles as well as Wits appraisal value in non-extraction group were lesser than those in extraction group. There were no statistically significant differences in SNB and ANB angles between extraction and non-extraction groups before treatment ($p > 0.05$), but comparison of Wits appraisal value between two groups represented statistically significant difference ($p < 0.05$).

The PP-OP and Mn-OP angles were greater in extraction group than non-extraction one. The two groups had no statistically significant differences in both angles before treatment ($p > 0.05$). Before treatment, the inclination of FOP was statistically steeper in extraction group than non-extraction group ($p < 0.05$). Although BOP inclination was steeper in extraction group compared to non-extraction one, no statistically significant difference was found ($p > 0.05$). The angulation of U1 to SN plane was statistically significantly greater in extraction group than non-extraction one ($p < 0.05$). The angle between L1 and SN plane was lesser in extraction compared to non-extraction groups with no statistically significant differences ($p > 0.05$). The angle between Mx- OP and Mn- OP lines was significantly lesser in extraction subjects than non-extraction ones ($p < 0.05$).

B) After treatment: Comparison of post-treatment SNA, SNB, ANB angles and Wits appraisal value of

extraction and non-extraction groups illustrated no statistically significant difference among two groups ($p > 0.05$). Although after orthodontic therapy, extraction subjects compared to non-extraction ones indicated greater PP-OP and Mn-OP angles, there were no statistically significant differences ($p > 0.05$). The inclination of FOP and BOP was statistically significantly steeper in extraction group compared to non-extraction one ($p < 0.05$). In extraction group, U1 to SN angle was statistically significantly lesser than that in non-extraction group ($p < 0.05$). After orthodontic treatment, L1-SN angle was significantly greater in non-extraction group than extraction one ($p < 0.05$). Although Mx-Mn angle in non-extraction group was greater than that in extraction one, no statistically significant difference between these two groups was observed ($p > 0.05$).

Discussion

In the present study, the inclination of occlusal plane and some dental/skeletal variables were compared in Class II division 1 patients treated with non-extraction and upper first premolar extraction protocol. In the current study, the range of age was 16-25 years at the baseline of treatment. It is found that the differences in craniofacial measures are made early in life. [10-12] Therefore, the influence of skeletal maturity and residual growth is not so important. In the ongoing study, the angles of SNA, SNB, ANB and MP- SN were evaluated to indicate the effect of both growth and orthodontic treatment on the position of jaws in sagittal

plane. The comparison of these angles between two groups before treatment revealed that the upper premolar extraction protocol was mainly accomplished in cases with maxillary prognathism, whereas non-extraction treatment was done in individuals with mandibular retrognathism.

By comparing the difference within each group, the significant changes of SNA, ANB angles and Wits appraisal value were found in extraction group, with the reduction of SNA and ANB angles to 2.3° and 2.4° , respectively, and Wits appraisal value to 1.7 mm ($p < 0.05$). The changes of SNA, SNB and ANB angles indicated therapeutic response as well as skeletal maturity effect, and facial balance improved in these subjects. In the current study, it was observed that after orthodontic treatment, the angulation between mandibular and SN planes in non-extraction cases remained nearly the same, while it increased in extraction group, which agrees with the report of Ochoa et al. and Ye et al. [13,14]

They concluded that the association between MP-SN reduction and OP canting could be interpreted by hinge structure of the temporomandibular joint. In the forward rotation of mandible, the vertical dimension of the arch located anterior to the hinge should be lessened to establish the space for rotation. The vertical maintenance of molars and their mesial movement during the orthodontic treatment enhance the distance from the fulcrum to the hinge by means of the wedge effect. [14] Increment of the Mn- SN angulation might be as a result of the molars extrusive movement, which occurs concurrent with space closure. [15] Mn- OP and PP- OP planes had no significantly change after orthodontic treatment in both groups ($p > 0.05$). According to Tanaka et al., the MP and OP tend to rotate forward with age, accompanied by simultaneous reduction of MP- SN, OP- SN and MP-OP during growth. [7] Unlike Tanaka et al., we found that the MP-OP increased, which could be interpreted as a result of clockwise rotation of the OP, and consequently steepening of MP. [7] The patients of this study have had growth potential so that the use of Class II elastics completely eliminates typical growth-induced decrease in inclination of OP and MP. [16]

In the present study, it was found that after treatment, the BOP increased in extraction group, but decreased in non-extraction group, which might be due to the upper incisor extrusion, culminating in increased overbite in extraction group. Before and after

orthodontic treatment in both groups, the inclination of FOP was greater than that of BOP, which is consistent with the finding of Li et al. [9] The FOP represented a structural limitation of jaw movement and all masticatory forces were focused on this plane. If the inclination of this plane changed significantly, it would revert to its original position and the relapse would occur. [17] Orthodontic treatment improved the occlusal relationship of Class II subjects, but BOP and FOP became steeper. An explanation for these changes would be due to the extrusion of lower molars and upper incisors by Class II treatment mechanics as well as the residual vertical growth. [15] The Class II elastics occasionally used to correct a Class II malocclusion could lead to the extrusion of mandibular molars and maxillary incisors, and consequently elevate the angulation of BOP and FOP as well as could exaggerate the mandibular plane slope, especially in extraction group after treatment. [18] The FOP illustrated a structural limitation of mandibular movement and all masticatory forces were centered on this plane. If the FOP inclination changes significantly during treatment, it reverts to its previous position and the relapse occurs. Although comparison the FOP before and after treatment between two groups revealed significant changes, no statistically significant changes in FOP inclination were found before and after treatment within each group, which could be considered as an important factor in post-treatment stability. The U1-SN angle significantly reduced in the extraction group owing to retraction of upper anterior teeth into the extracted premolar space, commonly used Class II division 1 treatment protocol [19], which is compatible with the findings of Janson et al. and Ciger et al. [20,21] After treatment, the angulation between L1 and SN plane in extraction group had no significant change; however, it significantly elevated in non-extraction group, indicating the occlusion improvement was greater in non-extraction subjects because of lower incisor protrusion.

In both groups, after orthodontic treatment, the cant of maxillary to mandibular OP decreased, representing that on average, the maxillary buccal teeth erupted more frequently than the mandibular molars. This result is the same as that of Tanaka et al. and Li et al. [7,9]

Conclusion

Though the use of extraction and non-extraction protocols for the treatment of Class II patients did not cause significant changes in the occlusal plane angles,

small changes in these angles can affect facial harmony and occlusal relationships. Different aspects should be considered as an appropriate treatment option for cases.

Funding: This study was a part of research project (Grant No: 95000263) supported and funded by Kerman University of Medical Sciences.

Conflict of interest: The authors declare that they have no conflict of interest.

Authors' Contribution:

The study was designed by Samaneh Sadeghi and Masumeh Darabi. Samaneh Sadeghi defined the conceptual content of the research. The study data were collected by Masumeh Darabi. Statistical analysis and interpretation of data were accomplished by Samaneh Sadeghi. Preparation of manuscript was performed by Samaneh Sadeghi.

References

- Janson G, Barros SEC, Simão TM, de Freitas MR. Relevant variables of Class II malocclusion treatment. *Dent Press Ortodon Ortop Facial* 2009; 14:149-57.
- Janson G, Valarelli DP, Valarelli FP, de Freitas MR. Treatment times of Class II malocclusion: four premolar and non-extraction protocols. *Eur J Orthod* 2012; 34:182-7.
- Gianelly AA. Arch width after extraction and nonextraction treatment. *Am J Orthod Dentofacial Orthop* 2003;123:25- 8.
- Paquette DE, Beattie JR, Johnston LE Jr. A long-term comparison of nonextraction and premolar extraction edgewise therapy in "borderline" Class II patients. . *Am J Orthod Dentofacial Orthop* 1992;102:1-14.
- Bishara SE, Cummins DM, Zaher AR. Treatment and posttreatment changes in patients with Class II, Division 1 malocclusion after extraction and nonextraction treatment. *Am J Orthod Dentofacial Orthop*1997;111:18-27.
- Bishara SE. Class II Malocclusions: Diagnostic and Clinical Considerations With and Without Treatment. *Semi Orthod* 2006; 12: 11-24.
- Tanaka EM, Sato S. Longitudinal alteration of the occlusal plane and development of different dentoskeletal frames during growth. *Am J Orthod Dentofacial Orthop* 2008;134:602.
- Kim JY, Lee SJ, Kim TW, Nahm DS, Chang Y. Classification of the skeletal variation in normal occlusion. *Angle Orthod* 2005; 75:311-9.
- Li JL, Kau C, Wang M. Changes of occlusal plane inclination after orthodontic treatment in different dentoskeletal frames. *Prog Orthod*. 2014; 15: 41.
- Perillo L, Femiano A, Palumbo S, Contardo L, Perinetti G. Skeletal and dental effects produced by functional regulator-2 in pre-pubertal class II patients: a controlled study. *Prog Orthod* 2013; 14:18.
- Bushing PH, Tanguay R, Demirjian A, LaPalme L, Turkewicz J. Mathematical models of longitudinal mandibular growth for children with normal and untreated Class II, division 1 malocclusion. *Eur J Orthod* 1988; 10:227-34.
- Baccetti T, Franchi L, McNamara JA Jr, Tollaro I. Early dentofacial features of Class II malocclusion: a longitudinal study from the deciduous through the mixed dentition. *Am J Orthod Dentofacial Orthop* 1997; 111:502-9.
- Ochoa BK, Nanda RS. Comparison of maxillary and mandibular growth. *Am J Orthod Dentofacial Orthop* 2004; 125:148–59.
- Ye R, Li Y, Li X, Li J, Wang J, Zhao S, et al. Occlusal plane canting reduction accompanies mandibular counterclockwise rotation in camouflaging treatment of hyperdivergent skeletal Class II malocclusion. *Angle Orthod* 2013;83:758-65.
- Fushima K, Kitamura Y, Mita H, Sato S, Suzuki Y, Kim YH. Significance of the cant of the posterior occlusal plane in Class II Division 1 malocclusions. *Eur J Orthod* 1996; 18: 27–40.
- Zimmer B, Nischwitz D. Therapeutic changes in the occlusal plane inclination using intermaxillary elastics. *Orofac Orthop* 2012; 73:377-86.
- Tovstein BC. Behavior of the occlusal plane and related structures in the treatment of class II malocclusion. *Angle Orthod*1955; 25:189–98.
- Lamarque S. The importance of occlusal plane control during orthodontic mechanotherapy. *Am J Orthod Dentofacial Orthop* 1995;107:548-58.
- Janson G, Barros SE, de Freitas MR, Henriques JF, Pinzan A. Class II treatment efficiency in maxillary premolar extraction and nonextraction protocols. *Am J Orthod Dentofacial Orthop*. 2007; 132:490-8.

20. Janson G, Mendes LM, Junqueira CH, Garib DG. Soft-tissue changes in Class II malocclusion patients treated with extractions: a systematic review. *Eur J Orthod* 2016; 38:631-37.
21. Ciger S, Aksu M, Germeç D. Evaluation of posttreatment changes in Class II Division 1 patients after nonextraction orthodontic treatment: cephalometric and model analysis. *Am J Orthod Dentofacial Orthop* 2005; 127:219-23.