

A comparative evaluation of cone-beam computed tomography and multi-slice computed tomography in the diagnosis of sheep mandibular bone defect: an in vitro study

Ehsan Moudi^{1✉}, Sina Haghanifar¹, Kave Kazemian², Ramin Foroughi³, Mehrdad Nabahati⁴
Ali Bijani⁵

1. Associate Professor, Dental Materials Research Center, Health Research Institute, Babol University of Medical Sciences, Babol, IR Iran.
2. Postgraduate Student, Student Research Committee, Babol University of Medical Sciences, Babol, IR Iran.
3. Assistant Professor, Oral Health Research Center, Health Research Institute, Babol University of Medical Sciences, Babol, IR Iran.
4. Assistant Professor, Clinical Research Development Center, Shahid Beheshti Hospital, Babol University of Medical Sciences, Babol, IR Iran.
5. Assistant Professor, Social Determinants of Health Research Center, Health Research Institute, Babol University of Medical Sciences, Babol, IR Iran.

✉ **Corresponding Author:** Ehsan Moudi, Faculty of Dentistry, Babol University of Medical Sciences, Babol, IR Iran.

Email: e. moudi@mubabol.ac.ir

Tel: +98 1132291408 **ORCID** (0000-0001-7226-5305)

Received: 16 Sept 2017

Accepted: 16 Sept 2018

Abstract

Introduction: Diagnosis of lesions and bone defects is very important and there is a lack of substantial studies on the most appropriate method for bone defect measurement. Hence, the aim of this study is to evaluate the accuracy of multi-slice computed tomography (MSCT) and cone-beam computed tomography (CBCT) in the diagnosis of mandibular bone defects present in sheep.

Material & Methods: This in vitro study was performed on 15 sheep's mandibular bones. Some defects were created in cortical and spongy bone using high-speed hand piece at the buccal and lingual cortical bone of the lower jaw. Totally, 75 mandibular bone defects with a depth of 1-3 mm were created. The mandibular bone samples were scanned using MSCT and CBCT scanners, and these scans were evaluated by two oral and maxillofacial radiologists. The positive and negative predictive values, sensitivity and specificity were calculated for both methods.

Results: The sensitivity of MSCT and CBCT were 78% and 96.5%, and Specificity of MSCT and CBCT were 90% and 92% respectively. The positive and negative predictive values were 97.5% and 89.5 % for CBCT, and 90% and 92% for MSC respectively. The negative and positive likelihood ratios (LR-) and (LR+) were 0.035 and 13.04 for CBCT as well as 0.245 and 7.82 for MSC respectively.

Conclusion: The study results demonstrated a higher accuracy of CBCT, compared to MSCT, in the diagnosis of bone defects.

Keywords: Bone, Cone-beam computed tomography, Diagnosis, Mandible

Citation for article: Moudi E, Haghanifar S, Kazemian K, Foroughi R, Nabahati M, Bijani A. A comparative evaluation of cone-beam computed tomography and multi-slice computed tomography in the diagnosis of sheep mandibular bone defect: an in vitro study. Caspian J Dent Res 2018; 7:24-9.

مقایسه توموگرافی کامپیوتری با اشعه مخروطی و برش چندگانه در تشخیص نواقص استخوانی ایجاد شده در فک پایین گوسفند: بررسی آزمایشگاهی

احسان موعودی^{۱*}، سینا حقانی فر^۱، کاوه کاظمیان^۲، رامین فروغی^۳، مهرداد نباهتی^۴، علی بیژنی^۵

۱. دانشیار، مرکز تحقیقات مواد دندان، پژوهشکده سلامت، دانشگاه علوم پزشکی بابل، بابل، ایران.

۲. دانشجوی دستیاری، کمیته تحقیقات دانشجویی، دانشگاه علوم پزشکی بابل، بابل، ایران.

۳. استادیار، مرکز تحقیقات سلامت و بهداشت دهان، پژوهشکده سلامت، دانشگاه علوم پزشکی بابل، بابل، ایران.

۴. استادیار، واحد توسعه تحقیقات بیمارستان شهید بهشتی، دانشگاه علوم پزشکی بابل، بابل، ایران.

۵. استادیار، مرکز تحقیقات عوامل اجتماعی موثر بر سلامت، پژوهشکده سلامت، دانشگاه علوم پزشکی بابل، بابل، ایران.

* نویسنده مسئول: احسان موعودی، دانشکده دندانپزشکی، دانشگاه علوم پزشکی بابل، بابل، ایران.

پست الکترونیکی: e. moudi@mubabol.ac.ir: تلفن: +۹۸ ۱۱۳۲۲۹۱۴۰۸

چکیده

مقدمه: با توجه به اینکه تشخیص ضایعات یا نواقص استخوانی از اهمیت بالایی برخوردار است و مطالعات کمی در زمینه در مورد مناسبترین متد جهت اندازه‌گیری نواقص استخوانی وجود دارد بنابراین، هدف از این مطالعه بررسی دقت cone beam-computed tomography (CBCT) و multi slice computed tomography (MSCT) در تشخیص نقایص استخوانی ایجاد شده در استخوان فک پایین گوسفند می‌باشد.

مواد و روش‌ها: این مطالعه آزمایشگاهی بر روی ۱۵ استخوان فک پایین گوسفند انجام شد. نقایصی در استخوان کورتیکال و اسفنجی توسط فرزهای گرد با هندپیس دور بالا در سطوح کورتیکال باکال و لینگوآل استخوان فک پایین ایجاد گردید. در مجموع ۷۵ نقص استخوان‌های فک پایین که عمقی معادل ۱ الی ۳ میلی‌متر داشتند، ایجاد شدند. نمونه‌ها توسط ۲ دستگاه MSCT و CBCT تصویر برداری شده و تصاویر توسط دو رادیولوژیست دهان و فک و صورت مورد ارزیابی قرار گرفتند. حساسیت، ویژگی، ارزش اخباری مثبت و منفی برای هر دو روش محاسبه شد.

یافته‌ها: در این مطالعه حساسیت CBCT و MSCT به ترتیب ۹۶/۵٪ و ۷۸٪ و ویژگی ۹۲٪ و ۹۰٪ مشاهده گردید. ارزش اخباری مثبت و منفی برای CBCT برابر با ۸۹/۵٪ و ۹۷/۵٪ و برای MSCT مساوی با ۸۵٪ و ۸۵/۵٪ گزارش شد. LR+ و Likelihood Ratio (LR-) برای CBCT ۱۳/۰۴ و ۰/۰۳۵ و برای MSCT ۷/۸۲ و ۰/۲۴۵ بوده است.

نتیجه‌گیری: نتایج حاصل از مطالعه حاضر نشان داد که CBCT دقت بالا تری نسبت به MSCT در تشخیص نواقص استخوانی دارد.

واژگان کلیدی: استخوان، توموگرافی کامپیوتری با اشعه مخروطی، تشخیص، فک پایین

Introduction

The use of various computed tomography (CT) scans for the evaluation of oral and dental diseases is increasing. This diagnostic method resulted in the creation of high-resolution images, and it has become one of the most widely used devices due to being highly applicable in different anatomical regions.^[1] A cone-beam computed tomography (CBCT) technique is a common imaging method in dentistry that is capable of

producing images with a resolution of less than 1 mm in size and high detection capability.^[2] Computerized tomography with multiple cutting is capable of producing images of pathologic changes in the bone surface by creating multiple-thin and overlapping cuts.^[3] In order to overcome the limitations of the general application of multi-slice computed tomography (MSCT), volumetric tomography systems have been

introduced for maxillofacial applications based on the idea of CBCT. [4] In addition, shorter scan time and radiation dose reduction are further advantages of CBCT over MSCT. [5] Several studies have focused on the evaluation and comparison of different CBCT devices and MSCT technology. [1-4, 6-9] Today, there are few studies on appropriate methods to choose the most accurate computed tomography in the diagnosis of the bone defects. The aim of this study is to compare the accuracy of MSCT and CBCT in the diagnosis of bone defects created in the sheep mandible.

Materials & Methods

This in vitro study was performed on 15 dry mandibles of sheep. Totally, 75 mandibular bone defects were created. First, the bones were immersed in 0.5% formalin solution for 10 days. Then, the soft tissue was dissected by a cutter (surgical blade NO.15). Defects were created in cortical and spongy bone using round burs 0.5, 1 (Switzerland, Juta) and a high-speed hand piece (NSK, Tokyo JAPAN). This procedure led to defects with different sizes and shapes on buccal and lingual cortical bone of the mandible. In some cases, bur only reached the cortical bone, and in other cases, it even penetrated into the cancellous bone. Totally, 75 mandibular bone defects were created with a depth of 1-3 mm and measured using Williams probe (Hu-Friedy, Chicago IL, USA). Seven and five samples had unilocular and multilocular defects respectively, while three were flawless. Multilocular defects had two or three holes.

The dry sheep mandibles were completely covered by thin layers of wax (Betadent-Iran) to simulate the soft tissue layers and were placed in the standard condition in the CBCT and MSCT devices. Required axial scans were taken from the mandibular bone to the condyle. In addition, the gantry angle varied according to the angle of the mandibular bone (Figures 1-4).

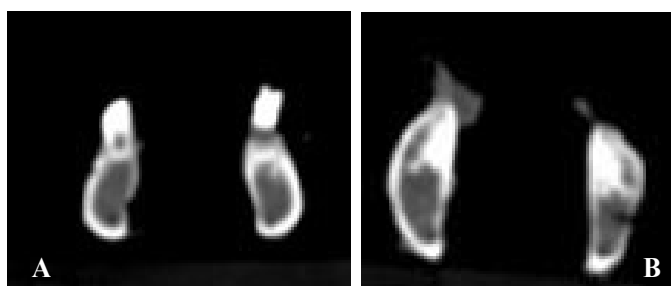


Figure 1. MSCT images of buccal (A) and lingual (B) bone defects

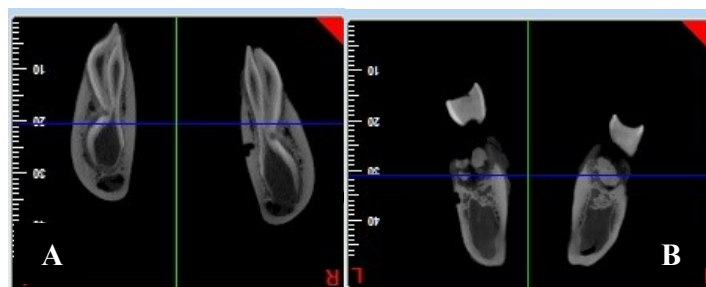


Figure 2. CBCT images of buccal (A) and lingual (B) bone defects

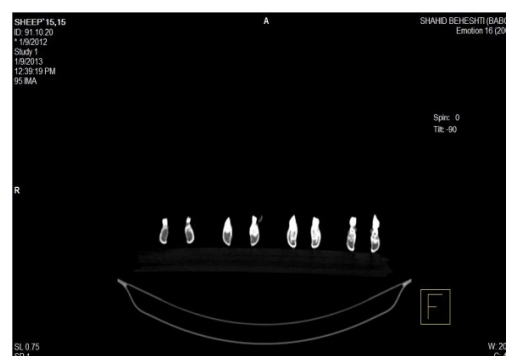


Figure 3. Placement of the mandibular bones of sheep in the MSCT devices

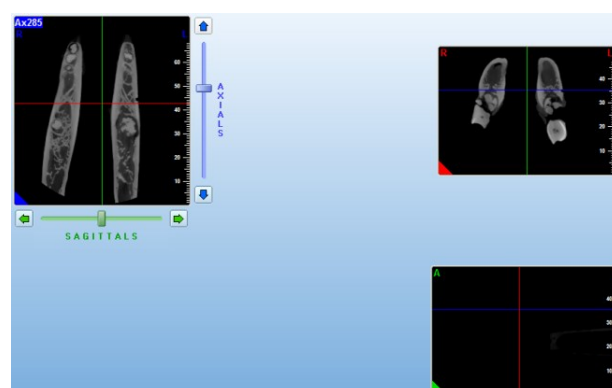


Figure 4. Evaluation of mandibular bone defects in sheep on MPR plane in the CBCT device

The mandibular bone was investigated under the following conditions: For the CBCT scanner (Newtom 5 G, Verona, Italy): Scanning Time = 15s, Voxel Size = 75 μ m, FOV = 16*18, mA = 1-20 mA, KVP=110

For the MSCT devices (16 slice Somatom Sensation, Siemens Germany): Collimation = 0.6, Rotation = 600 ms, Pitch = 0.75, Option = H70s/H60s, KVP 120, mA 90, Scanning Time = 20s, Pixel resolution = 0.28/0.48.

The original data was extracted from MSCT via Signora Software, and from CBCT by NNT Viewer software. The axial and cross-sectional planes were extracted by two softwares in these devices. CBCT images were observed in a dim room by brilliance 225B

LCD monitor with the resolution of 0.282*0.282 mm, while MSCT images were observed by Fujitsu B19-6 LED with 0.294 mm pixel. The observers including two oral maxillofacial radiologists were separately asked to determine different features of the cavities. These features include unilocularity and multilocularity in three planes of axial, coronal and multiplanar reconstruction (MPR), and the presence or absence of defects in each plane. During the analysis of the images on the screen, only one of the protocols was shown to the interactive effects on observers' interpretation. The general consensus between observers was measured by KAPPA coefficient according to the gold standard. SPSS 20 and chi-square test were used to calculate the sensitivity, specificity as well as positive and negative predictive values of final correct ratios with 95% CI.

Results

In this study, the observers had an agreement in comparison between CBCT and MSCT for diagnosis of defects on the buccal and lingual surfaces (Table 1). Another interesting point was the ability to detect various sizes of defects by both devices (Table 2).

Table 1. KAPPA coefficient of two observers in MSCT and CBCT on the buccal and lingual surfaces

Device	CBCT		MSCT	
	Observer 1	Observer 2	Observer1	Observer2
Right	0.889±0.48	0.933±0.38	0.646±0.079	0.589±0.083
Left	0.810±0.63	0.850±0.59	0.750±0.74	0.781±0.069

Table 2. The ability to accurately detect various sizes of defects by observers by MSCT and CBCT

Device	CBCT		MSCT	
	Observer1	Observer2	Observer 1	Observer2
Size(mm)				
1	91.3%	91.3%	43.5%	47.8%
2	95.5%	100%	86.4%	81.8%
3	100%	100%	96.7%	100%

In this study, the mean sensitivity was 78% and 96.5%. and the mean specificity for MSCT and CBCT is 90% and 92% respectively. The mean for positive and negative predictive values are 97.5% and 89.5% for CBCT, and 85% and 85.5% for MSCT respectively. The mean of negative and positive likelihood ratios (LR-) and (LR+) were 0.035 and 13.04 for CBCT, and 0.245 and 7.82 for MSCT (Table 3) respectively.

Table 3. Indices of diagnostic test accuracy for CBCT and MSCT by observers

	CBCT		MSCT	
	Observer 1	Observer 2	Observer 1	Observer 2
Sensitivity (CI95%)	%97 (%94-%100)	%96 (%92-%100)	%79 (%69-%88)	%77 (%68-%87)
Specificity (CI95%)	%90 (%84-%95)	%94 (%90-%99)	%90 (%85-%96)	%90 (%84-%95)
PPV ¹ (CI95%)	%87 (%80-%94)	%92 (%86-%98)	%86 (%77-%94)	%84 (%75-%93)
NPV ² (CI95%)	%98 (%95-%100)	%97 (%94-%100)	%86 (%79-%92)	%85 (%78-%91)
LR ⁺ (CI95%)	9.29 (5.30-16.27)	16.80 (7.71-36.59)	8.26 (4.53-13.07)	7.38 (4.16-13.08)
LR ⁻ (CI95%)	0.03 (0.01-0.12)	0.04 (0.01 (0.01-0.13)	0.24 (0.15-0.37)	0.25 (0.17-0.39)
Kappa±SE	0.85±0.04	0.90±0.03	0.70±0.05	0.68±0.06
Pvalue	<0.001	<0.001	<0.001	<0.001

1. PPV: Positive predictive value

2. NPV: Negative Predictive value

3. LR+: Likelihood Ratio+

4. LR-: Likelihood Ratio -

Discussion

The results of this study demonstrated higher sensitivity but similar specificity of CBCT compared to MSCT. In the present study, the diagnostic capability of CBCT device for the defects with a depth of 1 mm was more than that of MSCT device. By increasing the diameter to 2 mm, the diagnostic capability of MSCT increases and gets closer to that of CBCT. This trend for defects continues up to 3 mm depth; however, the diagnostic capability of MSCT will still be less than that

of CBCT. Perella et al. (2007) investigated and compared two protocols with different thickness in a MSCT 16 Slice and concluded that the helical CT had a low sensitivity (72% in protocol 1 and 50% in protocol 2) and high specificity (97%, 99%) in the diagnosis of bone defects smaller than 1mm.^[10] This is consistent with our finding. Other studies have also suggested the lower sensitivity and higher specificity of MSCT 16 Slice compared to CBCT for detecting bone defects.

[2,8,9, 11] Van Cann et al. (2008) compared MSCT and several other imaging modalities for evaluation of small cancer-micro-induced bone destructions in mandibular and reported 58% of sensitivity and 95.7% of specificity for MSCT. [12] Dreiseidler et al. (2011) [7] indicated that both MSCT and CBCT are capable of diagnosis of small bony encroachment on average malignant lesions. The reported sensitivity and specificity were 0.92% and 0.96% for CBCT Galileos, and 0.8% and 100% for MSCT 16, respectively. These results are in agreement with those of our current study. However, in contrast to the present study in which CBCT showed a slightly higher specificity compared to MSCT, the study of Dreiseidler et al. represented higher specificity for MSCT (1 vs. 90%). [7] This may be due to the smaller voxel size of CBCT in our study.

In a study (2008), Van Cann et al. illustrated that the CBCT compared to MSCT had better performance in the diagnosis of periapical defects and their differentiation from bone destruction caused by malignant tumors. Although this study reported that the use of CBCT may avoid unnecessary tests like single photon emission computed tomography (SPECT) and magnetic resonance imaging (MRI), [12] Jones et al. showed that CBCT images may be less reliable and accurate for the diagnosis of small defects. [13]

In our study, the positive and negative predictive values of CBCT more than those of MSCT for both observers. These findings are consistent with those of Dreiseidler et al. [7] which demonstrated higher accuracy of diagnosis using CBCT.

The higher sensitivity of CBCT in the present study goes against the results of Gaia et al. [2] who reported similar sensitivity and specificity for MSCT and CBCT. They compared CBCT i-CAT and MSCT Aquiline 64 in two para-sagittal and MPR/axial sections and no significant difference was found between the devices. This may be due to the voxel size of 0.25 mm of CBCT device in Gaia et al.'s study [2] compared to that of 75µm in the present study. Another possible reason for this contradiction can be due to the difference between thickness of slices in MSCT16 slice Somatom and Aquiline 64 Slice.

Conclusion

The results of this study have demonstrated that CBCT and MSCT have almost the same specificity; however, CBCT has higher sensitivity compared to

MSCT. Specifically, CBCT has higher sensitivity and specificity compared to MSCT for defects with a depth of less than 0.5 mm. Moreover, MSCT diagnostic capability increases for defects of higher depth. Overall, the use of CBCT has priority over MSCT.

Acknowledgements

We are thankful to the staff of Oral and Maxillofacial Radiology Department in Babol University of Medical Sciences for their cooperation.

Funding: This study was a part of research project (Grant No: 9135016) which was supported and funded by Babol University of Medical Sciences.

Conflict of interest disclosure: There is no conflict of interests.

Authors' Contributions

The study was designed by Ehsan Moudi and Sina Hghanifar. The study data was collected by Kaveh Kazemian. Analysis and interpretation of data were conducted by Ramin Foroughi and Mehrdad Nabahati. Drafting of the manuscript, and critical revision of the manuscript for important intellectual content were performed by Ehsan Moudi, Kaveh Kazemian and Ramin Foroughi. Study supervision was conducted by Ehsan Moudi and Sina Hghanifar and statistical analysis by Ali Bijani.

References

1. Mahesh M. Search for isotropic resolution in CT from conventional through multiple-row detector. *Radiographics* 2002;22:949-62.
2. Gaia BF, Sales MA, Perrella A, Fenyo-Pereira M, Cavalcanti MG. Comparison between cone-beam and multislice computed tomography for identification of simulated bone lesions. *Braz Oral Res* 2011;25:362-8.
3. Liang X, Jacobs R, Hassan B, Li L, Pauwels R, Corpas L, et al. A comparative evaluation of Cone Beam Computed Tomography (CBCT) and Multi-Slice CT (MSCT) Part I. On subjective image quality. *Eur J Radiol* 2010;75:265-9.
4. Al-Ekrish A A, Ekram M. A comparative study of the accuracy and reliability of multidetector CT and

- cone beam CT in the assessment of dental implant site dimensions: Author response. *Dentomaxillofac Radiol* 2011; 40: 468–9.
5. Scarfe WC, Farman AG, Sukovic P. Clinical applications of cone-beam computed tomography in dental practice. *J Can Dent Assoc* 2006;72:75-80.
 6. Heiland M, Schulze D, Rother U, Schmelzle R. Postoperative imaging of zygomaticomaxillary complex fractures using digital volume tomography. *J Oral Maxillofac Surg* 2004;62:1387-91.
 7. Dreiseidler T, Alarabi N, Ritter L, Rothamel D, Scheer M, Zöller JE, et al. A comparison of multislice computerized tomography, cone-beam computerized tomography, and single photon emission computerized tomography for the assessment of bone invasion by oral malignancies. *Oral Surg Oral Med Oral Pathol Oral Radiol Endod* 2011;112:367-74.
 8. Doyle S, Wiltz MJ, Kraut RA. Comparison of Cone-beam Computed Tomography and Multi-slice Spiral Computed Tomography Bone Density Measurements in the Maxilla and Mandible. *N Y State Dent J* 2015;81:42-5.
 9. Saati S, Kaveh F, Yarmohammadi S. Comparison of cone beam computed tomography and multi slice computed tomography image quality of human dried mandible using 10 anatomical landmarks. *J Clin Diagn Res* 2017; 11: ZC13–ZC6.
 10. Perrella A, Borsatti MA, Tortamano IP, Rocha RG, Cavalcanti MG. Validation of computed tomography protocols for simulated mandibular lesions: a comparison study. *Braz Oral Res* 2007;21:165-9.
 11. Cara AC, Gaia BF, Perrella A, Oliveira JX, Lopes PM, Cavalcanti MG. Validity of single- and multislice CT for assessment of mandibular condyle lesions. *Dentomaxillofac Radiol* 2007;36:24-7.
 12. Van Cann EM, Koole R, Oyen WJ, de Rooy JW, de Wilde PC, Slootweg PJ, et al. Assessment of mandibular invasion of squamous cell carcinoma by various modes of imaging: constructing a diagnostic algorithm. *Int J Oral Maxillofac Surg* 2008;37:535-41.
 13. Jones EM, Papio M, Tee BC, Beck FM, Fields HW, Sun Z. Comparison of cone-beam computed tomography with multislice computed tomography in detection of small osseous condylar defects. *Am J Orthod Dentofacial Orthop* 2016;150:130-9.