Caspian J of Dent Res

Original Article

Comparative evaluation of the frequency of myofibroblasts between oral and cutaneous squamous cell carcinomas

Ali Dodani[1], Sepideh Siadati[2], Jahanshah Salehinejad[3], Karimollah Hajian-Tilaki[4], Hamid Abbaszadeh ـ Bidokhty [5]✉

1. Dental Student , Student Research Committee, Babol University of Medical Sciences, Babol, Iran.
2. Associate Professor, Department of Pathology, Faculty of Medicine, Babol University of Medical Sciences, Babol, Iran.
3. Professor, Department of Oral and Maxillofacial Pathology, Faculty of Dentistry, Mashhad University of Medical Sciences, Mashhad, Iran.
4. Professor, Department of Biostatistics and Epidemiology, Faculty of Medicine, Babol University of Medical Sciences, Babol, Iran.
5. Assistant Professor, Cellular and Molecular Biology Research Center, Department of Oral and Maxillofacial Pathology, Faculty of Dentistry , Babol University of Medical Sciences, Babol, Iran.

✉**Corresponding Author:** Hamid Abbaszadeh, Faculty of Dentistry, Babol University of Medical Sciences, Babol, Iran.
Email: **hamidabbaszade@yahoo.com** **Tel:** **+981132291093**

Received: 10 May 2016 Accepted: 17 Sept 2016

Abstract

Introduction: Differentiation of fibroblasts to myofibroblasts is an initial and very important event in tumor genesis. Myofibroblasts produce proteinases that stimulate invasion in cancers. Due to the more malignant potential of oral squamous cell carcinoma (OSCC) compared to cutaneous squamous cell carcinoma (CSCC) , the aim of the present study was to compare myofibroblasts between OSCC and CSCC to understand whether myofibroblasts can help more malignant potential of OSCC compared to CSCC or not.

Materials &Methods: This cross-sectional study included 40 cases of OSCC and CSCC and 20 cases of normal skin and normal oral mucosa. Then, 4-micron sections of paraffin-embedded tissue blocks of studied groups were stained immunohistochemically with α-SMA antibody. Mean percentage of myofibroblasts was calculated in invasive fronts of OSCCs with CSCCs and also in normal samples and staining intensity of cells for α-SMA marker and distribution pattern of myofibroblasts were determined.

Results: The differences of average percentage of myofibroblasts in OSCC and CSCC compared to normal groups were significant (P_{value}= 0.007 and P_{value}=0.003 respectively), but when we compared OSCCs and CSCCs, the difference was not significant. Also, there were no significant differences between OSCC and CSCC with regard to staining intensity and pattern.

Conclusion: Different biologic behavior of OSCC compared to CSCC doesn't depend on myofibroblasts and other factors can be involved.

Keywords: Carcinoma, Evaluation, Myofibroblasts, Squamous cells

Citation for article: Dodani A, Siadati S, Salehinejad S, Hajian-Tilaki KO, Abbaszadeh- Bidokhty H. Comparative evaluation of the frequency of myofibroblasts between oral and cutaneous squamous cell carcinomas .Caspian J Dent Res 2016;5:24-9.

[Downloaded from cjdr.ir on 2026-11-23]

[DOR: 20.1001.1.22519890.2016.5.2.4.0]

[DOI: 10.22088/cjdr.5.2.24]

ارزیابی مقایسه ای فراوانی میوفیبروبلاست ها بین کارسینوم سلول سنگفرشی دهان و پوست

علی دودانی، سپیده سیادتی، جهانشاه صالحی نژاد، کریم الله حاجیان تیلکی ، حمید عباس زاده بیدختی*

چکیده

مقدمه: تمایز فیبروبلاست به میوفیبروبلاست یک رویداد اولیه و بسیار مهم در ایجاد تومور است. میوفیبروبلاست ها پروتئینازهایی تولید میکنند که تهاجم را در کانسر ها تحریک می کنند. بدلیل پتانسیل بدخیمی بیشتر کارسینوم سلول سنگفرشی دهان (OSCC) نسبت به کارسینوم سلول سنگفرشی پوست (CSCC)، هدف از این مطالعه مقایسه میوفیبروبلاست بین OSCC و CSCC است تا دریابیم که آیا میوفیبروبلاست می توانند به پتانسیل بدخیم بیشتر OSCC در مقایسه با CSCC کمک کنند یا نه.

مواد و روش ها: این مطالعه شامل ۲۰ مورد OSCC، ۲۰ مورد CSCC، ۱۰ بافت نرمال پوست و ۱۰ مورد مخاط نرمال دهان می شود. مقاطع ۴ میکرونی از بلوک های بافتی قرار گرفته در پارافین گروه های مورد مطالعه به روش ایمونوهیستوشیمی با آنتی بادی α-SMA رنگ آمیزی شدند. میانگین درصد میوفیبروبلاست ها در جبهه تهاجمی OSCCs و CSCCs و نیز در نمونه های نرمال محاسبه شد و شدت رنگ پذیری سلول ها برای نشانگر α-SMA و الگوی توزیع میوفیبروبلاست ها تعیین شد.

یافته ها: اختلاف میانگین درصد میوفیبروبلاست در OSCC و CSCC نسبت به گروه های نرمال معنی دار بود (به ترتیب P_{value}= 0.007 ،P_{value}=0.003)، اما زمانی که ما OSCCs و CSCCs را مقایسه کردیم، تفاوت معنی دار نبود. همچنین، تفاوت معنی داری بین OSCC و CSCC به لحاظ شدت و الگوی رنگ پذیری وجود نداشت.

نتیجه گیری: تفاوت رفتار بیولوژیک OSCC در مقایسه با CSCC به میوفیبروبلاست بستگی ندارد و عوامل دیگری می توانند دخیل باشند.

واژگان کلیدی: کارسینوم، ارزیابی، میوفیبروبلاست، سلولهای سنگفرشی

Introduction

Oral squamous cell carcinoma (OSCC) is the most common oral malignancy and cutaneous squamous cell carcinoma (CSCC) is the second most common skin cancer.[1,2] In solid tumors such as oral squamous cell carcinoma, a combination of the effects of cancer cells and stromal cells (i.e. fibroblasts, endothelial cells and inflammatory cells) has been considered as being involved that in harmony with each other act towards tumor progression, angiogenesis, local invasion and metastasis.[3] Myofibroblasts are heterogeneous and multifunctional cells which show different phenotypes. Myofibroblasts are at first described in cutaneous ulcers where they contract stroma, approximate epithelial edges to each other and thus facilitate healing of ulcer. Myofibroblasts regulate stromal in physiological and pathological statuses via direct cell-cell contacts and release of matrix metalloproteinases, tissue inhibitors of matrix metalloproteinases, components of extracellular matrix growth factors, cytokines, chemokines and lipid products and via expression of specific receptors. Some of normal tissues such as gastrointestinal tract and lungs have also myofibroblasts. Beside their role in healing of ulcers, myofibroblasts are necessary for tissue morphogenesis and help to stem cell niches and mucosal immunity.[4]

Carcinoma-associated fibroblasts (CAFs) which consist of both fibroblasts and myofibroblasts are frequently observed in the stroma of human carcinomas.[4] Differentiation of fibroblasts to myofibroblasts is an initial and very important event in tumorigenesis and mediates by cytokines and growth factors expressed by tumor cells. [5] In cancers, myofibroblasts are deficient or have other functions such as production of proteinases stimulating invasion. [4] Induction of myofibroblasts by OSCC induced factors that instead stimulate carcinomatous proliferation and result in neoplastic growth, have been shown.[5] Frequency of stromal myofibroblasts is correlated with worse prognosis in oral, breast and colorectal carcinomas. [6-10] On the other hand, malignant and metastatic potential for OSCC and CSCC is different. [11] OSCC and CSCC differ in terms of their prognosis.

[Downloaded from cjdr.ir on 2026-11-23]

[DOR: 20.1001.1.22519890.2016.5.2.4.0]
[DOI: 10.22088/cjdr.5.2.24]

For OSCC, 5- year survival rate varies between 35% and 45% and the risk of metastasis varies between 40% and 50% .[12, 13] For head and neck CSCC, the risk of metastasis is 11.7% and 5-years survival is 54% .[14, 15] Therefore, the aim of the present study was to compare myofibroblasts between OSCC and CSCC, to understand whether myofibroblasts can help more malignant potential of OSCC compared to CSCC or not.

Materials&Methods

This cross-sectional study included 60 samples (including 20 low-grade OSCCs, 20 low-grade CSCCs, 10 normal oral mucosa, 10 normal skins). Then, 4-micron sections of paraffin-embedded tissue blocks of studied groups were stained immunohistochemically with α-SMA antibody (Bond™ Ready-to-Use Primary Antibody Smooth Muscle Actin (alpha sm-1) [a mouse anti-human monoclonal antibody]; Leica Biosystems, Newcastle, United Kingdom, Product Code: PA0.943 Clone: alpha sm-1, Ig Class: IgG2a) . Spindle stromal cells which indicated positive staining for alpha smooth muscle actin (α-SMA) and cytoplasmic staining were considered as myofibroblasts.[16] α-SMA$^+$ smooth muscle cells of blood vessels' wall were not considered in this calculation.[17]Percentage of myofibroblasts among stromal cells under an optical microscope at 10 successive fields in invasive fronts of OSCCs and CSCCs was calculated. At 400X magnification light microscopic examination, percentage of α-SMA$^+$ cells among stromal cells (non-inflammatory and non-smooth muscle of blood vessels' wall) in sub-epithelial connective tissue of normal mucosa and skin was calculated in 10 successive microscopic fields and their means were recorded. In OSCCs and CSCCs, percentage of α-SMA$^+$ cells among stromal cells (non-inflammatory and non-smooth muscle of blood vessels' wall) in close proximity to carcinomatous islands was calculated in 10 successive microscopic fields and their means were recorded. [5]

Percentage of α-SMA$^+$ cells was categorized as following: 0=absence of positive cells; 1= 1-25% of cells are positive; 2=26-50% of cells are positive; 3=51-75% of cells are positive; 4=76-100% of cells are positive. Intensity of cell staining for α-SMA was categorized as following: 0= negative; 1=weak; 2= moderate; 3= sever. [5] Qualitatively, presence of myofibroblasts was categorized as following: 0=negative; 1=scanty; 2=abundant. Samples without any stromal myofibroblasts were considered as "negative"; samples with scattered stromal myofibroblasts were considered as "scanty" and samples with numerous and densely arranged stromal myofibroblasts were considered as "abundant". [16, 18] Also, distribution pattern of stromal myofibroblasts in SCCs was categorized as "spindle" and "network" according to dominant pattern.

In "spindle" pattern, at low-power and moderate-power magnification, α-SMA$^+$ myofibroblasts with spindle shape morphology attach tightly to carcinomatous islands or nests as one to three concentric layers. In "network" pattern, stromal myofibroblasts are very abundant and have plump shape and sometimes their proportion becomes greater than carcinomatous components; they arrange as short to moderate length crossover bundles and at high power magnification, their high density creates a multi-layered image in mind. [19] In statistical analysis, we used SPSS software and the normality of data was tested by Kolmogorov–Smirnov and t-test, one way ANOWA was performed for qualitative data, Chi-Square test for categorical data.). Significance level was considered as P-value< 0.05.

Ethical Approvals: The study has been independently reviewed and approved by ethical board of Babol University of Medical Sciences.

Results

In this study, a total of 60 samples (20 low-grade OSCCs, 20 low-grade CSCCs, 10 Normal oral mucosa [NO] and 10 Normal skins [NS]) were investigated. We studied myofibroblasts in these samples with the above-mentioned methods (Figures 1 and 2).

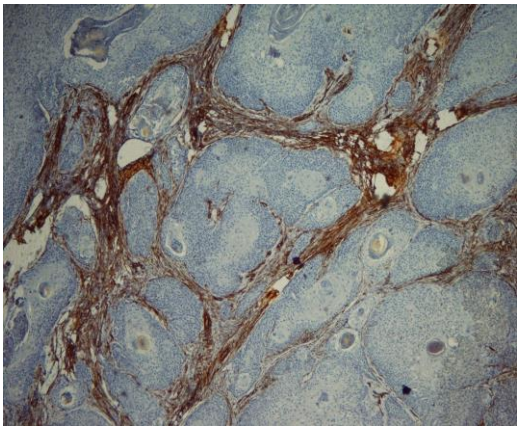

Figure 1. Myofibroblasts in invasive front of CSCC (40X magnification)

[Downloaded from cjdr.ir on 2026-11-23]
[DOR: 20.1001.1.22519890.2016.5.2.4.0]
[DOI: 10.22088/cjdr.5.2.24]

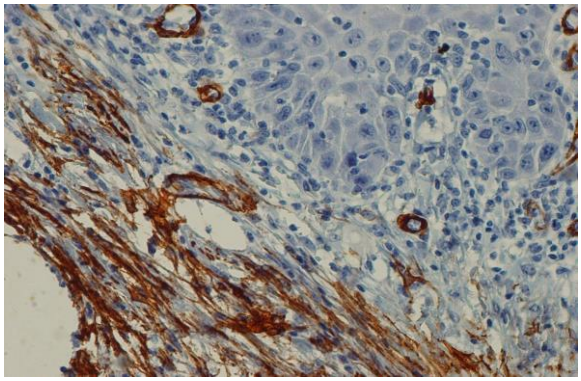

Figure 2. Myofibroblasts in invasive front of OSCC (400X magnification)

Mean percentage of myofibroblasts: The mean percentage of myofibroblasts of OSCC, CSCC, NO and NS samples is summarized in table 1. CSCC samples had the highest mean percentage of myofibroblasts and normal oral mucosal samples had the lowest .Results showed that the difference of mean percentage of myofibroblasts between OSCC and NO (P-value = 0.007<0.05) and also between CSCC and NS (P-value = 0.003< 0.05) was significant, but the difference of mean percentage of myofibroblasts between CSCC and OSCC was not statistically significant. (P-value = 0.97> 0.05) The percentage classification of myofibroblasts of OSCC, CSCC, NO and NS samples is summarized in table 2. According to table 2, the majority of OSCC and CSCC samples lies in second group (1-25% myofibroblasts); also, the majority of normal skin samples and half of normal oral mucosal samples has no myofibroblasts. Results showed that the difference of percentage classification of myofibroblasts between OSCC and NO (P-value = 0.036<0.05) and also between CSCC and NS (p-value = 0.002< 0.05) was significant, but the difference of percentage classification of myofibroblasts between CSCC and OSCC was not statistically significant. (P-value = 0.16).

Staining intensity of myofibroblasts: while the intensity of cell staining for α-SMA between OSCC and NO (P-value = 0. 001) and also between CSCC and NS (P-value = 0. 036< 0.05) was significantly different but the difference of intensity of cell staining for α-SMA between CSCC and OSCC samples was not statistically significant (P-value = 0.26). The majority of OSCC and CSCC samples had sever staining intensity for α-SMA.

Distribution of myofibroblasts: In addition, the distribution pattern of stromal myofibroblasts in OSCCs and CSCCs had spindle pattern and was not statistically significant between these groups. (P-value = 0. 29)

Qualitative classification of myofibroblasts: Furthermore, our results in qualitative presence of stromal myofibroblasts in OSCCs and CSCCs showed no statistically significant difference (P-value = 0. 29> 0.05). Ultimately, the majority of OSCC and CSCC samples were of "scanty" group.

Table 1. The mean percentage of myofibroblasts in studied groups

Group	N	Mean	Std.Deviation	P-value
Normal skin	10	2.2	4.1312	0.003
cutaneous squamous cell carcinoma	20	34.2	31.1124	
oral squamous cell carcinoma	20	33.85	35.4346	0.007
Normal oral mucosa	10	0.9	1.5239	

Table 2. The classification of percentage of myofibroblasts in studied groups

Group	percentage classification of myofibroblasts					P-value
	0%	1-25%	26-50%	51-75%	76-100%	
Normal skin	6	4	0	0	0	
cutaneous squamous cell carcinoma	0	10	4	3	3	0.002
oral squamous cell carcinoma	2	10	0	5	3	
Normal oral mucosa	5	5	0	0	0	0.036

Discussion

In this research, we found significant differences in mean percentage of myofibroblasts and percentage classification of myofibroblasts between OSCCs and NO, and between CSCCs and NS. Significant difference of mean percentage of myofibroblasts and percentage classification of myofibroblasts between OSCCs and NO suggest increased presence of these cells in OSCCs and probably their role in tissue invasion process and progression of OSCC. This finding is consistent with

[Downloaded from cjdr.ir on 2026-11-23]
[DOR: 20.1001.1.22519890.2016.5.2.4.0]
[DOI: 10.22088/cjdr.5.2.24]

other studies, which suggested that more OSCCs had "spindle" pattern of distribution[16, 17, 19, 20]. In their study, qualitatively myofibroblasts were scarce in normal samples just as our result. OSCCs had different myofibroblasts ranged from few to large numbers in their study which is similar to the current study. In the study of Seifi et al [17], OSCCs had "spindle" and "network" pattern of distribution for myofibroblasts and normal samples had scarce and scattered pattern; these findings are compatible with the results of the present study. In their research, more OSCCs had score 3 (myofibroblasts constitute more than 50% of stromal cells), which is the same as the current finding.

The findings of this study showed significant differences in mean percentage of myofibroblasts and percentage classification of myofibroblasts between CSCCs and NS suggested increased presence of these inflammatory cells in CSCCs and probably their role in tissue invasion process and progression of CSCC. This finding agrees with that of Kacar A et al. [21]

In compared with other researchers, Rao et al. [5] found significant differences in myofibroblasts frequency between OSCCs and oral submucous fibrosis, but they didn't have normal oral mucosa as control. They considered a role for myofibroblasts in fibrous, cancer progression and metastasis. In the current study, no significant difference was found in mean percentage of myofibroblasts and percentage classification of myofibroblasts between OSCCs and CSCCs. Although the malignant and metastatic potential of OSCC is more than CSCC, more invasive potential and poor prognosis of OSCC compared to CSCC are due to some factors except stromal myofibroblasts according to our findings; therefore, the role of myofibroblasts in different biological behavior of OSCC and CSCC is doubtful. Perhaps, more aggressive behavior of OSCC compared to CSCC is related to factors such as more vascularity of oral cavity compared to skin and subsequent easier access to lymphatic and blood vessels for earlier metastasis, late diagnosis of OSCC compared to CSCC due to less visibility, lack of safe margins and less capability to respect the entire tumor in oral cavity compared to skin due to more vicinity of oral cavity to vital organ and less accessibility in mouth and finally related to other molecules, markers and cells. Because of the novelty of current study in such a field (comparison of mean percentage of myofibroblasts and percentage classification of myofibroblasts between OSCC and CSCC) and lack of previous similar studies, it is not possible to compare this study with other studies from this standpoint.

Conclusion

Although presence of stromal myofibroblasts probably help the progression and invasion of OSCC and CSCC, it cannot have much importance in different biological behavior of OSCC and CSCC.

Acknowledgements

Hereby, we thank research Vice Chancellor of Babol University of Medical Sciences for their support of this study.

Funding: This study was a part of thesis and research project (Grant No: 2683) which was supported and funded by Babol University of Medical Sciences.

Conflict of interest disclosure: The authors state that they have no conflict of interest.

Authors' Contributions

The study was designed by Hamid Abbaszadeh. The study data were collected by Ali Dodani, Dr. Sepideh Siadati and Dr. Jahanshah Salehinejad. Analysis and interpretation of data were done by Dr. Karimollah Hajian Tilaki. Drafting of the manuscript and critical revision of the manuscript for important intellectual content were performed by Dr. Hamid Abbaszadeh and Ali Dodani. Study supervision was performed by Hamid Abbaszadeh.

References

1.Lambert R, Sauvaget C, de Camargo Cancela M, Sankaranarayanan R. Epidemiology of cancer from the oral cavity and oropharynx. Eur J Gastroenterol Hepatol 2011; 23:633-41.

2. Kane CL, Keehn CA, Smithberger E, Glass LF. Histopathology of cutaneous squamous cell carcinoma and its variants. Semin Cutan Med Surg 2004; 23:54-61.

3. Kalluri R, Zeisberg M. Fibroblasts in cancer. Nat Rev Cancer 2006; 6:392-401.

[Downloaded from cjdr.ir on 2026-11-23]

[DOR: 20.1001.1.22519890.2016.5.2.4.0]

[DOI: 10.22088/cjdr.5.2.24]

4. Ishii G, Ochiai A, Neri S.Phenotypic and functional heterogeneity of cancer-associated fibroblast within the tumor microenvironment. Adv Drug Deliv Rev 2016; 99(Pt B):186-96.
5. Rao KB, Malathi N, Narashiman S, Rajan ST. Evaluation of myofibroblasts by expression of alpha smooth muscle actin: A marker in fibrosis, dysplasia and carcinoma. J Clin Diagn Res 2014; ;8:ZC14-7.
6. Marsh D, Suchak K, Moutasim KA, Vallath S, Hopper C, Jerjes W, et al. Stromal features are predictive of disease mortality in oral cancer patients. J Pathol. 2011; 223:470-81.
7. Vered M, Dobriyan A, Dayan D, Yahalom R, Talmi YP, Bedrin L, et al. Tumor-host histopathologic variables, stromal myofibroblasts and risk score, are significantly associated with recurrent disease in tongue cancer. Cancer Sci 2010; 101:274-80.
8. Bello IO, Vered M, Dayan D, Dobriyan A, Yahalom R, Alanen K, et al. Cancer-associated fibroblasts, a parameter of the tumor microenvironment, overcomes carcinoma-associated parameters in the prognosis of patients with mobile tongue cancer. Oral Oncol 2011; 47:33-8.
9. Surowiak P, Murawa D, Materna V, Maciejczyk A, Pudelko M, Ciesla S, et al. Occurence of stromal myofibroblasts in the invasive ductal breast cancer tissue is an unfavourable prognostic factor. Anticancer Res 2007;27:2917-24.
10. Tsujino T, Seshimo I, Yamamoto H, Ngan CY, Ezumi K, Takemasa I, et al. Stromal myofibroblasts predict disease recurrence for colorectal cancer. Clin Cancer Res 2007;13:2082-90.
11. Hadler-Olsen E, Wetting HL, Rikardsen O, Steigen SE, Kanapathippillai P, Grénman R, et al. Stromal impact on tumor growth and lymphangiogenesis in human carcinoma xenografts. Virchows Arch 2010;457:677-92.
12. Khalili J. Oral cancer: risk factors, prevention and diagnostic. Exp Oncol 2008; 30:259-64.
13. Narendra H, Tankshali RA. Prevalence and pattern of nodal metastasis in pT4 gingivobuccal cancers and its implications for treatment. Indian J Cancer 2010; 47:328-31.
14. Quaedvlieg PJ, Creytens DH, Epping GG, Peutz-Kootstra CJ, Nieman FH, Thissen MR, et al. Histopathological characteristics of metastasizing squamous cell carcinoma of the skin and lips. Histopathology 2006;49:256-64.
15. Hinerman RW, Indelicato DJ, Amdur RJ, Morris CG, Werning JW, Vaysberg M, et al. Cutaneous squamous cell carcinoma metastatic to parotidarea lymph nodes. Laryngoscope 2008; 118:1989-96.
16. de-Assis EM, Pimenta LG, Costa-e-Silva E, Souza PE, Horta MC. Stromal myofibroblasts in oral leukoplakia and oral squamous cell carcinoma. Med Oral Patol Oral Cir Bucal 2012; 17:e733-8.
17. Seifi S, Shafaei S, Shafigh E, Sahabi SM, Ghasemi H. Myofibroblasts stromal presence and distribution in squamous epithelial carcinomas, oral dysplasia and hyperkeratosis. Asian Pac J Cancer Prev 2010;11:359-64.
18. Kellermann M, Sobral LM, da Silva SD, Zecchin KG, Graner E, Lopes MA, et al. myofibroblasts in the stroma of oral squamous cell carcinoma are associated with poor prognosis. Histopathology 2007;51:849-53.
19. Vered M, Allon I, Buchner A, Dayan D. Stromal myofibroblasts accompany modifications in the epithelial phenotype of tongue dysplastic and malignant lesions. Cancer Microenviron 2009; 2: 49–57.
20. Etemad-Moghadam S, Khalili M, Tirgary F, Alaeddini M. Evaluation of myofibroblasts in oral epithelial dysplasia and squamous cell carcinoma. J Oral Pathol Med 2009;38:639-43.
21. Kacar A, Arikok AT, Kokenek Unal TD, Onder E, Hucumenoglu S, Alper M. Stromal expression of CD*34*, alpha-smooth muscle actin and CD*26*/DPPIV in squamous cell carcinoma of the skin: a comparative immunohistochemical study. Pathol Oncol Res 2012;18:25-31.

[Downloaded from cjdr.ir on 2026-11-23]
[DOR: 20.1001.1.22519890.2016.5.2.4.0]
[DOI: 10.22088/cjdr.5.2.24]