

## Use of palatally inserted mini-screw for upper molar distalization: A case series

Valiollah Arash(DDS)<sup>1</sup>, Sepideh Rezapour(DDS)<sup>2</sup>, Reza Ghorbanipour (DDS)<sup>3</sup>, Babak Amoian (DDS)<sup>4</sup>,  
Fateme Majdzade (DDS)<sup>3✉</sup>

1. Associate Professor, Dental Materials Research Center, Department of Orthodontics, Faculty of Dentistry, Babol University of Medical Sciences, Babol, Iran.

2. General Dentist, Faculty of Dentistry, Babol University of Medical Sciences, Babol, Iran.

3. Assistant Professor, Department of Orthodontics, Faculty of Dentistry, Babol University of Medical Sciences, Babol, Iran.

4. Associate Professor, Dental Materials Research Center, Department of Periodontics, Faculty of Dentistry, Babol University of Medical Sciences, Babol, Iran.

✉Corresponding Author: Fateme Majdzade, Faculty of Dentistry, Babol University of Medical Sciences, Babol, Iran.

Email: fmajdzade@yahoo.com

Tel: +981132291408

Received: 12 Apr 2015

Accepted: 21 Sept 2015

### Abstract

Reports have shown that molars can be distalized successfully with virtually no orthodontic anchorage loss with an intraosseous anchorage, even with fully erupted second molars. The purpose of this study was evaluating the effects of mini-screws as skeletal anchorage for upper molar distalization. In this case series, three patients needing maxillary first molar distalization, were selected. mini-screw was inserted in the anterior part of the palate. The screws were anchored to the first premolars by transpalatal arch and immediately loaded (150-160 g) by 0.018-inch arch-wire and steel open-coil spring to distalize maxillary molars. The skeletal and dental changes were measured on cephalograms obtained before and after distalization. The amount of first molar distalization in the patients was 4 mm with 2° of tipping, 4 mm with 5° of tipping, and 3.5 mm with 2° of tipping respectively. Upper incisors and first premolars were stable during distalization.

**Keywords:** Orthodontic anchorage, Molar tooth, Palate

**Citation for article:** Arash V, Rezapour S, Ghorbanipour R, Amoian B, Majdzade F. Use of palatally inserted mini-screws for upper molar distalization: A case series. Caspian J Dent Res 2015; 4: 50-6.

## کاربرد مینی اسکرو پالاتالی جهت دیستاله کردن دندانهای مولر

ولی اله آرشی، سپیده رضاپور، رضا قربانی پور، بابک عمویان، فاطمه مجدزاده\*

### چکیده

گزارش ها نشان داده اند که با انکوریج داخل استخوانی دندانهای مولر بدون از دست رفتن انکوریج، حتی در حضور مولرهای دوم روییده میتوانند دیستاله شوند. هدف این مطالعه بررسی کاربرد مینی اسکروها به عنوان انکوریج اسکلتالی جهت دیستاله کردن مولرهای بالاست. در این مطالعه گزارش موارد سه بیمار نیازمند دیستالیزیشن مولرها انتخاب شدند. مینی اسکرو در قسمت قدامی کام قرار داده شد. اسکروها توسط یک ترانس پالاتال ارج به دندانهای پره مولر اول متصل شده و بلافاصله بانبروی ۱۵۰-۱۶۰ گرم توسط یک کویل اسپرینگ باز استیل روی سیم استیل ۰.۱۸/ جهت دیستاله کردن مولرها تحت اعمال نیرو قرار گرفتند. تغییرات اسکلتی و دندانی روی سفالوگرامهای قبل و بعد اندازه گیری شدند. مقدار دیستالیزیشن مولر اول در بیماران به ترتیب ۴ mm با ۲° تیپ دیستالی، ۴ mm با ۵° تیپ دیستالی و ۳.۵ mm با ۲° تیپ دیستالی بود. انسیزورها و پره مولرهای اول بالا در طی دیستالیزیشن ثابت بودند.

**واژگان کلیدی:** روش انکوریج ارتودنسی، دندان مولر، کام

### Introduction

After CI I malocclusion, most patients who require orthodontic treatment have CI II malocclusions.<sup>[1]</sup> Correction of molar CI II relationship by maxillary molar distalization without extracting the teeth has become popular during the last two decades. The current methods for distalization, use intraoral and extraoral appliances or a combination of both. However, the majority of these appliances result in anchorage loss in the form of distal tipping, extrusion, distal rotation of molars, and mesial movement of premolars and protrusion of incisors. Therefore, it is significant to control anchorage in orthodontic treatment.<sup>[2]</sup> Recently, skeletal anchorage systems such as miniscrews have been designed with titanium to provide stationary anchorage during different tooth movements and decrease treatment time without the need for patient's cooperation. Mini-screws have drawn a lot of attention because they have advantages such as minimum anatomic limitation in placement, easy placement and removal, no need for complicated clinical and laboratory stages, no need for osseointegration and lower costs. The locations for the placement of miniscrews in the maxilla include the anterior nasal spine, palate, tuberosity and the alveolar process between the teeth roots (inter-radicular areas) on the buccal and palatal sides.<sup>[3]</sup> Placement of miniscrews at

interdental areas for maxillary molar distalization has some disadvantages, including less mechanical stability of the mini-screw due to the relatively low thickness of cortical bone, damage potential to the roots of adjacent teeth, the necessity to use miniscrews with small diameters because of limited interdental space, the possibility of encroachment on the maxillary sinus, prevention of subsequent tooth movements, and etc.<sup>[4]</sup> If the upper incisors should be intruded during retraction, placement of miniscrews in buccal region is indicated.<sup>[5]</sup> In this context, the palate is the ideal location for miniscrews for maxillary molar distalization due to its adequate cortical bone thickness, resulting in miniscrew stability. Tomographic and CT scan studies have shown that the maximum bony tissue is found 6-9 mm posterior to the incisive foramen and 3-6 mm lateral to the mid-palatine raphe.<sup>[6]</sup>

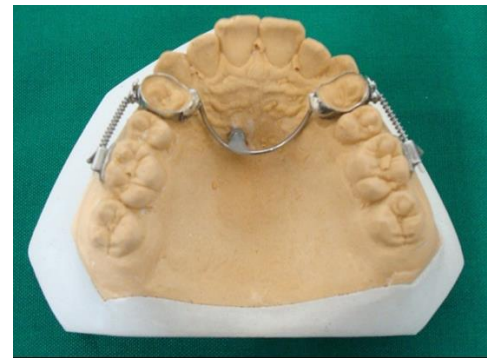
Kyung<sup>[7]</sup>, Oberti<sup>[8]</sup>, Polat-Ozsoy<sup>[9]</sup>, Gelgor<sup>[10]</sup> and Nappée- Miévilly et al.<sup>[11]</sup> used mini-screws placed in the palate for maxillary molar distalization. In these studies, molars were tipped during the distalization process. Escobar<sup>[12]</sup> and Kircelli<sup>[13]</sup> reported relatively severe tipping despite significant molar distalization with the use of miniscrew-supported pendulum while Suzuki et al.<sup>[14]</sup> and Sar et al.<sup>[15]</sup> with use of miniscrew implant-supported distalization system, reported

translation of first molars without distal tipping. The aim of this study was to evaluate skeletal and dental changes during maxillary molar distalization by palatal mini-screws as intraosseous anchorage and compare them with those in other studies.

### Case report

Two girls and one boy (11, 13, and 21 years old, respectively) with CI II molar relationship and space deficiency, who had no contraindications for surgeries, including systematic diseases and immunodeficiency, were selected. Mini-screws (Dual Top Anchor, Jeil Medical Corporation, Korea) measuring 10 mm in length and 1.6 mm in thickness were used for maxillary molar distalization in order to provide space. Informed consent was obtained from the cases.

The mini-screws were placed under local anesthesia by a periodontist. After providing the initial lateral cephalometric view, the thickness of bone was determined and a stent was prepared using an alginate impression. To ensure correct placement, the specific mini-screw location was determined in the stent, drilled and filled with gutta-percha. After gaining patient consent, the lateral cephalometric examination was repeated. Then, the mini-screw was placed 5 mm posterior to the incisive foramen and 3 mm to the left or right of the mid-palatine raphe using a micromotor (NSK, Tokyo, Japan) at 200 rpm. To prevent inflammation and infection, 0.2% chlorhexidine was prescribed for one week after placement of miniscrews, 0.018-inch steel brackets (Standard Edgewise System, Dentaaurum, Germany) were bonded on first premolars and bands (Standard Edgewise System, Dentaaurum, Germany) were placed on first molars on both sides. Then, an 0.036-inch palatal arch wire (Laboratory Wires, Round, Dentaaurum, Germany) was connected to premolars and its u-shaped end was fixed to mini-screw at the head of the mini-screw with dual-cured composite resin (Transbond XT, 3M Unitek, USA). For molar distalization in the session of mini-screw placement, a 0.018-inch steel wire (Dentaaurum, Germany) was placed between the first molar and the first premolar and distalization force was applied with an open coil spring (Ortho Technology Inc. USA). To control the rotation of molars transpalatal bars were soldered to palatal bands of first molars. The force was measured at 150-160 g with a gauge (Correx Tension Gauge, Switzerland) (Figure 1).



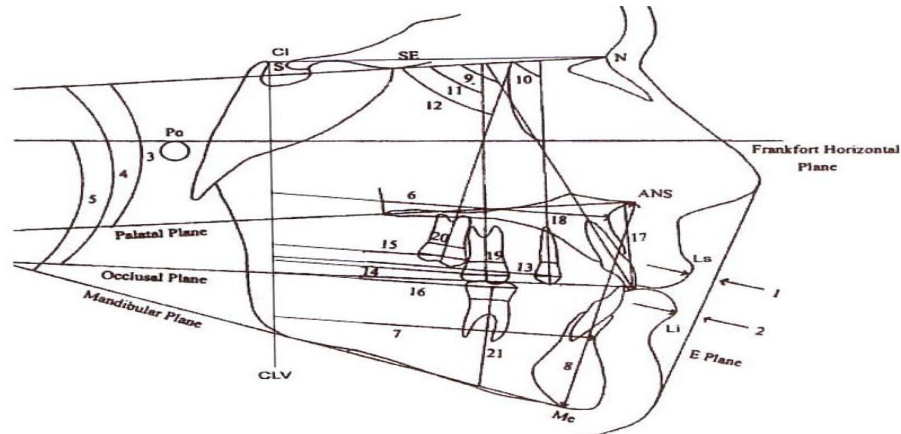
**Figure1. Skeletal supported anchorage for molar distalization**

The subjects were recalled at 4-week intervals and the coil springs were activated again and when the patient's occlusal relationship was converted to CI III up to 2 mm, distalization was terminated. Then the palatal arch was removed and replaced with Nance holding arch on molars to preserve the space. The mini-screw mobility was examined with zero (no movement) and one (presence of mobility) criteria after placement and at the end of distalization. Visual analogue scale was used to evaluate patient pain and discomfort one week after mini-screw placement and during its removal. Patients were asked to rate their expected pain experience on a 100-mm visual analog scale (VAS), where "0" represented no pain and "100" represented the worst pain imaginable. The following cut points on the pain VAS have been recommended: no pain (0–4 mm), mild pain (5–44 mm), moderate pain (45–74 mm), and severe pain (75–100 mm).<sup>[16]</sup> After the distalization period, a new cephalometric evaluation was carried out under the same conditions. The pre- and post-operative cephalograms were analyzed using the analysis techniques proposed by Nanda and Ghosh (Figure 2).<sup>[17]</sup> To determine the center of the tooth crown, the most prominent points in mesial and distal of the crown were connected by a line and the middle of this line was considered as the center of the crown (centroid). This line was used to evaluate linear-dental changes.

To determine dental molar axis, the most concave points at the mesial and distal aspects of CEJ were specified. Then the center point of the line connecting these two landmarks were determined and used to evaluate angular changes of the teeth. The length of treatment was 5 months and 20 days in the first patient, 5 months and 25 days in the second patient and 5 months and 22 days in the third patient. Slight inflammation was observed around the mini-screws

after a week. After placement and distalization, there was no movement in mini-screws. The VAS showed that placement of mini-screws was not painful but their

removal was a little unpleasant. Table 1 presents the results of analyses of cephalograms before and after the distalization of maxillary molars.

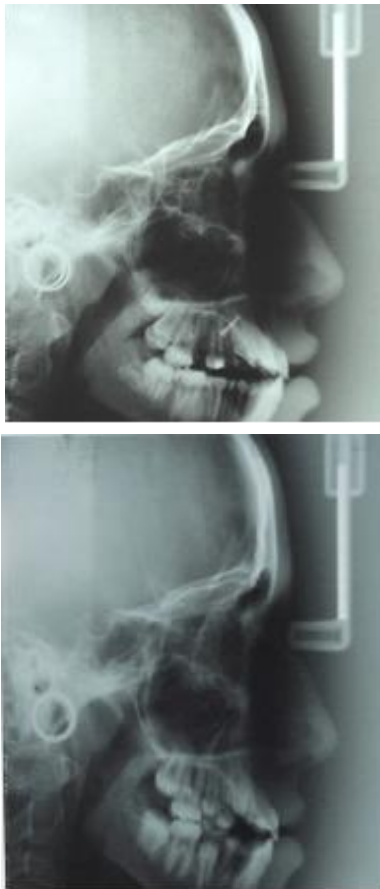

**Figure 2. Nanda and Ghosh Analysis for soft and hard tissue measurements**

1. Upper lip to E-line; 2. Lower lip to E-line; 3. SN-palatal plane; 4. SN-occlusal plane; 5. Frankfort-mandibular plane angle; 6. CLV to A point, 7. CLV to B point; 8. ANS to Me; 9. SN to maxillary incisors; 10. SN to maxillary first premolar; 11. SN to maxillary first molar; 12. SN to maxillary second molar; 13. CLV to maxillary first premolar centroid; 14. CLV to maxillary first molar centroid; 15. CLV to maxillary second molar centroid; 16. CLV to mandibular first molar centroid; 17. PP to maxillary incisor tip; 18. PP to maxillary first premolar centroid; 19. PP to maxillary first molar centroid; 20. PP to maxillary second molar centroid; 21. Mandibular plane to mandibular first molar centroid.

**Table1. Findings before and after maxillary molar distalization**

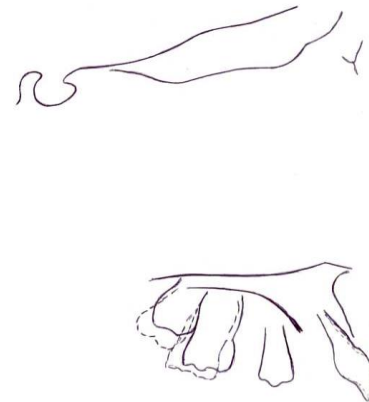
	Patient 1		Patient 2		Patient 3	
	before	after	before	after	before	after
SN-PP	7	6	4	3	15	16
SN-Occl P	20	19	15	14	26	26
FMA	40	40	37	39	30	37
SN-U1	103	104	70	70	93	93
SN-U4	85	85	81	81	71	71
SN-U6	70	68	70	65	67	65
SN-U7	70	68	51	48	53	50
CLV-A (mm)	77	77	69	69	61	61
CLV-B (mm)	78	77	67	67	41	41
ANS-Me (mm)	80	80	78	79	71	74
CLV-U4 (mm)	65	65	53.5	54	43.5	43
CLV-U6 (mm)	50	46	37	23	32.5	29
CLV-U7 (mm)	40	37	30	27	24	21
CLV-L6 (mm)	54	54	37.5	37.5	27.5	27
PP-U1 incisor tip (mm)	31	31	34.5	34.5	30	30
UL-E LINE(mm)	10	10	5	5	-2	-2
LL-E LINE(mm)	8	8	0	0	3	3
SN-Occl P	20	19	15	14	26	26



**Figure3.Upper: lateral cephalogram of pretreatment of 11 year old girl. Lower: posttreatment of the same patient and miniscrew placed in the palate. The upper molars were distalized**

The figure 4 shows the superimposition of maxillary teeth before and after molar distalization. The amount of distalization in the first patient was 4 mm with 2 degrees of tipping, 4 mm with 5 degrees of tipping in the second patient, and 3.5 mm with 2 degrees of tipping in the third patient. The maxillary second molars were distalized 3 mm in the three patients. The long axis of this tooth exhibited distal tipping of 2 degrees in the first patient and 3 degrees in the second and third patients.

The mandibular plane was stable in the first patient but it rotated clockwise up to 2 and 7 degrees in the second and third patients, respectively. The position of incisors and premolars was stable in all the three patients. There was no change in the distance between the upper lip and E line. All the patients experienced no pain (VAS: 0-4 mm) after mini-screw placement and mild pain (VAS: 5-44 mm) during removal of the miniscrews.



**Figure4. Superimposition of maxilla before and after molar distalization (solid line: pretreatment, broken line: post treatment)**

### Discussion

In the present study superimposition of pre- and post-operative cephalograms led to the conclusion that the side effects of other systems used to distalize molars, including protrusion of incisors, mesial movement of anterior anchorage teeth and distal tipping of first molars, do not happen with the use of mini-screws. The range of maxillary molar distalization after 5 months and 20 days in the first patient was 4 mm with 2 degrees of distal tipping, after 5 months and 22 days in the second patient it was 4 mm with 5 degrees of tipping, and after 5 months and 22 days in the third patient it was 3.5 mm with 2 degrees of tipping. Since this study showed that tipping of maxillary molars was less than that with the use of other systems, it can be concluded that the distal movement of molars was associated with less tipping. Similar to this study, Kyung<sup>[7]</sup> used two mini-screws on the mid-palatine raphe for the treatment of a 22-year-old patient. The third molars on both sides were extracted to facilitate the distal movement of the first and second molars. After 7 months of treatment, the first molars were distalized 5 mm at crown level and 3 mm at root level. Papadopoulos<sup>[18]</sup> used two mini-screws on both sides of the mid-palatine raphe, and distalization of first molars took 6 months during which no movement of incisors and no tipping of molars were observed. Studies on distalization with the use of other systems like mini-screw-supported pendulum have shown a range of maxillary molar distalization up to 5.1-6.4 mm.<sup>[12,13,15]</sup> Escobar<sup>[12]</sup> reported molar distalization of up to 6 mm with the distal tipping of molar long axis up to 11.3 degrees. Kircelli<sup>[13]</sup> reported distalization of 6.4 mm

with 10.9 degrees of distal tipping. Sar et al.<sup>[15]</sup> reported 2.9 mm distalization with 9 degrees distal tipping of upper first molars.

In spite of the fact that the range of distalization in those studies was more than that in this research, the range of tipping was greater, too, which might be attributed to the fact that treatment with a pendulum is carried out in two stages. First, the tooth is tipped with the pendulum and then other fixed appliances are used. Oberti<sup>[8]</sup> used two mini-screws in the anterior palate as direct anchorage. Molar distalization was  $5.9 \pm 1.7$  mm at crown level with  $5.6 \pm 3.7$  degrees of distal tipping in 6-8 months. Although the distal inclination of molar axis was much less than that with the pendulum, similar to the present study, the molars exhibited rotation, which might be attributed to the use of miniscrews as direct anchorage and the flexibility of the palatal arch. Polat-Ozsoy<sup>[9]</sup> reported results similar to those in the present study. In their study maxillary molars were distalized up to 3.5 mm in 6 months and there were no movements in the first premolars and incisors. Gelgor<sup>[10]</sup> carried out molar distalization in two groups and used an acrylic tubercle to increase anchorage in group 2. In group 1, the molars were distalized 3.95 mm in 4.5 months with 9.05 degrees of distal tipping. In group 2, the molars were distalized 3.88 mm in 5.4 months with 0.75 degrees of distal tipping. The incisors were protruded up to 1.08 degrees and the first premolars were tipped mesially up to 3.15 degrees, which might be attributed to the flexibility of the palatal arch. Due to strengthening of the palatal arch with the acrylic tubercle in group 2, no changes were observed in the position of first premolars and incisors.

Distalization resulted in tipping of the second molars in the present study. The first patient's wisdom teeth had been extracted before distalization and the second molars had fully erupted. Consequently, the first molars transferred the forces applied to the crowns of the second molars, resulting in 2 degrees of distal tipping in the second molars. In the second and third patients, 3 degrees of distal tipping were observed, which might be attributed to the presence of the dental bud of the third molars at the close proximity of the roots of the second molars, resulting in the transfer of the center of rotation to the apical third of the root after application of a distalizing force, tipping the tooth. In studies by Oberti<sup>[8]</sup>, Polat-Ozsoy<sup>[9]</sup>, Gelgor<sup>[10]</sup>, Suzuki et al.<sup>[14]</sup> and Sar et al.<sup>[15]</sup> no change was observed in the mandibular plane angle. In the first patient, the mandibular plane

angle did not increase during distalization. However, in the second and third patients 2 and 7 degrees of clockwise rotation was observed in the mandible, which was expected during the movement of maxillary molars. Lambardo<sup>[19]</sup> examined the palatal bone and concluded that it is suitable for miniscrew placement because the bone does not fracture and the screws are stable under the orthodontic forces. Since no movements were observed in screws from a clinical viewpoint until the end of treatment, it was concluded, similar to other studies, that use of miniscrews as anchorage in maxillary molar distalization in the paramedian area of the palate and their rapid loading are successful options. However, Kinzinger<sup>[20]</sup> reported that miniscrew might not be stationary during the treatment period. They used distal jets for distalization of maxillary molars in 8 patients. Two mini-screws were placed on either sides of the mid-palatine raphe for supporting the distal jet in each patient. It was reported that a lack of conformity of the transverse wire of the distal jet, which connected the two miniscrews, resulted in unequal distribution of force in screws. In addition, differences in the thickness of mucosa on the two sides of the mid-palatine raphe resulted in the placement of mini-screws at different levels, in itself resulting in uneven application of forces. It appears that fear of pain during miniscrew placement is a factor that prevents the patients from accepting mini-screws.

However, after examining pain by visual analogue scale, it was concluded that mini-screw placement and removal are not painful. There is minor pain during mini-screw removal (VAS: 5-44 mm) due to the release of the mucosa attached to the screw neck. It is useful to use topical anesthetic agents before removing mini-screws to alleviate such pains.

Further studies are necessary with larger sample sizes in order to evaluate the results of this study. In addition, it is recommended that two short mini-screws be placed on either side of the mid-palatine raphe to avoid damages to the roots of incisors.

## References

1. Danaie SM, Asadi Z, Salehi P. Distribution of malocclusion types in 7-9-year-old Iranian children. *East Mediterr Health J* 2006; 12:236-40.
2. Lim SM, Hong RK. Distal movement of maxillary molars using a lever-arm and mini-implant system. *Angle Orthod* 2007; 78:167-75.

3. Carano A, Velo S, Leone P, Siciliani G. Clinical applications of the Miniscrew Anchorage System. *J Clin Orthod* 2005; 39:9-24.
4. Park J, Cho HJ. Three-dimensional evaluation of interradicular spaces and cortical bone thickness for the placement and initial stability of microimplants in adults. *Am J Orthod Dentofac Orthop* 2009; 136:314.e1-12.
5. Tekale PD, Vakil KK, Vakil JK, Gore KA. Distalization of maxillary arch and correction of Class II with mini-implants: A report of two cases. *Contemp Clin Dent* 2015; 6: 226-32.
6. Baumgaertel S. Quantitative investigation of palatal bone depth and cortical bone thickness for mini-implant placement in adults. *Am J Orthod Dentofacial Orthop* 2009; 136:104-8.
7. Kyung SH, Lee JY, Shin JW, Hong C, Dietz V, Gianelly AA. Distalization of the entire maxillary arch in an adult. *Am J Orthod Dentofacial Orthop* 2009; 135:123-32.
8. Oberti G, Villegas C, Ealo M, Palacio JC, Baccetti T. Maxillary molar distalization with the dual-force distalizer supported by mini-implant: A clinical study. *Am J Orthod Dentofacial Orthop* 2009; 135:282.e1-5.
9. Polat-Ozsoy O. The use of intraosseous screw for upper molar distalization: A case report. *Eur J Dent* 2008; 2:115-21.
10. Gelgor IE, Karaman AI, Buyukyilmaz T. Comparison of 2 distalization systems supported by intraosseous screws. *Am J Orthod Dentofacial Orthop* 2007; 131:161.e1-8.
11. Nappée-Miévilley M, Nappée FJ, Kerbrat JB, Goudot P. [The pendulis appliance: a palatal miniscrew supported molar distalization device]. *OrthodFr* 2014; 85:265-73. [In French]
12. Escobar SA, Tellez PA, Moncada CA, Villegas CA, Latorre CM, Oberti G. Distalization of maxillary molars with the bone-supported pendulum: a clinical study. *Am J Orthod Dentofacial Orthop* 2007; 131:545-9.
13. Kircelli BH, Pektaş ZO, Kircelli C. Maxillary molar distalization with a bone-anchored pendulum appliance. *Angle Orthod* 2006; 76:650-9.
14. Suzuki EY, Suzuki B. Maxillary molar distalization with the indirect Palatal miniscrew for Anchorage and Distalization Appliance (iPANDA). *Orthodontics (Chic.)* 2013; 14:e228-41.
15. Sar C, Kaya B, Ozsoy O, Özçirpici AA. Comparison of two implant-supported molar distalization systems. *Angle Orthod* 2013; 83:460-7.
16. Lee TC, McGrath CP, Wong RW, Rabie AB. Patients' perceptions regarding microimplant as anchorage in orthodontics. *Angle Orthod* 2008; 78:228-33.
17. Ghosh J, Nanda RS. Evaluation of an intraoral maxillary molar distalization technique. *Am J Orthod Dentofacial Orthop* 1996; 110:639-46.
18. Papadopoulos MA. Orthodontic treatment of Class II malocclusion with miniscrew implants. *Am J Orthod Dentofacial Orthop* 2008; 134:604.e1-16.
19. Lombardo L, Gracco A, Zampini F, Stefanoni F, Mollica F. Optimal palatal configuration for miniscrew applications. *Angle Orthod* 2010; 80:145-52.
20. Kinzinger G, Gül den N, Yildizhan F, Hermanns-Sachweh B, Diedrich P. Anchorage efficacy of palatally-inserted miniscrews in molar distalization with a periodontally/miniscrew-anchored distal jet. *J Orofac Orthop* 2008; 69:110-20.