

## Frequency of radix molaris in mandibular first and second molars using cone-beam computed tomography images in a selected Iranian population

Mehrad Rafiei<sup>1✉</sup>, Zahra Tafakhori<sup>2\*</sup>

1. Dental Student, Student Research Committee, Rafsanjan University of Medical Sciences, Rafsanjan, Iran.

2. Associate Professor, Department of Oral and Maxillofacial Radiology, School of Dentistry, Rafsanjan University of Medical Sciences, Rafsanjan, Iran.

### Article Type

Research Paper

### ABSTRACT

**Introduction:** Adequate knowledge of dental anatomy is essential for successful endodontic treatment. The aim of this study was to determine the frequency of radix molaris in permanent mandibular first and second molars using cone-beam computed tomography (CBCT) in Rafsanjan-Iran in 2020.

**Materials & Methods:** The present study was conducted on CBCT images taken at a private oral and maxillofacial radiology clinic in Rafsanjan, Iran, in 2020. A total of 407 teeth were examined. An experienced radiologist reconstructed and examined the images in axial and, if necessary, sagittal section. Finally, the data were entered into SPSS 22 and analyzed using the chi-square test. A value of  $P < 0.05$  was considered statistically significant.

**Results:** A total of 365 (89.8) teeth, including 156 first molars and 209 second molars, were included in the study. Of these, 212 (58.1%) belonged to females and 153 (41.9%) to males. Sixteen (4.4%) teeth had three roots, all of which were first molars. Moreover, the extra roots were on the distolingual side and were radix entomolaris in all 16 cases. The prevalence of radix molaris was significantly higher in first molars ( $P = 0.001$ ) but did not differ by tooth side or sex.

**Conclusion:** The three-rooted mandibular first molars may occur in the Iranian population and are not a rare phenomenon.

**Keywords:** Incidence, Prevalence, Tooth Root, Cone-Beam Computed Tomography

Received : 20 May 2022

Revised : 15 Aug 2022

Accepted: 21 Aug 2022

Pub. online: 21 Sept 2022

**Cite this article:** Rafiei M, Tafakhori Z. Frequency of radix molaris in mandibular first and second molars using cone-beam computed tomography images in a selected Iranian population. *Caspian J Dent Res* 2022; 11(2):124-9.



© The Author(s).

Publisher: Babol University of Medical Sciences

\*Corresponding Author: Zahra Tafakhori, School of Dentistry, Rafsanjan University of Medical Sciences, Rafsanjan, Iran.

Tel: +98 34 34280008

E-mail: ztafakhori@yahoo.com

## Introduction

The first mandibular molars are the first permanent teeth to appear in the oral cavity and comprise the key to occlusion together with the second mandibular molars. These teeth have a large number of pits and fissures in their occlusal surface and have a low self-cleansing ability. Therefore, the mandibular first and second molars have a high risk of caries incidence and are more likely to need endodontic treatment in their lifetime. [1-3]

Performing a successful endodontic treatment depends on many factors. [2] One of the reasons for the failure of endodontic treatment is insufficient knowledge of the particular dental anatomy, which leads to errors in both diagnosis and treatment processes. [4] The mandibular first and second molars have two roots with two canals at the mesial root and one canal at the distal root. In some cases, there are two roots on the distal side. Researchers have identified this phenomenon as radix molaris. If this extra root is on the mesial side of the tooth, it will be called radix paramolaris, and if it is on the lingual side, it will be called radix entomolaris. [5, 6] The prevalence of radix molaris has been reported to vary from 3% to 40% in different communities. [7] The race has been shown to be a crucial factor in the occurrence of this phenomenon in different communities. [8, 9] Failure to identify additional roots can lead to endodontic treatment failure, a need for re-treatment, and increased expenses. Failure to treat one root can also lead to severe damage to the periodontal tissue. [8]

Conventional imaging is commonly used to assess the anatomical features of molars. [10] Nevertheless, this type of imaging cannot provide an accurate radiographic representation of the anatomical shape of the tooth because it offers two-dimensional images of a three-dimensional subject. Hence, cone-beam computed tomography (CBCT) is currently used to study the anatomy of teeth in greater detail. This type of imaging offers an excellent resolution, and due to its presentation of a three-dimensional image, it can provide better visualization of the external and internal morphology of the tooth and its root system than conventional and digital radiographs. [11, 6] Nowadays, CBCT is a crucial diagnostic technique in dentistry, especially in complex treatments. [12]

Studies have reported the prevalence of radix molaris to be 3-6% in the Iranian population [13, 14] but have evaluated only the first mandibular molars or extracted teeth. Considering the effects of race and ethnicity on the anatomy and morphology of human teeth and given the lack of studies on this subject in Iran, the present study was carried out to evaluate the frequency of radix molaris in permanent mandibular first and second molars using CBCT images in Rafsanjan, Iran in 2020. The researchers hope that their study will help dentists learn more about the prevalence and importance of this phenomenon in Iran so that unwanted incidents during treatment can be reduced.

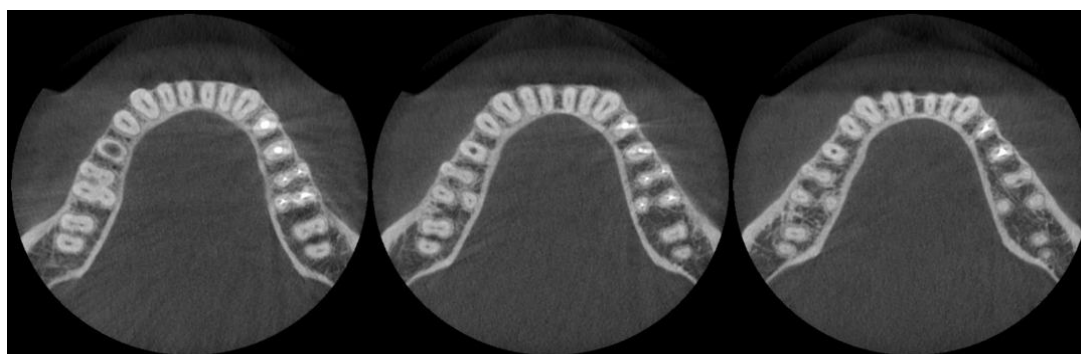
## Materials & Methods

The present study was performed on CBCT images obtained from patients referred to a private oral and maxillofacial radiology clinic in Rafsanjan city (Iran) from January 2020 to January 2021. These images were taken for diagnostic purposes or from patients who were candidates for dental implants. The code of ethics, with the number "IR.RUMS.REC.1400.129", was obtained from the research ethics committee of Rafsanjan University of Medical Sciences. The sample size was estimated using the enumeration method. The sample size was at least 143 with an absolute precision of 0.02 and a confidence level of 95% based on the study by Rahimi et al., in which the prevalence of radix molaris was 3%. [13] The sample size was obtained by the following formula:

$$n = \frac{Z^2 \cdot P(1-P)}{d^2}$$

A total of 407 CBCT images were taken with Planmeca ProMax 3D Classic (Helsinki, Finland) at 90 kVp and 10 mA for 10-15 seconds, with a voxel size of 0.4-0.6 mm. They were then evaluated using Planmeca Romexis software (version 3.8.3). All subjects with at least one mandibular molar were included in the study, and among them, those whose first or second permanent molars were fully erupted, had roots, had no pathologic lesions, and had not received dental treatment were evaluated. The images were examined by an experienced radiologist in axial section and, if necessary, reconstructed sagittal section (Figure 1).

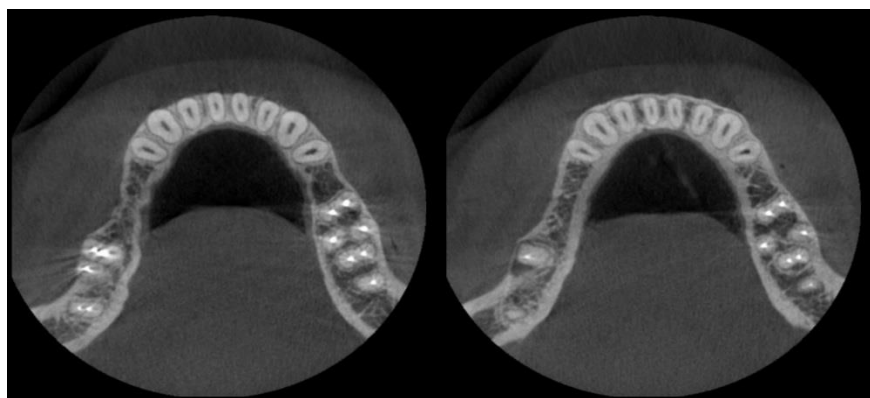
If there was an additional root, the radiologist recorded it as either radix entomolaris or radix paramolaris and noted whether it was on the right or left side. The patient's demographic information, including age and sex, was also recorded. In the end, the data were fed into SPSS software (version 22) and analyzed by the chi-square test. Statistically significant differences were set at  $P < 0.05$ .



**Figure 1. The bilateral incidence of radix entomolaris in the first mandibular molar on different axial sections**

## Results

Out of 407 radiographs, 365 (89.6%) mandibular molars, including 156 first molars and 209 second molars, were examined. A total of 212 teeth belonged to women and 153 to men. Further, 16 (4.4%) teeth had three roots, in all of which the extra root was on the distolingual side and was categorized as radix entomolaris (Figure 2). The chi-square test was used to evaluate the prevalence of radix molaris based on the tooth type, sex, and tooth side variables. The results showed that the prevalence of radix molaris varied significantly by tooth type. ( $P = 0.001$ ) The results also showed that all teeth with extra roots were first molars, and the prevalence of extra roots was thus reported as 10.3% in first molars. (Table 1).



**Figure 2. Incidence of radix entomolaris in the right mandibular first molar on different axial sections**

**Table 1. The frequency of radix molaris based on the study variables**

Variable	Frequency	Number of roots		P-Value
		Two	Three	
	Number	145	8	
	Percent	94.8	5.2	
	Number	204	8	
	Percent	96.2	3.8	
	Number	194	11	
	Percent	94.6	5.4	
	Number	155	5	
	Percent	96/9	3.1	
	Number	140	16	
	Percent	89.7	10.3	
	Number	209	0	
	Percent	100	0	

Data were analyzed by chi-square test

## Discussion

In the present study, the frequency of radix molaris was 4.4%. All additional roots were on the distolingual side (radix entomolaris), and no teeth with radix paramolaris were detected. The prevalence of radix entomolaris was 10.3% in the first molars. Detecting extra roots in the mandibular first and second molars is critical for a successful endodontic treatment.<sup>[15, 16]</sup>

Various studies have used different methods to investigate the prevalence of radix molaris. It has been shown that the use of periapical images to detect radix molaris may not be reliable,<sup>[13, 17]</sup> Some studies, however, have used periapical imaging to investigate the prevalence of radix molaris.<sup>[18, 19]</sup> Some researchers have also studied extracted teeth.<sup>[14, 20]</sup> In the present study, CBCT images were used. It provides a three-dimensional image of the tooth and enables the study of distances and angles. Tue et al. reported a prevalence of 25.61 for radix molaris in the first molars of a Taiwanese population.<sup>[19]</sup> In China, this prevalence was 29.7%.<sup>[21]</sup> While this three-rooted mandibular molar is a common phenomenon in East Asia, its prevalence rates in Africa, Europe, and South America have been reported to be 3, less than 1, and 1.7, respectively.<sup>[17]</sup>

In a Turkish population, Çolak et al. reported a prevalence of 1.9% for radix molaris in the first molars and 0.6% in the second molars.<sup>[22]</sup> Duman et al. also reported a prevalence of 1.2% for radix molaris in Turkey.<sup>[17]</sup> In a study the prevalence of radix molaris in the first molars was reported to be 4.5% in a Saudi population.<sup>[23]</sup> These differences may be due to different sample sizes and racial differences. In a study in northwestern Iran, Rahimi et al. showed that 3% of the first mandibular molars had radix molaris,<sup>[13]</sup> while the present study showed that the prevalence of radix molaris was 10.3% in the first mandibular molars. This discrepancy can be due to sample size as well as racial differences between the two regions. Another study reported that the prevalence of radix entomolaris was 6% in the first and 0.6% in the second molars.<sup>[16]</sup> In the present study, no three-rooted second molars and also no teeth with radix paramolaris were detected, and the prevalence of radix entomolaris was higher in the first molars, which might be due to technical differences at play.

In the present study, the prevalence of radix molaris was not affected by sex and jaw side. However, in all cases, the mandibular molars were not present on both sides, and the results on the effect of the side on the frequency of radix molaris can be biased. Others have also shown similar results.<sup>[13, 19, 24]</sup> In the present study, one subject had a bilateral incidence of radix molaris, and this scenario has been described in an Iranian population for the first time. This study showed that radix molaris is not a rare phenomenon in southeastern Iran and is especially common in the first molars. CBCT images are recommended to be used in these cases, as this technique shows the exact position of the tooth, the number of roots, and their angle and length very well. Therefore, it is possible to identify additional roots using CBCT images. The present study is a retrospective study, so prospective studies are recommended to investigate this phenomenon in more detail. In the present study, the teeth were not examined bilaterally, so it is recommended for future studies to examine the teeth bilaterally in each subject. It is also recommended to have the images examined by more than one person to avoid human error.

## Conclusion

In the Iranian population, three-rooted molars may occur in the first molars. Dentists should perform more diagnostic procedures if they suspect the presence of radix molaris, as this is not an uncommon finding.

## Funding

The present research (Grant No: 400045) was supported by Rafsanjan University of Medical sciences.

**Conflicts of Interest:** The authors have no conflict of interest.

## Authors' Contribution

Mehrad Rafiei designed the study and prepared the manuscript and performed the statistical analysis. Zahra Tafakhori collected the data and revised the manuscript.

## References

1. Peiris HR, Pitakotuwage TN, Takahashi M, Sasaki K, Kanazawa E. Root canal morphology of mandibular permanent molars at different ages. *Int Endod J* 2008;41:828-35.
2. Silva EJ, Nejaim Y, Silva AV, Haiter-Neto F, Cohenca N. Evaluation of root canal configuration of mandibular molars in a Brazilian population by using cone-beam computed tomography: an in vivo study. *J Endod* 2013;39:849-52.
3. Baugh D, Wallace J. Middle mesial canal of the mandibular first molar: a case report and literature review. *J Endod* 2004;30:185-6.
4. Sert S, Bayirli GS. Evaluation of the root canal configurations of the mandibular and maxillary permanent teeth by gender in the Turkish population. *J Endod* 2004;30:391-8.
5. Kuzekanani M, Haghani J, Nosrati H. Root and canal morphology of mandibular third molars in an Iranian population. *J Dent Res Dent Clin Dent Prospects* 2012;6:85-8.
6. Calberson FL, De Moor RJ, Deroose CA. The radix entomolaris and paramolaris: clinical approach in endodontics. *J Endod* 2007;33:58-63.

7. Wang Q, Yu G, Zhou XD, Peters OA, Zheng QH, Huang DM. Evaluation of x-ray projection angulation for successful radix entomolaris diagnosis in mandibular first molars in vitro. *J Endod* 2011;37:1063-8.
8. De Moor RJ, Deroose CA, Calberson FL. The radix entomolaris in mandibular first molars: an endodontic challenge. *Int Endod J* 2004;37:789-99.
9. Wu DM, Wu YN, Guo W, Sameer S. Accuracy of direct digital radiography in the study of the root canal type. *Dentomaxillofac Radiol* 2006;35:263-5.
10. Omer OE, Al Shalabi RM, Jennings M, Glennon J, Claffey NM. A comparison between clearing and radiographic techniques in the study of the root-canal anatomy of maxillary first and second molars. *Int Endod J* 2004;37:291-6.
11. Al-Shehri S, Al-Nazhan S, Shoukry S, Al-Shwaimi E, Al-Sadhan R, Al-Shemmery B. Root and canal configuration of the maxillary first molar in a Saudi subpopulation: a cone-beam computed tomography study. *Saudi Endod J* 2017; 2:69-76.
12. Venskutonis T, Plotino G, Juodzbaly G, Mickevičienė L. The importance of cone-beam computed tomography in the management of endodontic problems: a review of the literature. *J Endod* 2014;40:1895-901.
13. Rahimi S, Mokhtari H, Ranjkesh B, Johari M, Frough Reyhani M, Shahi S, et al.. Prevalence of extra roots in permanent mandibular first molars in Iranian population: a CBCT analysis. *Iran Endod J* 2017;12:70.
14. Kuzekanani M, Walsh LJ, Haghani J, Kermani AZ. Radix Entomolaris in the Mandibular Molar Teeth of an Iranian Population. *Int J Dent* 2017;2017:9364963.
15. Chakrabarty A, Sharma LCS, Sharma MS, Sudheer Kumar MSGP. Knowledge, Attitude And Practices Towards Endodontic Management Of Radix Cases. *Eur J Mol Clin Med* 2021;8:1052-8.
16. Kim KR, Song JS, Kim SO, Kim SH, Park W, Son HK. Morphological changes in the crown of mandibular molars with an additional distolingual root. *Arch Oral Biol* 2013;58:248-53.
17. Duman SB, Duman S, Bayrakdar IS, Yasa Y, Gumussoy I. Evaluation of radix entomolaris in mandibular first and second molars using cone-beam computed tomography and review of the literature. *Oral Radiol* 2020;36:320-6.
18. Yang Y, Zhang LD, Ge JP, Zhu YQ. Prevalence of 3-rooted first permanent molars among a Shanghai Chinese population. *Oral Surg Oral Med Oral Pathol Oral Radiol Endod.* 2010;110:e98-101.
19. Tu MG, Tsai CC, Jou MJ, Chen WL, Chang YF, Chen SY, et al. Prevalence of three-rooted mandibular first molars among Taiwanese individuals. *J Endod* 2007;33:1163-6.
20. Bhatia S, Kohli S, Parolia A, Yap NH, Lai CT, Tan EH. Prevalence of radix molar in mandibular permanent molars: an observational study in Malaysian population. *Oral Health Dent Manag* 2015;14:32-6.
21. Zhang R, Wang H, Tian YY, Yu X, Hu T, Dummer PM. Use of cone-beam computed tomography to evaluate root and canal morphology of mandibular molars in Chinese individuals. *Int Endod J* 2011;44:990-9.
22. Colak H, Ozcan E, Hamidi MM. Prevalence of three-rooted mandibular permanent first molars among the Turkish population. *Niger J Clin Pract* 2012;15:306-10.
23. Al-Alawi H, Al-Nazhan S, Al-Maflehi N, Aldosimani MA, Zahid MN, Shihabi GN. The prevalence of radix molaris in the mandibular first molars of a Saudi subpopulation based on cone-beam computed tomography. *Restor Dent Endod* 2019; 45:e1.
24. Kuzekanani M, Najafipour R. Prevalence and Distribution of Radix Paramolaris in the Mandibular First and Second Molars of an Iranian Population. *J Int Soc Prev Community Dent* 2018; 8:240-4.