

Frequency of middle mesial canal and radix entomolaris in mandibular first molars by cone beam computed tomography in a selected Iranian population

Somaye Hosseini¹, Ali Soleymani^{2✉}, Ehsan Moudi³, Tasnim Bagheri², Hemmat Gholinia⁴

1. Dental Student, Student Research Committee, Babol University of Medical Sciences, Babol, IR Iran. **ORCID** (0000-0002-9933-3344)
2. Assistant Professor, Oral Health Research Center, Health Research Institute, Babol University of Medical Sciences, Babol, IR Iran.
3. Associate Professor, Dental Materials Research Center, Health Research Institute, Babol University of Medical Sciences, Babol, IR Iran.
4. Msc in Statistics, Health Research Institute, Babol University of Medical Sciences, Babol, IR Iran.

✉Corresponding Author: Ali Soleymani, Department of Endodontics, Faculty of Dentistry, Babol University of Medical Sciences, Babol, IR Iran.

Email: soleymani_ali@yahoo.com

Tel: +981132291408

ORCID (0000-0003-1785-8081)

Received: 25 Jan 2020

Accepted: 29 Sept 2020

Abstract

Introduction: Although there are many studies about the internal anatomy of mandibular molars, there is still controversy over the frequency of middle mesial canals and isthmuses in the mesial root of mandibular molars and distolingual third root (Radix entomolaris) that it can be seen in any population, but it is more frequent in Asians and makes endodontic treatment difficult. Because of limited studies on the middle mesial canal, isthmus in north of Iran; therefore, the aim of this study was to investigate the frequency of these variations in the north of country.

Materials & Methods: In this retrospective cross-sectional study, The cone beam computed tomography (CBCT) images of 200 mandibular first molar teeth without any root canal treatment and completely erupted and developed were evaluated. Samples with open apex, internal root resorption, calcification, crown and extensive restoration were excluded. The patients' gender, age, tooth location (left and right), count of canals in the mesial root, presence or absence of isthmus in mesial root, middle mesial canal and isthmus level in the mesial root and distolingual root (Radix entomolaris) were studied in three groups based on age; <20, 20-40 and >40.

Results: From 200 samples, 18 teeth (9%) had middle mesial canal, 38 teeth (19%) had isthmus in mesial root and 6 teeth (3%) had distolingual root (Radix entomolaris).

Conclusion: due to the high frequency of isthmuses, middle mesial canals and Radix entomolaris in the population, which cannot be ignored, missing and treating these spaces could be one of the main reasons for failure in root canal treatment. Therefore, it is advised to put more effort into detecting and completely clean and obturate these spaces in surgical and non-surgical endodontic treatments.

Keywords: Tooth, Root canal therapy, Cone beam computed tomography

Citation for article: Hosseini S, Soleymani A, Moudi E, Bagheri T, Gholinia H. Frequency of middle mesial canal and radix entomolaris in mandibular first molars by cone beam computed tomography in a selected Iranian population. Caspian J Dent Res 2020; 9: 63-70.

بررسی میزان فراوانی کانال مزیال میانی و رادیکس انتومولاریس در مولرهای اول مندیبل توسط توموگرافی کامپیوتری با اشعه مخروطی در جمعیتی از ایران

سمیه حسینی^۱، علی سلیمانی^{۲*}، احسان موعودی^۳، تسنیم باقری^۴، همت قلی نیا^۴

۱. دانشجوی دندانپزشکی، کمیته تحقیقات دانشجویی، دانشگاه علوم پزشکی بابل، بابل، ایران.
 ۲. استادیار، مرکز تحقیقات سلامت و بهداشت دهان، پژوهشکده سلامت، دانشگاه علوم پزشکی بابل، بابل، ایران.
 ۳. دانشیار، مرکز تحقیقات مواد دندان، پژوهشکده سلامت، دانشگاه علوم پزشکی بابل، بابل، ایران.
 ۴. کارشناسی ارشد آمار، پژوهشکده سلامت، دانشگاه علوم پزشکی بابل، بابل، ایران.
- *نویسنده مسئول: علی سلیمانی، گروه اندودنتیکس، دانشکده دندانپزشکی، دانشگاه علوم پزشکی بابل، بابل، ایران.
پست الکترونیکی: soleymani_ali@yahoo.com تلفن: +۹۸۱۱۳۲۹۱۴۰۸

چکیده

مقدمه: اگرچه مطالعات زیادی در مورد آناتومی داخلی مولرهای مندیبل وجود دارد، اما هنوز در مورد شیوع کانال مزیال میانی و ایسموس در ریشه مزیال مولرهای مندیبل اختلاف نظر وجود دارد و همچنین ریشه سوم دیستولینگوال (رادیکس انتومولاریس) که این مورد میتواند در هر جمعیتی دیده شود، اما بیشتر در آسیایی ها دیده میشود و درمان ریشه را دشوار میسازد. از آنجا که مطالعات در مورد کانال مزیال میانی، ایسموس و رادیکس انتومولاریس در شمال ایران محدود است، برآنیم تا شیوع این موارد را در شمال کشور، با استفاده از تکنیک دقیق CBCT مورد مطالعه قرار دهیم.

مواد و روش ها: در این مطالعه گذشته نگر، تصاویر CBCT مربوط به ۲۰۰ دندان مولر اول مندیبل، بدون هیچ گونه درمان ریشه و کاملاً رویش یافته و تکامل یافته مورد بررسی قرار گرفتند. نمونه های دارای اپکس باز، تحلیل ریشه یا کلسیفیکاسیون، روکش و ترمیم وسیع از مطالعه خارج شدند. جنس بیمار، سن بیمار، موقعیت دندان (چپ و راست)، تعداد کانال ها در ریشه مزیال، وجود یا عدم وجود ایسموس در ریشه مزیال، محل حضور کانال مزیال میانی و محل حضور ایسموس در ریشه مزیال و وجود یا عدم وجود ریشه دیستولینگوال (رادیکس انتومولاریس) در سه گروه سنی ۲۰-، ۴۰-۲۰ و ۴۰+ بررسی شدند.

یافته ها: اختلاف معناداری بین میانگین فشار وارده بر دندان ها در بین دو گروه مشاهده نشد ($p>0.05$). اختلاف معناداری بین فراوانی های انواع شکست در بین دو گروه مشاهده نشد ($p>0.05$). فراوانی شکست cohesive در گروه CEM دو برابر گروه MTA بودند.

نتیجه گیری: در مجموع، با توجه به فراوانی ایسموس و کانال مزیال میانی و رادیکس انتومولاریس در جمعیت، که قابل چشم پوشی نیست، عدم پیدا کردن و درمان این فضاها میتواند یکی از دلایل اصلی شکست درمان اندودنتیک باشد، بنابراین توصیه به پاکسازی کامل و پر کردن این فضاها در درمان های اندودنتیک جراحی و غیرجراحی میشود.

واژگان کلیدی: دندان، درمان کانال ریشه، توموگرافی کامپیوتری با اشعه مخروطی

Introduction

The main purpose of endodontic treatment is complete cleansing and shaping of the pulp spaces and filling these spaces with acceptable materials.^[1] Although circumstances that affect root canal treatment are multiple, failure in detecting and cleaning the whole root canal system is one of the most important reasons

that influences a successful treatment. It has been proved that there is a correlation between the existence of missed canals and isthmuses and apical periodontitis.^[2] The molar teeth of the mandible are the most frequently affected teeth by carries. Therefore, they may need root canal treatment even at young ages.

Mandibular first molars are one of the most commonly treated teeth and include 17.4% of all root canal treatments. Among the treated teeth, the molar teeth of the mandible are the most common teeth that are extracted, and one of the main causes of their extraction is a failure in endodontic treatment (19.3%). Hence, knowledge of the anatomic variation of the root canal system in the different population may increase the likelihood of treatment success.^[3]

Factors affecting the morphology of mandibular first molars include genes and race.^[4] There are many types of research on the morphology of the mandibular molars, but there is still controversy over the frequency of middle mesial canals in the mesial root of the mandibular molars.^[2] Success rate in detecting the middle mesial canal is from 1% to 25%. Failure to find, clean and shape these root canal systems may cause persistent apical periodontitis.^[5] An isthmus is called a thin ribbon-shaped connection between two canals of a root. It is an important anatomical feature because it may contain pulp tissue remnants, necrotic tissues, microorganisms and their products. The mesial root of mandibular first molar has the most frequency of isthmuses.^[6] One of the anatomic variations of the first mandibular molar is the distolingual third root (Radix entomolaris), which can be seen in any population, but it is more frequent in Asians and makes the endodontic treatment difficult.^[7] At the opposite point, it is less frequent in the Turkish Cypriot population.^[8]

The Radix entomolaris orifice, which can be easily missed, may lead to untreated distolingual canals and cause treatment failure.^[9] Different techniques have been used to assess the root canal system.^[2] Recently, the cone beam computed tomography (CBCT) has been widely used as a 3D imaging technique in endodontic treatments, and it has many advantages over the routine 2D radiography in the assessment of the root canal morphology.^[10] The CBCT as a non-invasive three-dimensional method can be used directly in clinical assessments and has been reported to be as valid as clearing technique for assessing root canal system.^[9] Moreover, previous studies have shown that the CBCT was a valid tool for second mesiobuccal canal detection in maxillary first molars compared to the gold standard sectioning technique.^[11] Since the CBCT provides a 3D image, it is useful in special situations such as diagnosis and treatment of teeth with complex anatomy or lesions.^[12] Although the morphology of mandibular first molars has been widely investigated,^[13] studies on

the middle mesial canals, isthmuses and radix entomolaris are limited in the north of Iran. Therefore, the aim of this study was to investigate the frequency of these variations in the north of country.

Materials & Methods

The present study, as a retrospective cross-sectional study evaluated CBCT images of 200 mandibular first molars, provided by Newtom 5G(Newtom, Verona, Italy); operated at 110 kVp and 10 mAs. The field of the view was 12×8cm, and the voxel size was 75 µm.

Samples were selected from patients (male and female) In private maxillofacial radiology clinic during one year. This study was approved at the Ethics Committee of Babol University of Medical Sciences, Babol, Iran (with the code of IR.MUBABOL.HRI.REC.1397.248). The patients had no root canal treatments in their first mandibular molar and had completely erupted and developed mandibular first molars. Samples with open apex, root resorption, calcification, crown and extensive restoration were excluded.

$$\text{Sample size calculation: } n = \frac{z^2 p(1-p)}{d^2}$$

$$p=0.8^{[1]}$$

$$z=1.96 \Rightarrow n=113 \Rightarrow \text{minimum sample size}$$

$$d=0.05$$

The patients' sex, age, tooth location (left and right), the count of canals in the mesial root, presence or absence of the isthmuses in mesial root, middle mesial canal, and the isthmus level in the mesial roots, and presence of radix entomolaris, direction of its curvature, and inter orifice space between distolingual and distobuccal orifice and distolingual and mesolingual orifice were also recorded.

Samples were studied in three groups based on age; <20, 20-40 and >40. When a thin ribbon-shaped connection between mesiobuccal and mesiolingual canals was observed, it was recorded as the isthmus in the axial view (figure1).^[6] A true middle mesial canal was recorded when a round separated radiolucency between mesiobuccal and mesiolingual canals was observed in the axial view, despite the presence or absence of isthmuses (figure2).^[6] The Radix entomolaris root was examined in both axial and sagittal sections of CBCT (figure3).

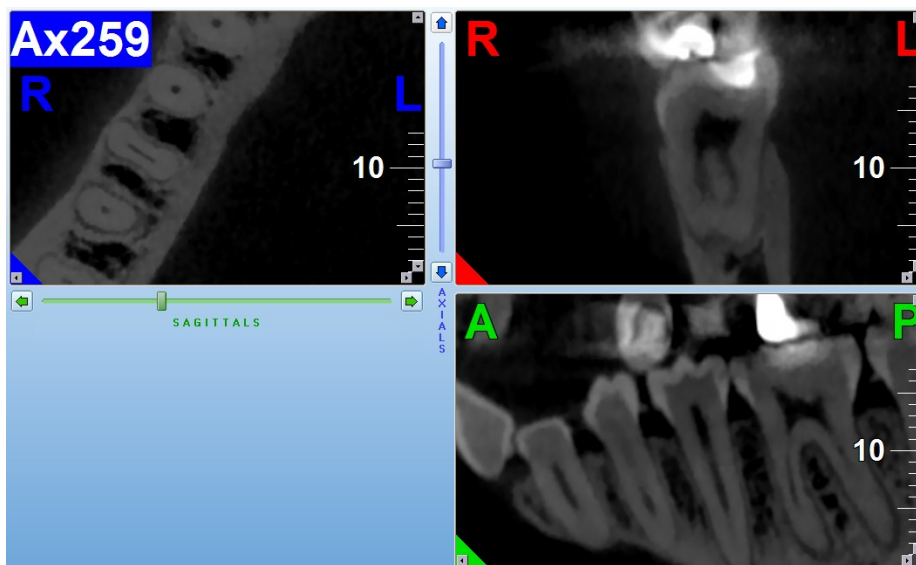


Figure1. Axial, coronal and sagittal view of CBCT image, showing isthmus in mesial root

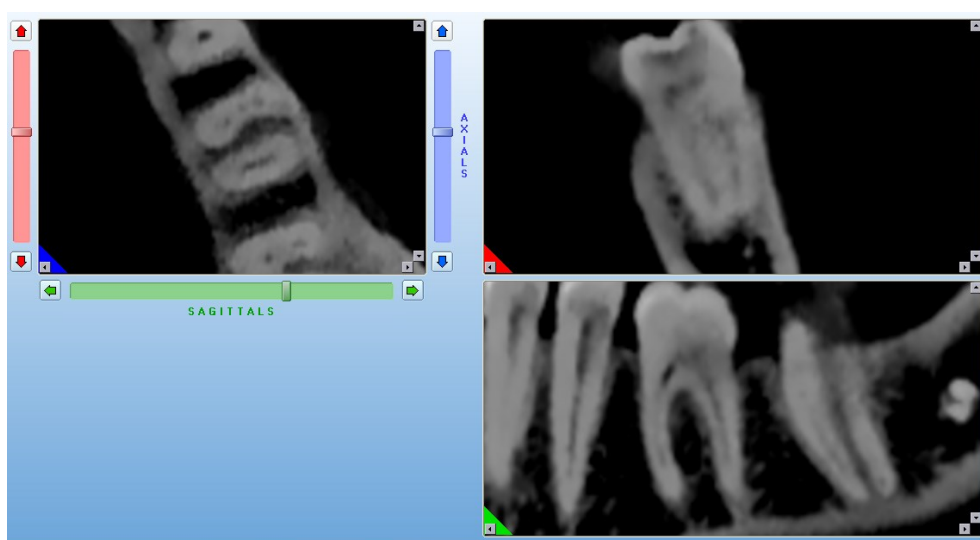


Figure2. Axial, coronal and sagittal view of CBCT image, showing middle mesial canal

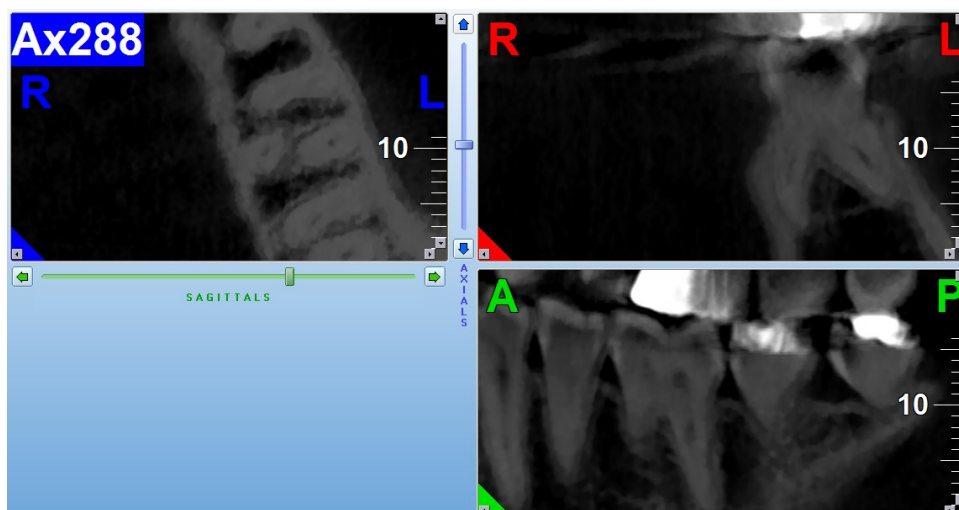


Figure3. Axial, coronal and sagittal view of CBCT image, showing Radix entomolaris

The CBCT images were assessed twice by two examiners including one endodontist and one radiologist. Images were observed by a third observer if there were any disagreements. Data were analyzed by SPSS (version 20.0, SPSS, Chicago, IL, USA). Descriptive statistics were reported in frequency, mean and standard deviation. The χ^2 and T-tests were used to compare indices in both genders, and $P < 0.05$ was statistically considered significant.

Results

Out of 200 cases, 18 cases (9%) had middle mesial canals, 38 cases (19%) had isthmuses in mesial root and 6 cases (3%) had distolingual roots (Radix entomolaris) (Table 1).

Table 1. Frequency of the middle mesial canal, isthmus in mesial root and Radix entomolaris root in mandibular first molars

	Frequency	Percent	total
MM canal	18	9%	200
Isthmus	38	19%	200
Radix ntomolaris	6	3%	200

All middle mesial canals (100%) were detected at cervical 1.3 of root. In total, 7 cases of the 18 middle mesial canals (38.88%) were originated from mesiobuccal orifice. Moreover, 3 cases (16.66%) were originated from mesiolingual orifice, and the other 8 cases (44.44%) had separated orifice located between mesiobuccal and mesiolingual orifice. In addition, 3 middle mesial canals (16.66%) finally joined the mesiolingual canal, and 2 canals (11.11%) finally joined the mesiobuccal canal. The other 13 canals (72.22%) faded and were not evaluable in more apical root sections.

Out of 38 cases with isthmus in mesial root, 13 case (6.5%) had isthmus in cervical one third of the root, 23 case (11.5%) had the isthmus in middle one third of root and 16 case (8%) had the isthmus in apical one third of root.

Out of 200 cases, 6 cases (3%) had distolingual roots (Radix entomolaris). Among the cases with Radix entomolaris, 1 case had a bilateral Radix entomolaris (1%). The distance between distolingual and distobuccal orifice was 3.2 - 4.7 mm, and the mean distance was 3.80 ± 0.63 mm. The distance between the distolingual and mesiolingual orifice was 3.2-3.9 mm. (Mean

distance = 3.55 ± 0.27 mm). All the Radix entomolaris roots in this study had curvatures in buccolingual direction and no significant curvatures in mesiodistal direction.

The relationship between the middle mesial canal and age was investigated. This relationship was not statistically significant ($P = 0.71$). The relationship between the presence of the isthmuses in the mesial roots and age was investigated. With age increasing, the isthmus frequency in the mesial roots decreased significantly ($p = 0.01$). No significant relationship was found between the presence of the middle mesial canals and gender ($P = 0.84$). No significant relationship was found between the presence of Radix entomolaris in the first mandibular molars and gender ($P = 0.45$).

Discussion

This study indicated that the frequency of the middle mesial canals in mandibular first molars was 9%, which is similar to the previous studies (between 1% and 15%).^[14] However, Mohammadzadeh Akhlaghi's study showed a lower percentage (0%). Since this study was performed on extracted teeth,^[15] it could be concluded that due to the probability of prior endodontic or periodontal disease and calcifications in the root canal system, the incidence of the middle mesial canals in extracted teeth was lower than healthy teeth, and the extracted teeth cannot represent healthy teeth in these studies.^[2]

Tahmasebi et al. in 2017 evaluated the CBCT images of Florida population and demonstrated that the incidence of the middle mesial canals in the mandibular first molars was 26%,^[2] which was higher than that in the present study. This difference can be attributed to the differences in the studied populations. It should also be borne in mind that the images reviewed in the present study were selected from the available CBCT archives prepared for other therapeutic purposes in a low dose to reduce the amount of the radiation received by the patients. There is also no information available with regard to the dose used in Tahmasebi's study (In both studies voxel size, mA and kVP were approximately similar, but the time of the exposure was not mentioned in her study).^[2]

The results of this study suggested that all middle mesial canals were present in cervical 1.3 levels of the roots, and most of them (55.56%) had a common orifice with the mesiobuccal and mesiolingual canals and

44.44% had a separate orifice. None of the detected middle mesial canals had a separate apical foramen.

The frequency of isthmuses in the mesial root of mandibular first molars was 19% in the ongoing study, which was lower than that in the study of Tahmasebi et al. in a population of Florida (64.7%).^[2] These may be due to the differences in the populations studied, and the CBCT images may also be obtained in a high dose in Tahmasebi's study, whose information is not available. In addition, in this study isthmuses were generally reported in the mandibular molar teeth which included the second molar, and it was noted that the frequency of the isthmuses was higher in the second molar.^[2]

In a study done by Mehrvarzfar et al in Isfahan, the prevalence of isthmus in the mesial roots was 83%,^[6] which is much higher than that in the present study. This difference can be attributed to the definition of the isthmus in these studies. In the present study, only the complete relationship between mesiobuccal and mesiolingual canals was recorded as isthmuses, indicating only complete isthmuses were considered, while in the Mehrvarzfar's study, incomplete communication was also recorded as incomplete isthmuses.^[6] Therefore, the frequency of the isthmuses in the current study was higher than that in the present study. In the present study, most of the isthmuses were present in the middle third level of the root (11.5%). The relationship between the frequency of the isthmuses in the mesial root of the first mandibular molars and age was investigated in this study. With age increasing, the frequency of the isthmuses in the mesial root of the first mandibular molars significantly decreased ($P = 0.01$), which could be related to secondary dentin formation.^[6]

The frequency of the Radix entomolaris in the present study was 3%, which is consistent with the prevalence of the Radix entomolaris in the Caucasian population (between 0.7% and 4.2%).^[16] In contrast, the prevalence of the Radix entomolaris roots was reported to be 5-40% or more among the East Asian population. Therefore, the Radix entomolaris is considered as a common morphological variation in East Asia.^[16] Among the samples with the Radix entomolaris root, 1 sample had bilateral Radix entomolaris (1%).

The inter orifice distance between the distobuccal and distolingual canal affects the shape of the access cavity. If there is a Radix entomolaris root, the shape of the access cavity should change from its usual triangular shape to a trapezoid shape. Compared to the normal

distolingual canal in a two-rooted molar tooth, the orifice of the distolingual canal is more distolingual in a three-rooted molar tooth.^[16]

In this study, we examined the inter orifice distance between distobuccal and distolingual canals and mesiolingual and distolingual canals. The mean distance between distobuccal and distolingual orifice was 3.80 ± 0.63 mm, and the mean distance between mesiolingual and distolingual orifice was 3.55 ± 0.27 mm. Mi-Ree et al. (2015) studied on a population of Korea and concluded that the DB-DL inter orifice distance was 2.8 ± 0.2 mm.^[16] These differences can be attributed to racial differences. All Radix entomolaris roots in this study had a curvature in the buccolingual direction and no significant curvature in the mesiodistal direction. These observations are consistent with the study of X Zhang et al. (2015) on a population of China.^[9]

These anatomical changes mean that file fracture may occur easily during cleaning and shaping. In addition, routine radiographs may not provide information about distolingual root curvatures in the buccolingual direction.^[13] In conclusion, using 3D CBCT imaging to understand the orientation of the curvatures of the Radix entomolar is due to the challenges. It may cause in endodontic treatment, which can be very helpful for treatment success.

The question now arises, aside from the nature of spaces between the mesiobuccal and mesiolingual canals, Is it necessary to cleanse and shape these spaces? Although the results of this study demonstrated that none of the middle mesial canals had separate apical foramen, the answer to the mentioned question is obvious. Previous studies have shown a relationship between the presence of untreated canals with isthmuses and apical periodontitis. These untreated canals and isthmuses can become infected with bacteria. Furthermore, if there is not enough shaping, the irrigation solution will not reach these areas and will not be disinfected. Therefore, regardless of the presence of the middle mesial canals or isthmuses, it is advised to complete instrumentation and irrigation these areas.^[2] In conclusion, due to the frequency of the isthmuses and middle mesial canals in the population, which cannot be ignored, the lack of finding and treating isthmuses or middle mesial canals could be one of the main reasons of root canal treatment failure. Therefore, it is advised to completely clean and obturate these spaces in surgical and non-surgical endodontics treatments. Proper

management of the isthmuses including bacterial load reduction and complete filling requires the use of newer technologies and further studies to confirm their effectiveness. According to a study by Mehrvarzfar et al., on laser cleansing function, it has been shown that this method is more useful in debris removal from apical one-third of the root canals compared to passive ultrasonic irrigation and manual washing techniques. In addition, the use of Er, Cr: YSGG lasers to obturate the root canal system results in an improved canal and isthmus obturation. Therefore, it is suggested to make use of modern technologies such as lasers modern irrigation machines and surgical microscopes that may lead to more complete cleaning and obturation during surgical and non-surgical endodontic treatments.^[6]

Conclusion

In conclusion, according to presence of isthmuses, middle mesial canals and Radix entomolaris in the population, which cannot be ignored, dentists should put more effort into detecting and cleaning these spaces in surgical and non-surgical endodontic treatments.

Acknowledgments

The authors wish to thank sincere cooperation of personnels on Dental Materials Research Center, Babol University of Medical Sciences.

Funding: This study was a part of research project (Grant no: 9706855), supported and funded by Babol university of Medical Sciences.

Conflict of interest disclosure: The authors state that they have no conflict of interest.

Authors' Contributions

The study was designed by Ali Soleymani and Ehsan Moudi. The study data were collected by Somaye Hosseini. Analysis and interpretation of data drafting of the manuscript, and critical revision of the manuscript for important intellectual content were performed by Hemmat Gholinia, Ali Soleymani, Ehsan Moudi. Study supervision was conducted by Ali Soleymani and Ehsan Moudi.

References

1. Hargreaves KM, Berman LH, Rotstein I, editors. Cohen's pathways of the pulp. 11th ed. St. Louis, Mo : Elsevier; [2016] .p.131
2. Tahmasbi M, Jalali P, Nair MK, Barghan S, Nair UP. Prevalence of middle mesial canals and isthmus in the mesial root of mandibular molars: An in vivo Cone-beam computed tomographic study. *J Endod* 2017;43:1080-3.
3. Torres A, Jacobs R, Lambrechts P, Brizuela C, Cabrera C, Guillermo G, et al. Characterization of mandibular molar root and canal morphology using cone beam computed tomography and its variability in Belgian and Chilean population samples. *Imaging Sci Dent* 2015;45:95-101.
4. Srivastava S, Alrogaibah NA, Aljarbou G. Cone-beam computed tomographic analysis of middle mesial canals and isthmus in mesial roots of mandibular first molars-prevalence and related factors. *J Conserv Dent* 2018;21:526-30.
5. Azim AA, Deutsch AS, Solomon CS. Prevalence of middle mesial canals in mandibular molars after guided troughing under high magnification: an in vivo investigation. *J Endod* 2015;41:164-8.
6. Mehrvarzfar P, Mohammadzade Akhlagi N, Khodaei F, Shojaei G, Shirazi S. Evaluation of isthmus prevalence, location, and types in mesial roots of mandibular molars in the Iranian Population. *Dent Res J (Isfahan)* 2014; 11: 251-6.
7. Torabinejad M, Walton RE, Fouad AF, editors. Endodontics: Principles and Practice. 5th ed. St. Louis, Missouri: Elsevier, Saunders ;2015.p.239.
8. Celikten B, Tufenkci P, Aksoy U, Kalender A, Kermeoglu F, Dabaj P, et al. Cone beam CT evaluation of mandibular molar root canal morphology in a Turkish Cypriot population. *Clin Oral Invest* 2016;20:2221-6.
9. Zhang X, Xiong S, Ma Y, Han T, Chen X, Wan F, et al. A Cone-beam computed tomographic study on mandibular first molars in a chinese subpopulation. *PLOS One* 2015;10:e0134919.
10. Madani ZS, Mehraban N, Moudi E, Bijani A. Root and canal morphology of mandibular molars in a selected Iranian population using cone-beam computed tomography. *Iran Endod J* 2017; 12: 143-8.
11. Gupta R, Adhikari HD. Efficacy of cone beam computed tomography in the detection of MB2 canals in the mesiobuccal roots of maxillary first

- molars: An in vitro study. *J Conserv Dent* 2017; 20: 332–6.
12. Torabinejad M, Walton RE, Fouad AF. *Endodontics: Principles and Practice*. 5th ed. St. Louis, Missouri: Elsevier, Saunders; 2015. p. 215.
 13. Nosrat A, Deschenes RJ, Tordik PA, Hicks ML, Fouad AF. Middle mesial canals in mandibular molars: incidence and related factors. *J Endod* 2015;41:28-32.
 14. 15. Hargreaves KM, Berman LH, Rotstein I, editors. *Cohen's pathways of the pulp*. 11th ed. St. Louis, Missouri : Elsevier; [2016]. p.131.
 15. Mohammadzadeh Akhlaghi N, Khalilak Z, Vatanpour M, Mohammadi S, Pirmoradi S, Fazlyab M, et al. Root canal anatomy and morphology of mandibular first molars in a selected iranian population: an in vitro study. *Iran Endod J* 2017;12:87-91.
 16. Mi-Ree Choi, Young-Mi Moon, Min-Seock Seo. Prevalence and features of distolingual roots in mandibular molars analyzed by cone-beam computed tomography. *Imaging Sci Dent* 2015; 45: 221-6.