

Prevalence of mandibular accessory foramina using CBCT in a selected Iranian population

Nazmehr Vahdani¹, Fatemeh Ghobadi¹, Ali Bijani², Sina Haghanifar³✉

1. Postgraduate Student, Student Research Committee, Babol University of Medical Sciences, Babol, IR Iran.
2. Assistant Professor, Social Determinants of Health Research Center, Health Research Institute, Babol University of Medical Sciences, Babol, IR Iran.
3. Associate Professor, Oral Health Research Center, Health Research Institute, Babol University of Medical Sciences, Babol, IR Iran.

✉ **Corresponding Author:** Sina Haghanifar, Department of Oral and Maxillofacial Radiology, Faculty of Dentistry, Babol University of Medical Sciences, Babol, IR Iran.

Email: s.haghanifar@mubabol.ac.ir

Tel: +981132291408

ORCID: (0000-0001-5949-8913)

Received: 7 Feb 2019

Accepted: 16 Mar 2019

Abstract

Introduction: The aim of the current study was to evaluate the frequency of accessory foramina in human mandible.

Material & Methods: In this cross-sectional study, 400 cone beam computed tomography (CBCT) images of mandibles of 273 patients (120 males and 153 females), divided into four groups ≤ 30 , 30–39, 40–49, and ≥ 50 years) with the mean age of 38.05 ± 13.71 years (40.71 ± 12.83 for males and 35.39 ± 12.05 for females) were evaluated. The number and diameter of accessory foramina from midline to anterior border of ramus with 0.1 mm intervals were investigated. Data were analyzed with SPSS 17 (SPSS Inc., Chicago, IL, USA) using T-Test, Pearson's correlation coefficient and Fisher exact test.

Results: Totally, 568 accessory foramina with mean diameter of 0.35 ± 0.15 mm were seen. The frequency of accessory foramina in the studied patients was 83% with mean frequency of 88% in males and 80% in females. These results showed a significant difference between the genders in frequency of accessory foramen ($P < 0.001$) although no difference was observed among different age groups. The highest frequency belonged to anterior lingual of mandible. The frequency of accessory foramina in posterior mandible was higher in females, while males indicated higher frequency in anterior mandible. No significant difference was found in the frequency of accessory foramina between the right and left sides of the mandible.

Conclusion: The results suggested, the survey of accessory foramina is recommended in CBCT images of mandible for therapeutic reasons due to higher frequency of accessory foramina in mandible.

Keywords: Mandible, Cone -beam computed tomography, Anatomic variation, Prevalence

Citation for article: Vahdani Nm, Ghobadi F, Bijani A, Haghanifar S. Prevalence of mandibular accessory foramina using CBCT in a selected Iranian population. Caspian J Dent Res 2019; 8: 31-6.

میزان شیوع سوراخهای فرعی استخوان فک پایین با استفاده از CBCT در جمعیتی از ایران

نازمهر وحدانی^۱، فاطمه قبادی^۱، علی بیژنی^۲، سینا حقانی فر^{۳*}

۱. دانشجوی دستیار، کمیته تحقیقات دانشجویی، دانشگاه علوم پزشکی بابل، بابل، ایران.
 ۲. استادیار، مرکز تحقیقات عوامل اجتماعی موثر بر سلامت، پژوهشکده سلامت، دانشگاه علوم پزشکی بابل، بابل، ایران.
 ۳. دانشیار، مرکز تحقیقات سلامت و بهداشت دهان، پژوهشکده سلامت، دانشگاه علوم پزشکی بابل، بابل، ایران.
- *نویسنده مسئول: سینا حقانی فر، گروه رادیولوژی دهان، فک و صورت، دانشکده دندانپزشکی، دانشگاه علوم پزشکی بابل، بابل، ایران.
پست الکترونیکی: s.haghanifar@mubabol.ac.ir. تلفن: +۹۸ ۱۱۳۲۲۹۱۴۰۸

چکیده

مقدمه: مطالعه حاضر با هدف ارزیابی میزان شیوع سوراخ های فرعی در فک پایین انسان می باشد.

مواد و روش ها: در این مطالعه مقطعی، ۴۰۰ اسکن CBCT فک پایین مربوط به ۲۷۳ بیمار (۱۲۰ مرد و ۱۵۳ زن) با میانگین سنی $38/05 \pm 13/71$ سال ($40/71 \pm 12/83$ سال در مردان و $35/39 \pm 12/05$ سال در زنان) و تقسیم شده در چهار گروه سنی (≥ 30 سال، ۳۱-۳۹ سال، ۴۰-۴۹ سال و ≥ 50 سال) ارزیابی شدند. تعداد و قطر سوراخ های فرعی از ناحیه میدلاین تا قدام راموس با مقاطع عرضی ۰/۱ میلیمتر بررسی شدند. داده ها توسط نرم افزار SPSS نسخه ۱۷ (SPSS Inc., Chicago, IL, USA) با استفاده از T-Test, Pearson correlation coefficient, and Fisher exact test آنالیز شدند.

یافته ها: بطور کلی ۵۶۸ سوراخ فرعی با میانگین قطر $0/35 \pm 0/15$ میلیمتر مشاهده شد. شیوع سوراخ های فرعی در بیماران مورد مطالعه ۸۳٪ با میانگین ۸۸٪ در مردان و ۸۰٪ در زنان بوده است. این نتایج نشان داد که تفاوت معناداری ($P < 0/001$) بین دو جنس در شیوع سوراخ های فرعی وجود دارد؛ اگر چه بین گروههای سنی مختلف تفاوتی مشاهده نشد. بیشترین شیوع سوراخهای فرعی در ناحیه لینگوآل قدام فک پایین بود. شیوع سوراخ های فرعی در خلف فک پایین در زنان بیشتر بوده در حالی که آقایان شیوع بالاتری را در قدام فک پایین نشان دادند. هیچ تفاوت معناداری در شیوع سوراخ های فرعی بین سمت راست و چپ فک پایین مشاهده نشد.

نتیجه گیری: نتایج نشان داد که با توجه به شیوع بالای سوراخهای فرعی در فک پایین بررسی آن در تصاویر CBCT بدست آمده از فک پایین جهت انجام امور درمانی توصیه می شود.

واژگان کلیدی: فک پایین، توموگرافی کامپیوتری با اشعه مخروطی، تنوع آناتومیکی، شیوع

Introduction

Being aware of the location of the neurovascular bundles in mandible is critical for a successful local anesthesia in oral surgeries.^[1-6] The role of mandibular accessory foramina ignored in diagnosis process is very important.^[2, 3] Accessory foramina are correlated with venous drainage and blood supply system, which form during the formation of primary teeth and alveolar process.^[3, 4] Accessory foramina are highly varied in adults and mostly located in the anterior and posterior lingual and buccal regions.^[3, 4, 7] Lack of awareness of the location of accessory foramina results in inadequate anesthesia during bone surgery processes as well as the accessory foramina play a role of spreading bony

invasion of tumors arising from mandibular lingual cortical plate and may cause a route for tumor spreading following radiotherapy of mandibular region.^[3, 8] In addition, the accessory foramina have a great importance in dental implant insertion in mandible, which are usually missed during the diagnostic phase of implant treatment.^[9-12] The survey of the accessory foramina was not possible in the past due to the lack of imaging techniques; however, nowadays with the advent of new devices such as CBCT, an accurate three-dimensional assessment of the jaws and tooth is provided, which leads to precise finding of accessory foramina.^[11, 13-19] Since, in the previous studies, there

was no assessment of accessory foramina's prevalence in the body of mandible [20-25], the aim of the current study was to evaluate the prevalence of accessory foramina in mandible of an Iranian population.

Materials & Methods

In the current cross-sectional study, 400 mandibular CBCT scan images of 273 patients (120 males and 153 females) referring to a private oral and maxillofacial radiology center from 2013 to 2017 were evaluated after ethical approval was given by Babol University of Medical Sciences (Mubabol.REC1396.64). Patients ranged from completely edentulous mandible to completely dentate mandible with the mean age of 38.05 years (40.71 years in male and 35.39 years in female) were categorized into 4 age groups of <30, 30-39, 40-49, and ≤50 years.

Exclusion criteria were history of bone disease and having bony lesions in the mandible such as cysts, osteosclerosis and chronic osteomyelitis, which can cause destruction and/or disappearance of buccal or lingual cortical plates or changes in density of the bone that cannot be surveyed the foramina. The CBCT images were provided by Cranex 3D (Soredex; Helsinki, Finland) with exposure parameters of 6 mA, 89 kvp, voxel size: 0.2 mm, and field of view: 6x8 cm. Using Ondemand 3D Dental software, from midline to anterior ramus of the teeth, the number and diameter of mandibular accessory foramina were assessed cross-sectionally with 0.1 mm intervals. Then, a diagnosis method was used to find the accessory foramina by looking at image slices of cross sections before and after foramina, observing the path of canal and following them from cortical bone to cancellous bone. Data were analyzed with SPSS 17 (SPSS Inc., Chicago, IL, USA) using T-Test, Pearson's correlation coefficient, and Fisher exact test. The informed consent was provided.

Results

Of 400 CBCT images evaluated in the current study, 178 and 222 were for male and female patients, respectively. The prevalence of accessory foramina in the studied patients was 83% with mean prevalence of 88% in males and 80% in females ($P < 0.001$). Their mean age was 38.05 years (35.39 years in females and 40.71 years in males) and the mean age of patients with accessory foramen was 39.97 years (37.36 years in females and 42.58 years in males). In addition, the patients were divided into 4 age groups. Table 1 shows the prevalence of accessory foramen in each group based on age range and gender.

Table 1. Descriptive frequency of mandibular accessory foramen in patients based on age and gender groups

Age Groups (year)	Number	Female Male	With AF*	Without AF
<30	76	50 26	40 23	63 3
30-39	57	40 17	33 14	47 3
40-49	69	31 38	23 33	56 5
≥50	71	32 39	27 36	63 3
Total	273	153 120	123 106	229 44

* AF = Accessory Foramen

Totally, 568 accessory foramina were found in the patients: 290 (52%) and 278 (48%) belonged to male and female patients. Moreover, the mean diameter of accessory foramina in males and females was 0.36 ± 0.16 and 0.34 ± 0.01 mm, respectively. Table 2 illustrates the prevalence of accessory foramen in the studied patients based on gender.

Table 2. Prevalence of mandibular accessory foramen in the studied patients based on gender

Sex	Without AF*	1AF	2 AF	3AF	4AF	5AF	6AF	7AF	8AF	9AF	10AF
Female	30	40	51	18	6	7	1	1	-	-	1
Male	14	27	29	15	22	3	3	2	2	1	-
Total	44	67	80	33	28	10	4	3	2	1	1

* AF = Accessory Foramen

Ten accessory foramina were observed in a patient; most of them were in anterior mandibular teeth. The maximum diameter was seen in the buccal surface of premolars (1.8 mm), while the minimum diameter

belonged to buccal regions of molars. Figure 1 demonstrates an accessory foramen in different regions and surfaces of mandible.

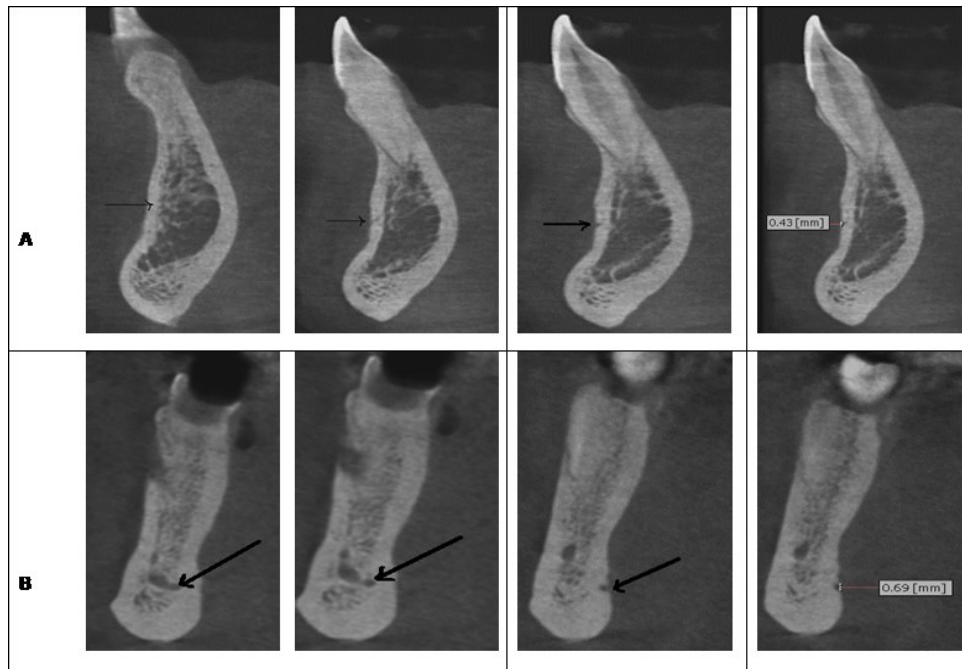


Figure1. Sectional CBCT in (A) buccal surface of central (B) lingual surface of premolar (C) lingual surface of canine (D) lingual surface of molar

Table 3 represents the number and mean diameter of accessory foramina in different regions of mandible based on gender and location. The prevalence of accessory

foramina was different between the genders ($P < 0.001$)—in females, they were more prevalent in posterior mandibles, while more common in anterior mandibles of males (Figure 2).

Table3. Frequency and mean diameter of mandibular accessory foramen in the studied patients based on location and gender

Place	Number	Male	Female	Diameters(Mean±SD)
Buccal (Anterior)	164	94	70	0.33±0.1
Lingual (Anterior)	265	142	123	0.38±0.1
Buccal (Premolar)	17	11	6	0.46±0.3
Lingual (Premolar)	78	33	45	0.32±0.1
Buccal (Molar)	4	0	4	0.28±0.06
Lingual (Molar)	40	10	30	0.29±0.9

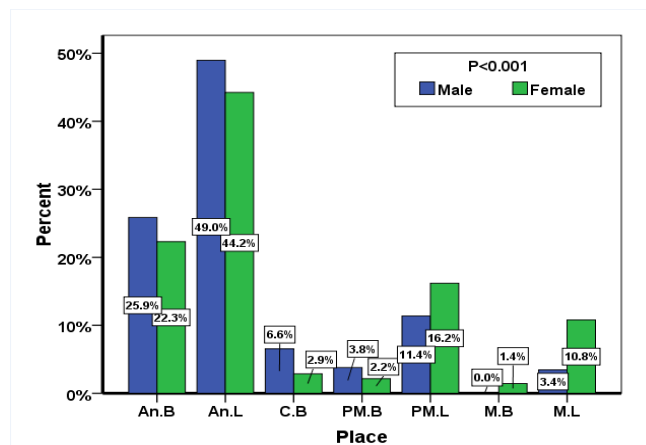


Figure2. Prevalence of mandibular accessory foramen in the studied patients based on gender and location*

* An .B =Anterior .Buccal An .L=Anterior .Lingual C .B =Canine Buccal PM .B =Premolar .Buccal
 PM .L =Premolar .Lingual M .B = Molar .Buccal M .L =Molar .Lingual

Discussion

The current study suggested that the prevalence of accessory foramen in the Iranian population was 83% and the prevalence was higher in males. Przystanska et al. evaluated the prevalence of accessory foramen in anterior lingual of mandible on 299 dry adult mandibles (regardless of gender) and suggested at least 1 accessory foramen in 288 mandibles (96%).^[20] They reported foramina in the lingual surface of anterior mandible; however, we evaluated the foramina extended up to cancellous bone in CBCT in this study. Varying results as a higher prevalence can be attributed to all accessory foramina regardless of its continuity to cancellous bone.

Sisman et al. have reported the prevalence of accessory foramina in CT images 2% (in our study it was 83%).^[21] This can be due to more precision of CBCT than that of CT images in evaluation of details. Like our study, the prevalence of accessory foramina was higher in males.

Gupta et al. evaluated 50 dry adult human mandibles of Indian population with magnifying glass.^[22] The prevalence of accessory lingual foramen was 88%, which is the same as our results. Freire et al.^[3], MurliManju et al.^[23], Samanta et al.^[24] and Padmavathi et al.^[25] assessed the accessory foramen in the area of mandibular foramen (medial of ramus) observationally.

The mean diameter of accessory foramina in males and females was 0.36 ± 0.16 and 0.34 ± 0.14 mm, respectively, the difference between genders was insignificant. The prevalence of accessory foramen was significantly higher in lingual of mandible than in buccal surface; this can be explained by more thickness of cortical bone on buccal border and separation of vessels and nerves on lingual surface. Generally, the prevalence of accessory foramen in posterior and anterior mandibles was higher in females and males, respectively.

In the current study, the mean diameter of accessory foramina reduced from anterior to posterior mandibular regions, and the minimum mean diameter of accessory foramina was found on buccal surface of mandibular molars. Since buccal and lingual plates were thicker in posterior regions than anterior ones, we concluded that a higher number and larger diameter of accessory foramina result from thinner buccal and lingual plates. Based on these results, the maximum number of accessory foramina in mandible was found in anterior lingual regions, which constituted 46% of total foramina observed.

Conclusion

Due to the repeated requests for reports on the observations of accessory foramina in mandible, anatomic variations should be studied using imaging examinations before surgical sections since the results may significantly affect the success of treatment. Results of the current study showed a remarkable prevalence of accessory foramen in a population in Iran; hence, we recommend the use of CBCT scan to identify and find the location of accessory foramina in mandibular surgeries as well as therapeutic plans and treatment procedures.

Funding: This study was a part of research project (Grant No: 9644718) supported and funded by Babol University of Medical Sciences.

Conflict of interest: The authors declare that they have no conflict of interest.

Author's Contribution

The study was designed by Sina Haghanifar and Nazmehr Vahdani. Sina Haghanifar and Nazmehr Vahdani defined the conceptual content of the research. The study data were collected by Nazmehr Vahdani. Statistical analysis and interpretation of data were accomplished by Ali Bijani. Preparation of manuscript was performed by Nazmehr Vahdani and Fatemeh Ghobadi. Study supervision was performed by Sina Haghanifar.

References

1. Haghanifar S1, Poorsattar Bejeh Mir A. Accessory mental foramina, incisive nerve plexus and lingual canals with unusual emergence paths: report of two rare cases. *Indian J Dent* 2015;6:44-8.
2. Haghanifar S1, Rokouei M. Radiographic evaluation of the mental foramen in a selected Iranian population. *Indian J Dent Res* 2009;20:150-2.
3. Freire AR, Rossi AC, Prado FB, Caria PH, Botacin PR. Incidence of the mandibular accessory foramina in Brazilian population. *J M S* 2012;29:171-3.
4. Goyal N, Garg A, Sharma M. Unilateral accessory mandibular canal and bilateral double mental foramina in dried human mandible-a case report. *Int J Basic Appl Med Sci* 2016;6:43-5.
5. Nagar M, Bhardwaj R, Prakash R. Accessory lingual foramen in adult Indian mandibles. *J Anat Soc India* 2001;50:13-4.

6. Shalini R, RaviVarman C, Manoranjitham R, Veeramuthu M. Morphometric study on mandibular foramen and incidence of accessory mandibular foramen in mandibles of south Indian population and its clinical implications in inferior alveolar nerve block. *Anat Cell Biol* 2016; 49: 241–8.
7. Seema AM. Multiple unilateral accessory mandibular foramina-a case report. *NJCA* 2012;1:190-2.
8. Fanibunda K1, Matthews JN. Relationship between accessory foramina and tumour spread in the lateral mandibular surface. *J Anat* 1999;195 (Pt 2):185-90.
9. Flygare L, Ohman A. Preoperative imaging procedures for lower wisdom teeth removal. *Clin Oral Investig* 2008;12:291-302.
10. Gowgiel JM. The position and course of the mandibular canal. *J Oral Implantol* 1992;18:383-5.
11. Haghanifar S, Arbabzadegan N, Moudi E, Bijani A, Nozari F. Evaluation of Lingual Mandibular Depression of the Submandibular Salivary Glands Using Cone-Beam Computed Tomography. *Res Med Dent Sci* 2018;;6:563-7.
12. Juodzbalys G, Wang HL, Sabalys G. Anatomy of Mandibular vital structures. Part II: mandibular incisive canal, mental foramen and associated neurovascular bundles in relation with dental implantology. *J Oral Maxillofac Res* 2010;1:e3.
13. Abesi F, Saeedi F, Haghanifar S, Moudi E, Khafri S. Evaluation of neurovascular anatomical variations in maxillary anterior region in cone beam computed tomography images. *Caspian J Dent Res* 2017;6:23-9.
14. Haas LF, Dutra K, Porporatti AL, Mezzomo LA, De Luca Canto G, Flores-Mir C, et al. Anatomical variations of mandibular canal detected by panoramic radiography and CT: a systematic review and meta-analysis. *Dentomaxillofac Radiol* 2016;45:20150310.
15. Neves FS, Torres MG, Oliveira C, Campos PS, Crusóé-Rebello I. Lingual accessory mental foramen: a report of an extremely rare anatomical variation. *J Oral Sci* 2010;52:501-3.
16. Pereira-Maciel P, Tavares-de-Sousa E, Oliveira-Sales MA. The mandibular incisive canal and its anatomical relationships: A cone beam computed tomography study. *Med Oral Patol Oral Cir Bucal* 2015;20:e723-8.
17. Haghanifar S, Yousefi S, Moudi E, Abesi F, Bijani A, Moghadamnia AA, et al. Accuracy of densitometry of two cone beam computed tomography equipment in comparison with computed tomography. *Electron Physician*. 2017;9:4384.
18. Haghanifar S, Moudi E, Bijani A, Lavasani SS, Lameh AR. Mandibular canal and its incisive branch: A CBCT study. *World Family Medicine* 2017;15:133.
19. Haghanifar S, Moudi E, Bijani A, Ghanbarabadi MK. Morphologic assessment of mandibular anterior teeth root canal using CBCT. *Acta Med Acad* 2017;46:85-93.
20. Przystanska A, Bruska M. Anatomical classification of accessory foramina in human mandibles of adults, infants, and fetuses. *Anat Sci Int* 2012;87:141-9.
21. Sisman Y, Sahman H, Sekerci A, Tokmak T, Aksu Y, Mavili E. Detection and characterization of the mandibular accessory buccal foramen using CT. *Dentomaxillofac Radiol* 2012;41:558-63.
22. Gupta S, Soni A, Singh P. Morphological study of accessory foramina in mandible and its clinical implication. *Indian J Oral Sci* 2013;4:12.
23. MurliManju BV, Prabhu LV, PraMeela M.D, Ashraf CM, Krishnamurthy A, Kumar CG. Accessory mandibular foramina: prevalence, embryological basis and surgical implications. *J Clin Diagn Res* 2011;5:1137-9.
24. Samanta PP, Kharb P. Morphometric analysis of mandibular foramen and incidence of accessory mandibular foramina in adult human mandibles of an Indian population. *Rev Arg Anat Clin* 2013;5:60-6.
25. Padmavathi G, Tiwari S, Varalakshmi KL, Roopashree R. An anatomical study of mandibular and accessory mandibular foramen in dry adult human mandibles of south Indian origin. *IOSR J Dent Med Sci* 2014;13:83-8.