

Accuracy of vertical bitewing radiography in determination of root length of maxillary primary molars

Mahtab Hamzeh¹, Farida Abesi², Soraya Khafri³, Ana Rakhshandejoo⁴✉

1. Assistant Professor ,Oral Health Research Center, Health Research Institute, Babol University of Medical Sciences, Babol, IR Iran. **ORCID** (0000-0002-5969-4356)
2. Associate Professor, Dental Materials Research Center, Health Research Institute ,Babol University of Medical Sciences, Babol, IR Iran.
3. Assistant Professor, Infertility and Reproductive Health Research Center, Health Research Institute, Babol University of Medical Sciences, Babol, IR Iran.
4. Dental Student, Student Research Committee, Babol University of Medical Sciences, Babol, IR Iran.

✉**Corresponding Author:** Ana Rakhshandejoo, Faculty of Dentistry, Babol University of Medical Sciences, Babol, IR Iran.
Email: ana_rakhshandeh@yahoo.com **Tel:** +989012042800 **ORCID** (0000-0003-3123-5470)

Received: 7 Jan 2018 Accepted: 30 Sept 2018

Abstract

Introduction: Considering the good geometry and possibility of simultaneous observation of the roots of the maxillary and mandibular molars in vertical bitewing radiography, the present study was conducted to evaluate the accuracy of vertical bitewing radiography in determination of root length of maxillary primary molars.

Material & Methods: One hundred first primary molars and forty second primary molars which were planned to be extracted for reasons other than this study, were used in this cross-sectional study. All radiographs were taken by a radiologist with vertical bitewing technique using XCP pediatric bitewing film holder. The root length was measured from the highest visible point of the occlusal surface to the most apical point of the root using caliper with accuracy of 0.1 mm. After removing the teeth, the length of each root was measured from the highest point at the occlusal surface to the tip of the root. Data were entered into SPSS 20 and analyzed using Pearson correlation and one sample t-test. Significance level was considered as 0.05.

Results: According to the results of one sample t-test, although the root length was estimated slightly higher than the actual size in all cases, the difference was significant only for distobuccal root of the first primary molar ($P < 0.05$). The results of Pearson correlation test showed that in 95% of cases, the true root length values were consistent with those measured by radiography.

Conclusion: Based on the results of this study, except for distobuccal root of first primary molar, the vertical bitewing could precisely determine the root length of primary molars.

Keywords: Bitewing radiography, Tooth root, Molar

Citation for article: Hamzeh M, Abesi F, Khafri S, Rakhshandejoo A. Accuracy of vertical bitewing radiography in determination of root length of maxillary primary molars. Caspian J Dent Res 2018; 7: 38-43.

ارزیابی دقت رادیوگرافی بایت وینگ عمودی در اندازه گیری طول ریشه مولرهای شیری فک بالا

مهتاب حمزه^۱، فریدا عابسی^۲، ثریا خفری^۳، آنا رخشنده جو^{۴*}

۱. استادیار، مرکز تحقیقات سلامت و بهداشت دهان، پژوهشکده سلامت، دانشگاه علوم پزشکی بابل، بابل، ایران.

۲. دانشیار، مرکز تحقیقات مواددندانی، پژوهشکده سلامت، دانشگاه علوم پزشکی بابل، بابل، ایران.

۳. استادیار، مرکز تحقیقات بهداشت باروری و ناباروری، پژوهشکده سلامت، دانشگاه علوم پزشکی بابل، بابل، ایران.

۴. دانشجوی دندانپزشکی، کمیته تحقیقات دانشجویی، دانشگاه علوم پزشکی بابل، بابل، ایران.

*نویسنده مسئول: آنا رخشنده جو، دانشکده دندانپزشکی، دانشگاه علوم پزشکی بابل، بابل، ایران. پست الکترونیکی: ana_rakhshandeh@yahoo.com
تلفن: +۹۸۹۰۱۲۰۴۲۸۰۰

چکیده

مقدمه: با توجه به ژئومتری بهتر و امکان رویت همزمان ریشه دندانهای مولر شیری فک بالا و پایین در رادیوگرافی بایت وینگ عمودی، مطالعه حاضر با هدف بررسی دقت رادیوگرافی بایت وینگ عمودی در تعیین طول ریشه مولرهای شیری فک بالا انجام شد.

مواد و روش ها: در مطالعه مقطعی حاضر از ۱۰۰ دندان مولر اول شیری و ۴۰ دندان مولر دوم شیری که باید به دلایلی غیر از انجام این مطالعه کشیده می شدند، استفاده شد. همه رادیوگرافی ها توسط یک متخصص رادیولوژی با تکنیک بایت وینگ عمودی بوسیله فیلم نگهدار بایت وینگ عمودی اطفال XCP تهیه شدند. پس از تهیه رادیوگرافی توسط کولیس با دقت ۰/۱ میلیمتر طول ریشه از بالاترین نقطه قابل رویت از سطح اکلوژال تا اپیکال ترین نقطه قابل مشاهده اندازه گیری شدند. پس از خارج کردن دندان ها طول هر یک از ریشه ها از بلندترین نقطه در سطح اکلوژال تا نوک ریشه اندازه گیری شده و ثبت گردید. داده ها وارد نرم افزار SPSS 20 شده و با استفاده از تست های ضریب همبستگی پیرسون و one sample T-test آنالیز شدند. $P < 0.05$ از لحاظ آماری قابل ملاحظه در نظر گرفته شد.

یافته ها: طبق نتایج آزمون one sample t-test، اگرچه کلیه موارد، رادیوگرافی، اندازه طول ریشه را کمی بیشتر از اندازه واقعی تخمین زده بود، اما این تفاوت تنها در مورد ریشه دیستوباکال دندان D، از لحاظ آماری قابل ملاحظه بود. نتایج آزمون همبستگی پیرسون نشان داد که در ۹۵٪ موارد مقادیر طول ریشه واقعی با مقادیر اندازه گیری شده توسط رادیوگرافی همسو بودند.

نتیجه گیری: بر اساس نتایج این مطالعه، به جز در مورد ریشه دیستوباکال دندان D، رادیوگرافی بایت وینگ عمودی در تعیین طول ریشه مولرهای شیری فک بالا از دقت خوبی برخوردار بود.

واژگان کلیدی: رادیوگرافی بایت وینگ، ریشه دندان، مولر

Introduction

Root canal therapy is a therapeutic option for teeth with infectious pulp. Deciding between pulpectomy and extraction of the tooth sometimes becomes difficult. Extraction of deciduous teeth can alter child's behavior and tendency toward dentistry due to the pain and pressure felt by the child during the procedure. On the

other hand, early loss of the tooth can lead to space loss and puts permanent tooth eruption at risk.^[1-3] Determination of root length plays an important role in choosing between root canal therapy or tooth extraction. If pulpectomy is considered as the therapeutic option, the exact determination of root length for complete root canal cleaning and prevention of damage to underlying

permanent tooth is an important issue.^[4] Planning appropriate treatment for these teeth requires a tool for observation of root and the surrounding tissue along with clinical examination. Radiographs are excellent methods to detect the decays which are not clinically apparent. Therefore, the replacement of carious lesions is postponed until radiological evidence is observed.^[5] Radiography is the most common technique for determining root length and evaluating the structures around the root.^[6] Moreover, the complex anatomy of the root canal system in the primary molars makes the determination of location of the apex less precise and the precise measurement of the root length is compromised sometimes due to the presence of permanent tooth buds, periapical pathologies and pathological or physiological root resorption.^[7,8] Different studies on accuracy of periapical radiography have shown different results.

In the study of Subramaniam et al. in 2005, there was no significant difference between root length measured by conventional and digital periapical radiography and true root length.^[9] In a study conducted by Krishnan et al. in 2012, periapical radiography was able to determine the root length of single-root teeth in a range of 0.5 mm difference with real length (72%).^[10]

According to the results of Neena et al. in 2011, both digital and conventional periapical radiography were able to reliably measure the length of the root.^[11] Different results were observed in studies which compared bitewings and periapical radiography.^[12,13] Considering the better geometry and the possibility of simultaneous observation of the roots of the maxillary and mandibular molars in vertical bitewing radiography, leading to a decrease in the dose of radiation, the present study was conducted to determine the accuracy of vertical bitewing radiography in determining root length of maxillary molars.

Materials & Methods

This cross-sectional study was approved by Ethical Committee of Babol University of Medical Sciences (Ethical number: mubabol.rec.1395.236). The patients referred to Pediatric Dentistry Department of Babol University of Medical Sciences were selected based on inclusion criteria and according to clinical conditions, the tooth extraction was planned. In the present study, with coefficient of influence of 1/0 (R) at 95%

confidence level with 80% power, 140 samples were determined using G POWER software.

The inclusion criteria were the presence of the maxillary molar teeth that were decided to be extracted for some reasons other than this study (extensive caries, orthodontic reasons, and parents' unwillingness to save the teeth). The teeth with no visible crown in the radiograph or with fracture during the extraction were excluded from the current study.

In the present study, 140 maxillary molars including 100 first primary molars and 40 second primary molars were extracted and used. All radiographs were taken by a radiologist using the Minray Soredex (Finland) device with Vertical Bitewing Technique by the XCP pediatric bitewing film holder (Dentsply, Rinn Co, USA). In all cases, the KVP of the device was 60 and mA was equal to 7, and the radiation duration varied according to the size of the child. All radiographs were developed using the Air-Techniques PERI-PRO III (Air Techniques, New York, USA) automatic device (figure 1). After taking radiographs, the root length was measured from the highest visible point of the occlusal surface to the most apical point of the root using Beerendonk caliper (Dentaurum, Ispringen, Germany) with the precision of 0.1 mm.

After removing the teeth, the length of each root was measured from the highest point at the occlusal surface to the tip of the root. Finally, the collected data were entered into SPSS 20 and analyzed using statistical tests such as one sample t-test and Pearson correlation. A significant level was considered 0.05.

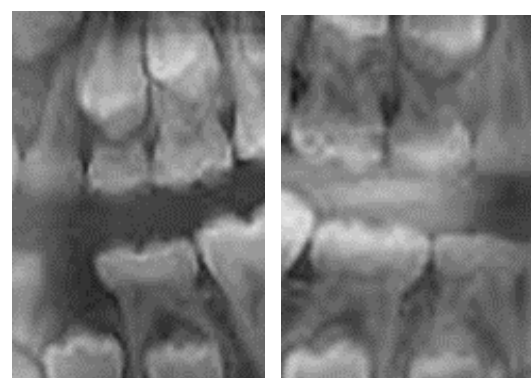


Figure1. Vertical bitewing images of primary molars

Results

Minimum, maximum and average of true and radiographic length of the roots are illustrated in tables 1, 2 and 3 based on the type of the root and teeth.

According to one sample t-test, in all cases, though the root length was estimated slightly more than the true length, this difference was only statistically significant for distobuccal root of first primary molar (P=0.001, table 1, 2).

The results of Pearson correlation test showed that in 95% of the cases, values of the true root length were consistent with the values measured by radiography (table 3).

Table 1. Difference of radiographic and true root size of first primary molars

Root type Measurement	Mesiobuccal			Distobuccal			Palatal		
	True	Radiogra phy	Differenc e	True	Radiogra phy	Differenc e	True	Radiogra phy	Differenc e
Maximum	7.5	8	-3	7.5	7	-1	9	8.5	-2
Minimum	15	16	2	14	14.5	3	15	15	3
Mean±SD	12.34±1.75	12.85±1.94	0.51±0.70	10.52±1.33	11.32±1.07	0.80±0.90	11.88±1.34	12.41±1.39	0.53±0.86
p-value*		0.937			0.001			0.754	

• The results of one sample t-test to measure the difference of radiography and true results with the hypothetical fixed value of 0.5

Table 2. Difference of radiographic and true root size of second primary molars

Root type Measurement	Mesiobuccal			Distobuccal			Palatal		
	True	Radiography	Difference	True	Radiography	Difference	True	Radiography	Difference
Maximum (mm)	7.5	7.5	-1.5	8	8.5	-1	8	8.5	-1.5
Minimum (mm)	14	15.5	1.5	15	15.5	2.5	15.5	16	2
Mean±SD (mm)	11.31±2.09	11.81±2.48	0.50±0.77	10.87±1.53	11.45±0.50	0.57±0.75	12.10±1.96	12.46±2.04	0.35±0.73
p-value*		1.00			0.517			0.232	

• The results of one sample t-test to measure the difference of radiography and true results with the hypothetical fixed value of 0.5

Table3. Correlation of radiographic and true root size of first and second primary molars

First primary molar	Radiographic Mesiobuccal	True Mesiobuccal	Radiographic Palatal	True Palatal	Radiographic Distobuccal	True Distobuccal
		R 0.934 pvalue <0.001	R 0.934 pvalue <0.001	R 0.801 pvalue <0.001	R 0.801 pvalue <0.001	r 0.737 pvalue <0.001
Second primary molar	Radiographic Mesiobuccal	True Mesiobuccal	Radiographic Palatal	True Palatal	Radiographic Distobuccal	True Distobuccal
		R 0.958 pvalue <0.001	R 0.958 pvalue <0.001	R 0.933 pvalue <0.001	R 0.933 pvalue <0.001	r 0.877 pvalue <0.001

• Based on pearson correlation test

Discussion

According to the results of this study, in all cases, the radiography tended to indicate the larger values of root length, but the significant statistical difference was only found for distobuccal root of first primary molars. This difference can be due to the position of this root, angle of the rays in this area and the angle of this root relative to the film.

Although various studies have been conducted to suggest the performance of bitewing radiography, most

of them have focused on the efficiency of this radiography in diagnosis of dental caries, alveolar bone height and evaluation of bone loss.^[5,14,15] To the best of our knowledge there are no studies evaluating the accuracy of bitewing radiography in determination of root and canal length; thus, comparing the results of this study with similar ones was not possible. According to the studies of Basso et al and Topaloglu et al., periapical radiography has had an appropriate accuracy in determination of root length of primary incisors.^[4,16] In the study of Wankhade et al., periapical radiography

was less precise than other methods in determination of root canal length of primary teeth.^[13] In the study of Rekabi et al., the root canal length of primary molars measured by radiography was equal to electronic apex locator in 99.3% and in the study of Eskandariyan et al. there were no significant differences in determination of root canal length of primary molars using electronic apex locator and periapical radiography.^[17,18]

The precise determination of root length of upper primary molars using periapical radiography was not possible in many cases due to the proximity of roots to permanent teeth buds. The presence of physiologic or pathologic root resorption or the presence of periapical pathology makes the measurement even more difficult. Ahmad et al. stated that the accuracy of determination of root canal length of primary anterior teeth was 72% using periapical radiography and Santos Lde et al. expressed that this accuracy was 54.68%.^[7,19] In the study of Pinheiro et al., the root canal length measured by radiography was significantly greater than the true length.^[1] Considering the absence of similar studies about the accuracy of bitewing radiography in measuring the root canal length of primary molars, it was not possible to compare the results of this study to other studies. Considering the advantages of vertical bitewing radiography such as the ease of process and possibility of simultaneous observation of complete structure of upper and lower primary molars, it is recommended to conduct further studies on this subject.

Conclusion

Based on the results of this study, except for distobuccal root of first primary molar, vertical bitewing could precisely determine the root length of primary molars.

Funding: This study was a part of research project (Grant no: 9543419) which was supported and funded by Babol University of Medical Sciences.

Conflict of interest disclosure: The authors state that they have no conflict of interest.

Authors' Contributions

The study was designed by Mahtab Hamzeh and Farida Abesi. The study data were collected by Ana Rakhshandejoo. Analysis and interpretation of data drafting of the manuscript, and critical revision of the

manuscript for important intellectual content were performed by Soraya Khafri, Mahtab Hamzeh, Farida Abesi and Ana Rakhshandejoo. Study supervision was conducted by Mahtab Hamzeh and Farida Abesi.

References

1. Pinheiro SL, Bincelli IN, Faria T, Bueno CEDS, Cunha RS. Comparison between electronic and radiographic method for determination of root canal length in primary teeth. *RSBO* 2012 ; 9 : 11-6.
2. Nelson-Filho P, Romualdo PC, Bonifácio KC, Leonardo MR, Silva RA, Silva LA. Accuracy of the iPex multi-frequency electronic apex locator in primary molars: an ex vivo study. *Int Endod J* 2011;44:303-6.
3. Koçak S, Koçak MM, Sağlam BC. Efficiency of 2 electronic apex locators on working length determination: A clinical study. *J Conserv Dent* 2013;16:229-32.
4. Basso MD, Jeremias F, Cordeiro RC, Santos-Pinto L. Digital radiography for determination of primary tooth length: in vivo and ex vivo studies. *Scientific World Journal* 2015;2015:939045.
5. Parveen K, Wyne AH. Methods for caries detection: an overview. *Pakistan Oral Dent J* 2015;35:666-9.
6. Oznurhan F, Ünal M, Kapdan A, Ozturk C, Aksoy S. Clinical evaluation of apex locator and radiography in primary teeth. *Int J Paediatr Dent* 2015;25:199-203.
7. Ahmad IA, Pani SC. Accuracy of electronic apex locators in primary teeth: a meta-analysis. *Int Endod J* 2015; 48:298-307.
8. Bahrololoomi Z, Soleymani AA, Modaresi J, Imanian M4, Lotfian M. Accuracy of an electronic apex locator for working length determination in primary anterior teeth. *J Dent (Tehran)* 2015;12:243-8.
9. Subramaniam P, Konde S, Mandanna DK. An in vitro comparison of root canal measurement in primary teeth. *J Indian Soc Pedod Prev Dent* 2005;23:124-5.
10. Krishnan IS, Sreedharan S. A comparative evaluation of electronic and radiographic determination of root canal length in primary teeth: An in vitro study. *Contemp Clin Dent* 2012;3:416-20.
11. Neena IE, Ananthraj A, Praveen P, Karthik V, Rani P. Comparison of digital radiography and apex locator with the conventional method in root length

- determination of primary teeth. *J Indian Soc Pedod Prev Dent* 2011;29:300-4.
12. Mello-Moura ACV, Bresolin CR, Moura-Netto C, Ito A, Araki AT, Imparato JCP, et al. Use of artificial primary teeth for endodontic laboratory research: experiments related to canal length determination. *BMC Oral Health* 2017;17:131.
 13. Wankhade AD, Kumar R, Singh RK, Chandra A. Root canal length determination by different methods in primary teeth: an in vivo study. *Pediatr Dent* 2013;35:E38-42.
 14. Foster Page LA, Boyd D, Fuge K, Stevenson A, Goad K, Sim D et al. The effect of bitewing radiography on estimates of dental caries experience among children differs according to their disease experience. *BMC Oral Health* 2018;18:137
 15. Abdinian M, Razavi SM, Faghihian R, Samety AA, Faghihian E. Accuracy of digital bitewing radiography versus different views of digital panoramic radiography for detection of proximal caries. *J Dent (Tehran)* 2015;12:290-7.
 16. Topaloglu-Ak A, Aykut Yetkiner A, Güniz Baksi B, Eronat C. Ex vivo comparison of radiographic and electronic root canal length measurements in primary molars. *Eur J Paediatr Dent* 2015;16:149-53.
 17. Rekabi S, Rajaie Behbahani E, Soruri M, Bahrololoomi Z. A Clinical Comparison of Accuracy of an Electronic Apex Locator (EAL) and Radiography in the Determination of Working Length in Primary Molars. *J Shaheed Sadoughi Univ Med Sci* 2013;21(Suppl 3):360-9.[In Persian]
 18. Eskandariyan T, Sahebi S, Amirabadi F, Alipour A. Clinical comparison of root canal length in mandibular molars using an apex locator and conventional radiography. *Shiraz Univ Dent J* 2011; 12: 114-9.[In Persian]
 19. Santos Lde M, dos Reis JI. Comparative analysis of the electronic and radiographic determination of root canal length of primary molars– an ex vivo study. *Braz J Oral Sci* 2009;8: 189-92.