Caspian J of Dent Res

Original Article

Clinical and denture-related characteristics in patients with epulis fissuratum: a retrospective 58 case series

Marzieh Mohammadi[1],Nader Navabi[2]✉,Mohammad Reza Zarei[2]

1. General Dentist, Private Practice, Kerman, Iran.
2. Associate Professor, Social Determinants on Oral Health Research Center,Kerman University of Medical Sciences, Kerman, Iran.

✉**Corresponding Author:** Nader Navabi, Dental School, Kerman University of Medical Sciences, Kerman, Iran.
Email: n_navabi@kmu.ac.ir **Tel:** +098-3432118071

Received: 3 Sept 2016 Accepted: 4 Mar 2017

Abstract

Introduction: Epulis fissuratum is one of the important denture-related mucosal lesions that occurs around the borders of an ill-fitting denture. The purpose of this study was to analyze the cases of epulis fissuratum admitted in the department of oral medicine, Kerman Dental School in relation to the demographic, denture-related and clinical findings.

Materials &Methods: Medical files of all patients referred to the Department of Oral Medicine and Oral Pathology, Kerman Dental School, Iran from 1999 to 2014 were reviewed and 58 cases with the diagnosis of epulis fissuratum with complete and acceptable data were illustrated.

Results: The frequency of epulis fissuratum was 2.9 % of the total number of pathologies. The disorder had been occurred predominantly in the sixth decade of life (41.4%) and more often among females (79.3%). The frequency of epulis fissuratum was higher for a length of denture use of more than 10 years. Patients reported pain associated with the lesion (70.6%).

Conclusion: The knowledge of some facts, especially the quality of dentures and level of denture hygiene in patients with epulis fissuratum supports the importance of the prevention of the lesion, hence the dentists should instruct their patients who have worn dentures how to prevent this lesion.

Keywords: Patients ,Dentures, Retrospective study, Epulis

Citation for article: Mohammadi M, Navabi N, Zarei MR. Clinical and denture-related characteristics in patients with epulis fissuratum: a retrospective 58 case series. Caspian J Dent Res 2017; 6:15-21.

[Downloaded from cjdr.ir on 2024-10-12]

[DOR: 20.1001.1.22519890.2017.6.1.3.4]

[DOI: 10.22088/cjdr.6.1.15]

خصوصیات بالینی و مرتبط با دندان مصنوعی در بیماران مبتلا به اپولیس فیشوراتوم : سری گذشته نگر ۵۸ بیمار

مرضیه محمدی، نادر نوابی*، محمدرضا زارعی

چکیده

مقدمه: اپولیس فیشوراتوم یکی از ضایعات مخاطی مهم مرتبط با دندان مصنوعی است که در مجاورت لبه های دست دندانیکه گیر ناکافی دارد ایجاد می شود. هدف از مطالعه حاضر، آنالیز یافته های دموگرافیک و بالینیو ویژگیهای دندان مصنوعی بیماران مبتلا به اپولیس فیشوراتوم مراجعه کننده به بخش بیماریهای دهان دانشکده دندانپزشکی کرمان بوده است.

مواد و روش ها: پرونده های پزشکی کلیه بیماران با تشخیص اپولیس فیشوراتوم که از سال ۱۳۷۸ تا ۱۳۹۳ به بخش بیماریهای دهان و پاتولوژی دهان دانشکده دندانپزشکی کرمان ارجاع داده شده بودند مرور گردید و از این میان، ۵۸ بیماری که داده های مربوط به ایشان کامل و قابل قبول بود، مورد بررسی و تشریح قرار گرفت.

یافته ها: وقوع اپولیس فیشوراتوم به میزان ۲/۹درصد کل ضایعات بود .این ضایعه، اغلب در دو دهه ششم و هفتم از زندگی بیماران (۴۱/۴ درصد) به میزان بالاتری در خانمهارخ داده بود (۷۹/۳درصد). اپولیس فیشوراتوم در بیمارانیکه بیش از ۱۰سال از دست دندان استفاده کرده بودند بروز بالاتری داشت و ۷۰/۶درصد از بیماران درد ناشی از ضایعه را ابراز کرده بودند.

نتیجه گیری: پی بردن به برخی از واقعیات نظیر کیفیت دست دندان و میزان رعایت بهداشت آن توسط بیماران مبتلا به اپولیس فیشوراتوم بیانگر اهمیت پیشگیری از بروز این ضایعه است از این رو دندانپزشکان باید بیماران استفاده کننده از دندان مصنوعی خود را در زمینه پیشگیری از این ضایعه آموزش دهند.

واژگان کلیدی: بیماران،دندان مصنوعی، مطالعه گذشته نگر،اپولیس

Introduction

Some of the oral mucosal lesions occur as a result of acute and chronic irritations caused by factors associated with dentures. These lesions are known as denture-related mucosal lesions (DML).[1-5] The most common DMLs are frictional keratosis, epulis fissuratum, candidiasis, traumatic ulcers, angular cheilitis and denture stomatitis.[1,6-7] Epulis fissuratum has always been reported as the most prominent DML and it has been shown that the use of a complete denture increases the risk of this lesion three times.[8–10] The word "epulis" is a general term that refers to the hyperplasia occurring in the gingiva or in the alveolar mucosa. Epulis fissuratum is also referred to as denture granuloma, inflammatory fibrous hyperplasia, denture-induced fibrous hyperplasia and denture-related hyperplasia.[9-11] Epulis fissuratum is a benign reactive hyperplasia of the fibrous connective tissue that occurs adjacent to the flanges of complete or partial ill-fitting dentures. These dentures usually have flanges longer than usual and give rise to mild and chronic irritation of the adjacent mucosa. Epulis fissuratum usually occurs in middle-aged and older adults who wear removable dentures for a long time, with a higher prevalence rate in women.[12-14] This lesion is formed as one or more folds of hyperplastic tissue between the alveolar vestibules in the labial or buccal mucosa and the flange of the denture fits between the folds. The lesion is usually painless and pink; however, some of these lesions might be erythematous and also symptomatic. Epulis fissuratum has a firm consistency, a smooth surface and varied size; this lesion might grow to involve almost the entire length of the vestibule. This lesion is more prevalent in the maxilla and also in the anterior regions.[15-18] Diagnosis is usually possible when it is observed in the immediate vicinity of the denture flange. Ulcerations are occasionally observed in the bottom of fissures of the lesion. The red and small lesions, which are mostly inflamed lesions, completely disappear when the denture is removed or its flanges are shortened. The larger fibrous lesions must be surgically removed. It is often necessary to increase the sulcus depth simultaneously with the surgical treatment. In addition, it is advisable to replace the patients' denture or reline it in order to prevent the recurrence of the lesion. [16-18] According to the results of a study

[Downloaded from cjdr.ir on 2024-10-12]
[DOR: 20.1001.1.22519890.2017.6.1.3.4]
[DOI: 10.22088/cjdr.6.1.15]

conducted in Iran in 2013, the prevalence rate of epulis fissuratum was 16.4%.[9] Although studies on DML have always regarded epulis fissuratum as one of the most common lesions, have not described its clinical characteristics. Some studies have examined this lesion in a separate class of lesions, namely a reactive hyperplasia of the soft tissue, categorizing epulis fissuratum like pyogenic granuloma, giant cell granuloma and peripheral fibroma instead of classifying it as a DML [11-14] Some other studies have sufficed to indicate the demographic and clinical characteristics of the patients in comparison with other types of reactive hyperplasia. No case-series study has been carried out on this lesion in Iran prior to this study. The aim of this study was to evaluate the clinical manifestations of epulis fissuratum in a case series, whether as a lesion subset of DML or a reactive hyperplasia of the soft tissue.

Materials & Methods

This case-series study reviewed the oral disease archives of Kerman Faculty of Dentistry (Iran), where the complete records of the patients with oral diseases have been kept since 1999. The records from 1999 to march 2015 were covered and used in this study. The clinical diagnoses of all cases in this period of time were examined and all cases with the clinical diagnosis of epulis fissuratum were collected. There was an agreement among all oral diseases specialists who had visited the patients with epulis fissuratum on the clinical diagnosis of this disease. In fact, the hyperplastic folds adjacent to the denture flange were considered as the symptom. The information of the cases diagnosed with epulis fissuratum available in the archives was included in the study. The information of the patients with this lesion was included in two sections of a designed form:

The first section consisted of items related to age, gender, type of denture (upper, lower, complete or partial), denture's age, the denture manufacturer (dentist, hygienist), denture retention (fitting, ill-fitting), denture fracture and repair history, daily hygiene and cleaning of the denture with toothbrush or cleaning products by the patient (if yes, how often) and whether the denture has suction or not.

In the second section, the characteristics of the lesion examined by the specialist of oral medicine were recorded and these contain the history of pain in the lesion, the number of folds forming the lesion, dispersion of the lesions on the jaw and whether it has one or more focal points, the presence of ulcers and keratosis in the depth of the tissue folds, the color of the lesion (red or the same color as the mucosa), the maximum length of the lesion (less than 2 cm, 2–4 cm, or more than 4 cm), lesion's response to symptomatic treatments (the lesions size is reduced, has not changed or has been removed), the presence of diffuse erythema or multiple nodules in the hard palate or papillary hyperplasia).[15-19] This study was done after receiving permission from the ethics committee of Kerman University of medical sciences (NO. K/92/358). The patients' personal information was kept confidential. All cases with missing data or incomplete forms were excluded from the study. Data were descriptively analyzed through SPSS 23.

Results

Out of 3121 registered cases, 91 cases of epulis fissuratum were extracted from the archives showing the frequency rate of 2.9% for epulis fissuratum. After reviewing the information available on the forms, 33 cases were excluded from the study due to being incomplete, and finally the clinical information of 58 patients was reported. The mean age of the patients with epulis fissuratum in this study was 54.93±9.99 years; the youngest patient was 33 years old and the oldest one was 89 years old. The duration mean of wearing denture for patients was 12.7±9.17 years in this study; the longest and shortest periods of time were 36 years and 1 year, respectively. The information of patients and their dentures is available in Table 1 and the information on the clinical characteristics of the lesion is shown in Table 2.

There were one and two lesions in the lingual aspect of the mandible (1.7% of the total) and in the maxillary facial and lingual aspects (3.4% of the total), respectively. Ten patients (17.2%) had lesion in both the mandible and maxilla. The results of the responses to symptomatic treatment in 9 patients (6.9%) showed no change in the lesion and complete regression of the lesion in response to the symptomatic treatment was observed in one patient (1.7%). the dysplasia results were not reported by the pathologist in any of cases. Ten patients (17.2%) were affected inflammatory papillary hyperplasia in their palate and also 28 patients (48.2%) suffered from erythema in their palate simultaneously. Figures 1: (a) to (c) (Intraoral photographs of mandibular (a, b) and

[Downloaded from cjdr.ir on 2024-10-12]
[DOR: 20.1001.1.22519890.2017.6.1.3.4]
[DOI: 10.22088/cjdr.6.1.15]

maxillary (c) arch) show epulis fissuratum; hyperplastic folds in the affected mucosa; over the alveolar ridge extending to the vestibule sulcus in three cases.

Table1. Demographic and denture-related data of 58 studied patients

Variable	Groups	Frequency	Percent
Gender	Male	12	20.7
	Female	46	79.3
Age (Year)	<50	20	34.5
	50-60	24	41.4
	60-70	10	17.2
	>۷۰	4	6.9
History of denture fabrication (Year)	<5	15	25.9
	۵-10	12	20.7
	>10	31	53.4
Denture manufacturer	Dentist	25	43.1
	Oral hygienist	33	56.9
Retention of maxillary denture	Proper	38	65.5
	Unacceptable	20	34.5
Retention of mandibular denture	Proper	22	37.9
	Unacceptable	36	62.1
History of fixing denture	Yes	14	24.1
	No	44	75.9
Daily washing of denture by patient	Yes	43	74.2
	No	15	25.8
Type of denture	Complete	53	91.4
	Partial	5	8.6
Frequency of denture daily washing	Once	15	34.8
	Twice	12	27.9
	Three times	16	37.3

Table 2. Clinical data about lesions of 58 studied patients

Variables	Groups	Frequency	Percent
Number of tissue folds	One	18	31
	Two	23	39.7
	Three	8	13.8
	More	9	15.5
Pain reporting	Yes	41	70.6
	No	17	29.4
Maxillary distribution	Focal	11	47.8
	Multifocal	12	52.2
Mandibular distribution	Focal	26	60.4
	Multifocal	17	39.6
Ulcer in depth of folds	Yes	32	55.1
	No	26	44.9
Keratosis adjacent to the lesions	Yes	10	17.2
	No	48	82.2
Color in comparison to adjacent mucosa	Redder	20	34.4
	Same	38	65.5
Surface of lesion	Smooth	50	86.2
	Rough	8	13.8
Maximum length of lesion(centimeter)	<2	16	27.6
	2-4	30	51.7
	>4	12	20.7

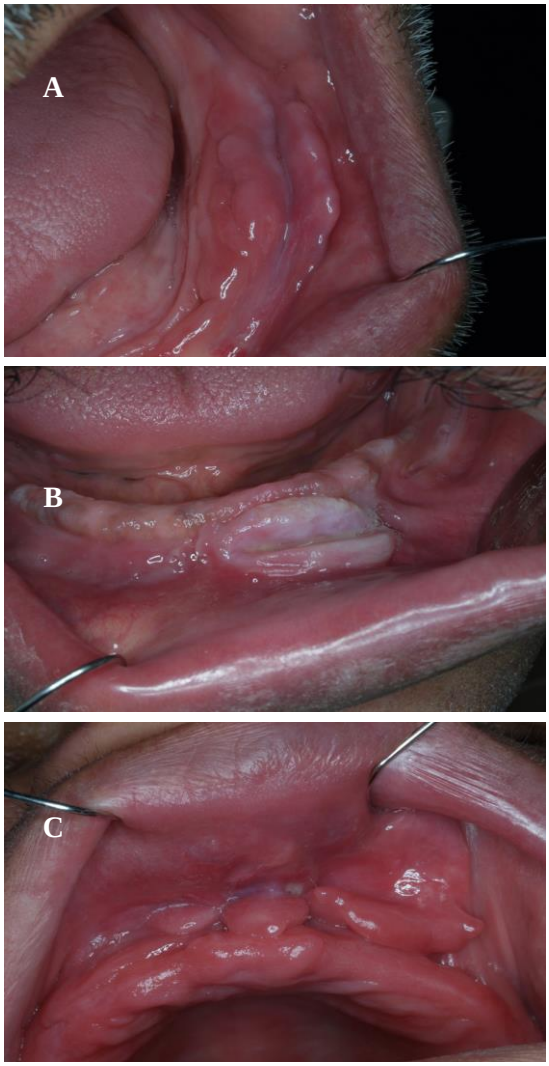

Figure 1 (a): Clinical photograph showing hyperplastic folds on the left mandibular ridge of a 53-years old male. (b) An exophytic mass on the labial vestibule of a 50-years old male. (c) Clinical aspect of epulis fissuratum in the maxillary alveolar ridge of a 59-years old female

Discussion

This study intends to describe the clinical characteristics of a large number of cases (58 patients) with epulis fissuratum lesion, who were diagnosed and treated in a 15-year period. Firoozmand et al. has reported the clinical characteristics of 50 patients with this lesion in a 22 year period in a similar study.[20] Studies on denture wearers indicated the prevalence rate of 8.4-16.4% for this lesion [8, 9] however, the mentioned prevalence rate was related to the population of denture wearers and it seems that there is a relationship between the prevalence of this lesion and other mucosal lesions caused by dentures and other factors such as the quality of the denture. The majority of the patients with epulis

[Downloaded from cjdr.ir on 2024-10-12]
[DOR: 20.1001.1.22519890.2017.6.1.3.4]
[DOI: 10.22088/cjdr.6.1.15]

fissuratum in the study were female (79.3%), consistent with the results of studies by Coelho, Firoozmand and Canger.[19–21] Higher life expectancy of women, higher number of dental visits among women, higher number of women wearing dentures compared to men with the same age, the higher number of women wearing dentures due to esthetic reasons and mucosal atrophy after menopause, which makes the thin mucosa even more sensitive to chronic irritation have been mentioned as the main reasons of the higher prevalence of this lesion among women compared to men.

The mean age of the patients in this study was 54.93 and most of them were in their 50s (the 6th decade of their lives) (41.4%). The mean age of the patients in Firoozmand study was 42.2 and the oldest group of these patients was in their 50s (34%) and the patients in the study conducted by Coelho were in their 50s and 60s. As mentioned above, the mean age of the patients and the highest age group among them in this study are higher than similar studies conducted in Brazil.[19, 20] The higher incidence of denture-related lesions in the younger age group could indicate that patients in the community under study (Iran) lose their teeth at younger ages and the average age of the first time of denture wearing is lower in these communities.

In the present study, majority of patients had been wearing their dentures more than ten years (53.4 %) that is similar to a study by Canger (68.5%). However, the longest period of time since a patient started wearing dentures was reported 6–10 years among those with epulis fissuratum in Coelho study.[19, 21] It seems that the patients' resistance against replacing or repairing the dentures enhances with age increase and these treatments become harder due to their physical conditions. There is a direct relationship between time and the rate of chronic trauma by dentures to the tissues adjacent to them. Therefore, clinicians have asserted that the useful life for a denture is 5 years and the denture needs replacement or some maintenance due to the resorption of lower alveolar ridge after this period. In the present study, 70.6% of the patients stated the symptoms of pain caused by the lesion, similar to the results reported by Firoozmand (70%).[20] The pain that the patients experienced because of the lesion can be a result of mucosal ulcerations caused by the denture flange trauma in the depth of the lesion folds, secondary infections of the lesion or factors such as Candida infection or the pressure caused by patient's prosthesis on the adjacent mucosal tissues. The occurrence of epulis fissuratum on the mandible was more prevalent than the maxilla (43 cases versus 23 cases). Canger also reported higher prevalence on the mandible (53.3%).[21] Histopathological assessment of our cases exhibited no evidence of dysplasia. Coelho reported no evidence of dysplasia in 3.8% of the cases in the histopathologic analysis of 524 cases of epulis fissuratum.[19] Dysplasia rarely occurs in the immediate vicinity of denture flanges; however, chronic irritation of the oral cavity for a long time is always followed by the possibility of premalignant and even malignant lesions. In the present study, like other studies, the majority of lesions with ulcerations or proliferative changes were caused by complete dentures, in comparison with partial dentures.[19, 21] Inflammatory papillary hyperplasia of the palate was observed in 17.2% of the patients in this study, consistent with Canger's study, in which the simultaneous occurrence of two lesions was 15%. This lesion is one of the important mucosal lesions like epulis fissuratum, and the simultaneous occurrence of these two lesions can be considered a "combination syndrome".[21]

The average length of 2-4 cm was the most common size of this lesion (51.7%). However, this aspect has not been mentioned in other studies. In addition, one of the strengths of this study was the report of the prevalence of the clinical factors, including distribution of one or more focal lesions, ulcers in the depth of the folds and keratosis adjacent to the lesions, the predominant color of the lesion and the number of its folds, which were not highlighted in similar studies. The color of the lesions in this study was the same as the adjacent mucosa (65.6%), with a smooth surface (86.2%) as stated in the literature.[15-17]

It seems that similar studies have neglected the evaluation of two important factors causing epulis fissuratum: the quality of dentures and its poor denture hygiene. However, these two factors, the denture fabrication (quality) items such as the manufacturer, denture retention, history of its maintenance or repair and being equipped with suction and hygiene items such as the number of times that the patient washed the denture and whether the patients washed the denture on a daily basis or not, were evaluated in the current study. It is a fact that wearing dentures puts the patients at risk of certain mucosal lesions in a way that the prevalence of mucosal lesions in edentulous patients who do not wear dentures is only 16.7%, compared to the 50-58.2% prevalence rate of these lesions in denture wearers [6, 7, 10]

[Downloaded from cjdr.ir on 2024-10-12]
[DOR: 20.1001.1.22519890.2017.6.1.3.4]
[DOI: 10.22088/cjdr.6.1.15]

One of the limitations of case-series is describing the clinical characteristics of the lesions in a cross sectional manner. Therefore, in order to closer look at the impact of the denture-related effects on epulis fissuratum establishment, longitudinal studies are recommended in this ground.

Conclusion

The modern dentistry requires the dentists to acquire the necessary knowledge in order to protect the health of the oral tissues and prevent the chronic diseases of the oral mucosa. One of the necessary conditions to prevent the occurrence of these epulis fissuratum lesions is to perform standard prosthetic treatments on the patients and carry out the necessary maintenance procedures of the denture as soon as possible. As you can see, 56.9% of the dentures were manufactured by an oral hygienist, with an apparent relationship with the patients' lack of knowledge on the necessity of visiting a prosthodontist and also with economic issues. One of the most important responsibilities of the dentists at the time the denture is delivered to the patients is to provide specific instructions in order to protect the health of the mucosal tissues under the denture. The maintenance and hygiene-related advice such as how to wash the denture and the length of wearing the dentures throughout the day and also recommendations on regular visits to make sure of the health of the tissues under the denture over time are among these necessary instructions.

Acknowledgements

The authors wish to thank sincere cooperation of Social Determinants on Oral Health Research Center, Kerman University of Medical Sciences. The authors declare no conflict of interest.

Funding: This study was a part of a thesis (Kerman Dental School No. 922) and research project (GrantNo. 92/282) and funded by Kerman University of Medical Sciences.

Authors' contributions

The study design,Analysis of data, drafting of the manuscript and critical revision of the manuscript for important intellectual content were performed by Nader Navabi. The study data were collected by Marzieh Mohammadi and the study supervision was performed by Mohammad Reza Zarei.

References

1.Mandali G, Sener ID, Turker SB, Ulgen H. Factors affecting the distribution and prevalence of oral mucosal lesions in complete denture wearers. Gerodontology 2011; 28:97-103.

2. Jainkittivong A, Aneksuk V, Langlais RP. Oral mucosal lesions in denture wearers. Gerodontology 2010; 27:26-32.

3. Freitas JB, Gomez RS, De Abreu MH, Ferreira E ,Ferreira E. Relationship between the use of full dentures and mucosal alterations among elderly Brazilians. J Oral Rehabil 2008; 35:370-4.

4. Coelho CM, Sousa YT, Daré AM. Denture-related oral mucosal lesions in a Brazilian school of dentistry. J Oral Rehabil 2004; 31:135-9.

5. MacEntee MI, Glick N, Stolar E. Age, gender, dentures and oral mucosal disorders.Oral Dis 1998; 4:32-6.

6.Martori E, Ayuso-Montero R, Martinez-Gomis J, Viñas M, Peraire M. Risk factors for denture-related oral mucosal lesions in a geriatric population. J Prosthet Dent 2014; 111:273-9.

7. da Silva HF, Martins-Filho PR, Piva MR. Denture-related oral mucosal lesions among farmers in a semi-arid northeastern region of brazil. Med Oral Patol Oral Cir Bucal 2011; 16:e740-4.

8.Patil S, Yadav N, Patil P, Kaswan S. Prevalence and the relationship of oral mucosal lesions in tobacco users and denture wearers in the north Indian population. J Family Community Med 2013; 20:187-91.

9. Atashrazm P, Sadri D. Prevalence of oral mucosal lesions in a group of Iranian dependent elderly complete denture wearers. J Contemp Dent Pract 2013; 14:174-8.

10.Moskona D, Kaplan I. Oral lesions in elderly denture wearers. ClinPrev Dent 1992; 14:11-4.

11. Zarei MR, Chamani G, Amanpoor S. Reactive hyperplasia of the oral cavity in kerman province, iran: a review of 172 cases. Br J Oral MaxillofacSurg 2007; 45: 288-92.

12. AlaAghbali A, VosoughHosseini S, Harasi B, Janani M, Mahmoudi SM. Reactive hyperplasia of the oral cavity: a survey of 197 cases in tabriz, northwest iran. J Dent Res Dent Clin Dent Prospects 2010; 4: 87-9.

13.Amirchaghmaghi M, Mohtasham N, MosannenMozafari P, Dalirsani Z. Survey of reactive hyperplastic lesions of the oral cavity in

[Downloaded from cjdr.ir on 2024-10-12]

[DOR: 20.1001.1.22519890.2017.6.1.3.4]

[DOI: 10.22088/cjdr.6.1.15]

mashhad, northeast iran. J Dent Res Dent Clin Dent Prospects 2011; 5: 128-31.
14. Naderi NJ, Eshghyar N, Esfehanian H. Reactive lesions of the oral cavity: a retrospective study on 2068 cases. Dent Res J (Isfahan) 2012; 9: 251-5.
15. Ross Kerr A, Chan KC, Phelan JA. Benign lesions of the oral cavity and the jaws. In: Glick M, editor. Burket's oral medicine. 12th ed. Shelton, CT: PMPH-USA, LTD; 2015.p.150-1.
16. Navabi N, Gholamhoseinian A, Baghaei B, Hashemipour MA. Risk factors associated with denture stomatitis in healthy subjects attending a dental school in southeast Iran. Sultan QaboosUniv Med J 2013; 13:574-80.
17. Zarb G, Hobkirk JA. History taking, treatment planning and improving denture-bearing areas for edentulous patients. In : Zarb G , Hobkirk JA , Eckert SE , Jacob RF , editors. Prosthodontic treatment for edentulous patients complete dentures and implant-supported prostheses. 13th ed. St. Louis, Missouri: Elsevier Mosby; 2013.p.61-5.
18. Neville BW, Damm DD, Allen CM, Chi AC. Oral and maxillofacial pathology. 4th ed. St. Louis, Missouri: Elsevier; 2016.p.455-7.
19. Coelho CM, Zucoloto S, Lopes RA. Denture-induced fibrous inflammatory hyperplasia: a retrospective study in a school of dentistry. Int J Prosthodont 2000; 13:148–51.
20. Firoozmand LM, Almeida, Guimarães Cabral LA. Study of denture-induced fibrous hyperplasia cases diagnosed from 1979 to 2001. Quintessence Int 2005; 36:825-9.
21. Canger EM, Celenk P, Kayipmaz S. Denture-related hyperplasia: a clinical study of a turkish population group. Braz Dent J 2009; 20: 243-8.

[Downloaded from cjdr.ir on 2024-10-12]

[DOR: 20.1001.1.22519890.2017.6.1.3.4]

[DOI: 10.22088/cjdr.6.1.15]